

# Extravascular Images of a Penetrating Aortic Ulcer Discovered During Robotic Segmentectomy

Patrick B. McGeoghegan, BS<sup>1</sup>; Vuong-Lam Pham, MD<sup>2</sup>; Vicente Orozco-Sevilla, MD, FACS<sup>3</sup>

<sup>1</sup>Department of Medicine, Baylor College of Medicine, Houston, Texas

<sup>2</sup>Division of Thoracic Surgery, Baylor College of Medicine, Houston, Texas

<sup>3</sup>Division of Cardiothoracic Surgery, Baylor College of Medicine, Houston, Texas



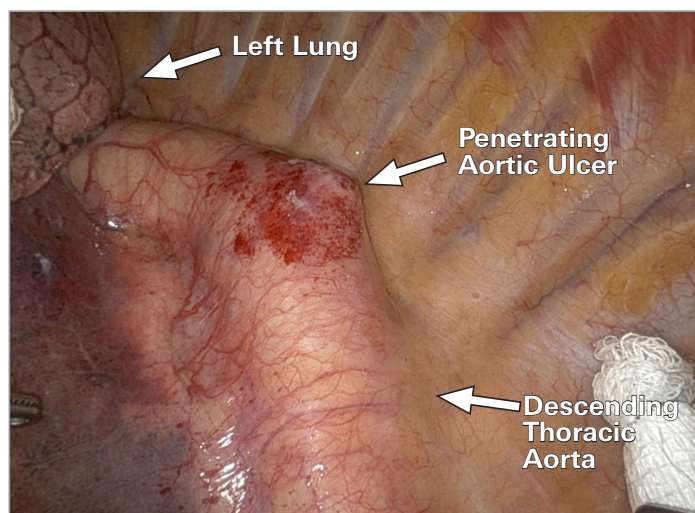
**Keywords:** Acute aortic syndrome; penetrating atherosclerotic ulcer; robotics; indocyanine green

## Case Description

A 68-year-old woman with a 25.3-pack-year history of smoking, hypertension, and hyperlipidemia was noted to have a left lower lobe nodule during a lung cancer screening computed tomography (CT) study. Positron emission tomography CT showed a hypermetabolic lesion suspicious for bronchogenic carcinoma. She also had a fusiform abdominal aortic aneurysm that did not meet criteria for intervention.

Left lower lobe superior segmentectomy with mediastinal lymph node dissection was performed via a robot-assisted thoracoscopic approach. After the left lung was retracted anteriorly and apically, a penetrating aortic ulcer (PAU) became visible in the descending thoracic aorta just distal to the arch (Fig. 1). Posterior hilar and fissure dissection were performed with successful transection of the left lower superior bronchopulmonary segment. Indocyanine green fluorescent dye was injected after pulmonary artery ligation to delineate the intersegmental boundary line. This dye allowed visualization of the PAU under near-infrared light, showing areas of decreased or absent fluorescence representing disruption of the vasa vasorum from atherosclerotic degeneration of the media (Fig. 2).

Postoperative contrast-enhanced CT with angiography did not reveal abnormalities of the thoracic aorta (Fig. 3). Retrospective measurements revealed a PAU depth of roughly 6 to 7 mm and a maximum diameter of 1.8 cm. Thoracic endovascular aortic repair was performed with deployment of a 41 by 10-mm GORE TAG graft (W.L. GORE & Associates), and the patient was discharged 2 days later with a follow-up CT scheduled. Patient consent was obtained for publication.



**Fig. 1** Thoracoscopic image shows an isolated penetrating aortic ulcer incidentally discovered in the proximal descending thoracic aorta during robot-assisted left lower lobe segmentectomy.

**Citation:** McGeoghegan PB, Pham VL, Orozco-Sevilla V. Extravascular images of a penetrating aortic ulcer discovered during robotic segmentectomy. *Tex Heart Inst J*. 2025;52(1):e248545. doi:10.14503/THIJ-24-8545

**Corresponding author:** Patrick B. McGeoghegan, BS, 1 Baylor Plaza, Houston, TX, 77030 ([patrick.mcgeoghegan@bcm.edu](mailto:patrick.mcgeoghegan@bcm.edu))

## Comment

Penetrating aortic ulcer is a recognized category of acute aortic syndrome and can lead to morbidity and mortality.<sup>1</sup> This report includes intraoperative images of an isolated PAU from outside the vessel, discovered during an index thoracoscopic case for pulmonary malignancy. Enhanced visualization was provided by minimally invasive thoracoscopy and indocyanine green contrast. Postoperative CT angiographic imaging did not reveal abnormalities of the thoracic aorta, yet subsequent retrospective measurements revealed a PAU with a depth of 6 to 7 mm from the intima and a maximum diameter of 1.8 cm.

Although CT angiography is highly sensitive for acute aortic syndrome, data on accurate radiologic identification of PAU in particular are scarce, and subtle lesions can be overlooked.<sup>2</sup> In this case, the maximum diameter of 1.8 cm suggested a high-risk lesion. Other imaging characteristics indicative of intervention include a maximum PAU depth of at least 10 mm, a maximum diameter of 1.3 to 2.0 cm, associated intramural hematomas, saccular aneurysms, or increasing pleural effusions.<sup>3</sup> Therefore, this case highlights the importance of intraoperative identification to decrease missed diagnoses of clinically significant PAU.

In addition, intraoperative extravascular images of PAUs are infrequently reported in the literature,<sup>4</sup> and those that are reported do not provide the same exceptional

## Abbreviations

CT, computed tomography  
PAU, penetrating aortic ulcer

clarity as robotic thoracoscopy.<sup>5</sup> Near-infrared indocyanine green is ideal for real-time assessment of vascular flow and quickly revealed poorly perfused, necrotic regions that contribute to PAU pathogenesis and eventual rupture.<sup>6</sup> The images provided in this report should serve as valuable educational tools because intraoperative recognition of PAU is critical to allow prompt vascular intervention and improve patient outcomes.


## Article Information

**Published:** 24 April 2025

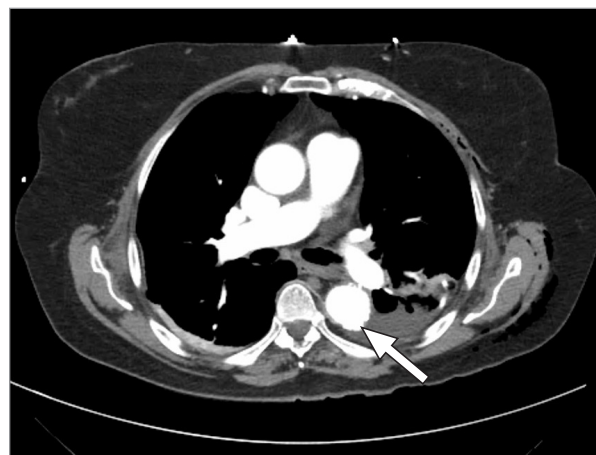**Open Access:** © 2025 The Authors. Published by The Texas Heart Institute®. This is an Open Access article under the terms of the Creative Commons Attribution-NonCommercial License (CC BY-NC, <https://creativecommons.org/licenses/by-nc/4.0/>), which permits use and distribution in any medium, provided the original work is properly cited, and the use is noncommercial.

**Author Contributions:** All authors contributed to the conception and design. Patrick B. McGeoghegan collected and assembled the images. All authors contributed to the writing of this article.

**Conflict of Interest Disclosure:** Authors have made no disclosures.



**Fig. 2** Near-infrared indocyanine green fluorescent imaging reveals poorly perfused segments caused by atherosclerotic ulceration and disruption of the vasculature within the tunica media.



**Fig. 3** A computed tomography angiography axial image shows the penetrating aortic ulcer (arrow). The penetrating aortic ulcer was not reported to be of clinical significance. There was no associated hematoma. Post hoc measurement of ulcer depth was roughly 6 to 7 mm from the intimal surface, and penetrating aortic ulcer diameter was 1.8 cm.

**Funding/Support:** No funding was received for this study. Patient consent was obtained for publishing intraoperative photographs, consistent with institutional policy.

**Acknowledgments:** We express our gratitude to Dr R. Taylor Ripley for permitting the use of intraoperative images captured during his surgical procedure. His support and expertise have greatly enriched the quality of the report.

## References

1. Bellomo TR, DeCarlo C, Khoury MK. Outcomes of symptomatic penetrating aortic ulcer and intramural hematoma in the endovascular era. *J Vasc Surg.* 2023;78(5):1180-1187. doi:10.1016/j.jvs.2023.06.107
2. Quint LE, Francis IR, Williams DM. Evaluation of thoracic aortic disease with the use of helical CT and multiplanar reconstructions: comparison with surgical findings. *Radiology.* 1996;201(1):37-41. doi:10.1148/radiology.201.1.8816517
3. Isselbacher EM, Preventza O, Hamilton Black J III. 2022 ACC/AHA guideline for the diagnosis and management of aortic disease: a report of the American Heart Association/American College of Cardiology Joint Committee on Clinical Practice Guidelines. *Circulation.* 2022;146(24):e334-e482. doi:10.1161/CIR.0000000000001106
4. Patino J, Roughneen PT. The rarity of penetrating ulcer with intramural hematoma of the ascending aorta. *Braz J Cardiovasc Surg.* 2022;37(4):599-601. doi:10.21470/1678-9741-2020-0498
5. Geraci TC, Scheinerman J, Chen D. Beyond the learning curve: a review of complex cases in robotic thoracic surgery. *J Thorac Dis.* 2021;13(10):6129-6140. doi:10.21037/jtd-2019-rts-05
6. Alander JT, Kaartinen I, Laakso A. A review of indocyanine green fluorescent imaging in surgery. *Int J Biomed Imaging.* 2012;2012:940585. doi:10.1155/2012/940585