

Case Reports

The Role of Electrophysiologic Study in Device Selection for Leadless Atrial Pacing

Joshua R. Hirsch, MD¹; Jordan M. Gales, MD^{1,2}; Irakli Giorgberidze, MD^{1,3}; Hamid Afshar, MD^{1,3}

¹Section of Cardiology, Baylor College of Medicine, Houston, Texas

²Department of Cardiology, The Texas Heart Institute at Baylor St Luke's Medical Center, Houston, Texas

³Department of Cardiology, Michael E. DeBakey Veterans Affairs Medical Center, Houston, Texas



Abstract

The AVEIR DR (Abbott Medical) was the first dual-chamber leadless pacing system approved by the US Food and Drug Administration. Many patients with sinus node dysfunction have physiologically normal atrioventricular conduction, so an atrial-only pacing system may be appropriate for them. Three patients with symptomatic sinus node dysfunction underwent device implantation with electrophysiologic study, including incremental atrial pacing until loss of 1:1 atrioventricular conduction (atrioventricular Wenckebach cycle length) and His-ventricular interval measurement. If the atrioventricular Wenckebach cycle length was no more than 400 milliseconds and the His-ventricular interval measurement was no more than 55 milliseconds, single-chamber atrial implantation was deemed appropriate. Each patient displayed a different response to atrioventricular conduction testing, demonstrating how electrophysiologic study before device implantation may identify patients for whom atrial-only pacing is not appropriate.

Keywords: Electrophysiologic techniques, cardiac; cardiac pacing, artificial; bradycardia; sick sinus syndrome

Case Report

Sinus node dysfunction (SND) is the most common indication for pacemaker implantation, making up more than half of device implantations in the United States.^{1,2} Single-chamber atrial-inhibited pacing (commonly referred to as “AAI”: atrial pacing with atrial sensing that inhibits stimulation when an atrial signal is detected) has infrequently been used in the United States largely because of the anticipated need for dual-chamber pacing,³ although dual-chamber pacing occurs in a minority of patients (1.7%–4.5% per year).^{4,5} The AVEIR DR (Abbott Medical) became the first dual-chamber leadless pacing (LP) system to be approved by the US Food and Drug Administration after demonstrating safety and efficacy in the AVEIR DR i2i study.⁶ The AVEIR DR system provides synchronous atrioventricular dual-chamber, adaptive–rate (DDDR) pacing via atrial (termed “AR”) and ventricular (termed “VR”) LP that communicates wirelessly.^{6,7} The AVEIR AR device is implanted in the right atrium, usually at the base of the right atrial appendage.⁸ Atrial-only LP device implantation has previously been described under the Food and Drug Administration’s compassionate use for investigational medical products,⁹ and use of the AVEIR AR device alone is currently covered by the Centers for Medicare & Medicaid Services under coverage with evidence development (ClinicalTrials.gov identifier NCT05932602). Appropriate patient selection for atrial-only LP device implantation is an area of approaching need. This report describes 3 cases in which an electrophysiology (EP) study immediately before LP device implantation yielded differing results, exemplifying how atrioventricular nodal and

Citation: Hirsch JR, Gales JM, Giorgberidze I, Afshar H. The role of electrophysiologic study in device selection for leadless atrial pacing. *Tex Heart Inst J.* 2025;52(1):e248495. doi:10.14503/THIJ-24-8495

Corresponding author: Hamid Afshar, MD, 2002 Holcombe Blvd, Department of Cardiology, Michael E. DeBakey Veterans Affairs Medical Center, Houston, TX 77030 (hamida@bcm.edu)

conduction system testing can guide single-chamber vs dual-chamber LP device implantation.

Case 1

A 76-year-old man with hypothyroidism, hyperlipidemia, and tremors was referred to the clinic for dizziness and bradycardia. The patient's implantable loop recorder revealed sinus bradycardia (slowest heart rate, 40/min; mean heart rate, 50/min), with 2 sinus pauses longer than 10 seconds and atrial fibrillation with a burden less than 1%. The patient described lightheadedness with activity, syncopal episodes, and progressive fatigue. Physical examination was performed without evidence of substantial abnormality. Electrocardiography displayed sinus bradycardia, with a PR interval of 184 milliseconds and a normal QRS complex (84 milliseconds). Transthoracic echocardiography confirmed a normal left ventricular ejection fraction (55%-60%) without substantial chamber or valvular abnormality. Pacemaker implantation was recommended, and after discussion of the procedure, risks, and benefits of transvenous and LP systems, the patient elected LP device implantation.

He consented to an EP study followed by AVEIR DR LP system implantation, with an atrial-only implant if deemed appropriate. After induction of general anesthesia and femoral venous access, a quadripolar catheter was introduced to the right atrium. The His-ventricular (HV) interval was measured, and incremental atrial pacing was performed until loss of 1:1 atrioventricular conduction (atrioventricular Wenckebach cycle length). If the HV interval was no more than 55 milliseconds and the atrioventricular Wenckebach cycle length was no more than 400 milliseconds, single-chamber atrial LP device implant would be deemed appropriate. This patient's atrioventricular Wenckebach cycle length was 400 milliseconds, and his HV interval was 48 milliseconds. Implantation of the AVEIR AR device was therefore performed using a standard technique to ensure appropriate position, fixation, sensing, and capture at the junction of the right atrial appendage base and lateral right atrial wall.

Device programming and parameters for all 3 cases are listed in Table I. Clinical follow-up through 75 months for the patient in case 1 demonstrated improvement in clinical symptoms and no recurrent syncope or procedural or device-related complication. Loop recorder

Key Points

- Electrophysiologic study, including rapid atrial pacing and measurement of the HV interval, may be useful to assess a patient's candidacy for an atrial-only pacing strategy.
- An AAI leadless pacing strategy may appropriately treat SND while minimizing procedural risk, limiting battery expenditure, and deferring ventricular leadless or transvenous device implantation until indicated by development of atrioventricular block or progression of conduction system disease.

Abbreviations

EP, electrophysiology
 HV, His-ventricular
 LP, leadless pacemaker
 SND, sinus node dysfunction

interrogation has not shown any atrioventricular block and has shown 1% burden of atrial fibrillation.

Case 2

A 78-year-old man was referred to the study clinic for symptomatic sinus pauses. His medical history included paroxysmal atrial fibrillation; previous subdural hematoma and gastrointestinal bleeding while on oral anticoagulation therapy; severe aortic insufficiency and ascending aortic aneurysm status following aortic valve, ascending aorta, and hemiarch replacement with maze surgical ablation and left atrial appendage ligation 2 years earlier; hypertension; chronic kidney disease (stage 3B); and obesity. Ambulatory rhythm monitoring 2 years earlier had detected sinus pauses lasting longer than 3 seconds while the patient was taking low-dose metoprolol; he was asymptomatic at that time, and the pauses initially did not recur after discontinuation of the β -blocker. He again presented after multiple presyncopal episodes correlating with sinus pauses on ambulatory rhythm monitoring (sinus rhythm: average rate, 73/min; 4 pauses, with longest lasting 3.4 seconds; no atrial or ventricular arrhythmia). Physical examination was performed without evidence of substantial abnormality. Electrocardiogram displayed normal sinus rhythm, with a PR interval of 206 milliseconds and a QRS complex of 106 milliseconds. Transthoracic echocardiogram confirmed normal left ventricular ejection fraction (55%-60%), with impaired relaxation and mildly elevated prosthetic aortic valve gradient and normal valve

TABLE 1. Pacemaker Programming and Parameters After Implantation

	Case 1			Case 2			Case 3		
Device programming	AAI 60			DDDR 60			DDD 50		
	Sensor off			Paced atrioventricular delay, 200 ms			Paced atrioventricular delay, 225 ms		
	Hysteresis rate delta off			Sensed atrioventricular delay, 180 ms			Sensed atrioventricular delay, 225 ms		
				Rate responsive atrioventricular delay off			Rate responsive atrioventricular delay off		
				Hysteresis rate delta off			Hysteresis rate delta off		
				Ventricular intrinsic preference (200-ms extension)			Ventricular intrinsic preference (200-ms extension)		
				Maximum sensor rate, 95/min			Maximum track rate, 130/min		
Timing of interrogation	1 d	2 wk	30 wk	1 d	2 wk	15 wk	1 d	2 wk	9 wk
Pacing since implantation, %	N/A	1	5	N/A	Atrial: 42 Ventricular: 15	Atrial: 47 Ventricular: 15	N/A	Atrial: 7 Ventricular: 5	Atrial: 7 Ventricular: 5
Sensed amplitude, <1.0 mV		1.1	2.8	P: 2.1 R: 9.3	P: 2.5 R: 11.5	P: 3.1 R: 13.1	P: 4.2 R: 17.4	P: 5.0 R: 16.4	P: 5.8 R: 16.5
Pacing impedance, Ω	390	400	480	Atrial: 300 Ventricular: 580	Atrial: 340 Ventricular: 610	Atrial: 320 Ventricular: 550	Atrial: 420 Ventricular: 820	Atrial: 380 Ventricular: 820	Atrial: 350 Ventricular: 700
Pacing capture threshold, V ^a	2.5 (0.5 ms)	2.25 (1.0 ms)	3.0 (1.0 ms)	Atrial: 0.5 Ventricular: 0.5	Atrial: 0.5 Ventricular: 0.5	Atrial: 0.5 Ventricular: 0.5	Atrial: 0.5 Ventricular: 0.5	Atrial: 1.5 Ventricular: 0.5	Atrial: 0.5 Ventricular: 0.5
Programmed pacing amplitude, V ^a	3.5 (0.5 ms)	3.5 (1.0 ms)	4.0 (1.0 ms)	Atrial: 2.5 Ventricular: 2.5	Atrial: 1.25 Ventricular: 1.25	Atrial: 1.25 Ventricular: 1.25	Atrial: 3.5 Ventricular: 3.5	Atrial: 3.5 Ventricular: 3.5	Atrial: 1.5 Ventricular: 1.5
Estimated battery longevity, y	N/A	14.6	9.9	N/A	Atrial: 5.6 Ventricular: 10.8	Atrial: 6.9 Ventricular: 11.1	N/A	Atrial: 6.2 Ventricular: 11.1	Atrial: 6.2 Ventricular: 11.0

N/A, not applicable.

^a Pacing duration 0.4 ms unless otherwise specified in parentheses.

function. Pacemaker implantation was recommended, and the patient elected LP device implantation.

The patient's HV interval measured 65 milliseconds, and his atrioventricular Wenckebach cycle length measured 580 milliseconds. Implantation of the AVEIR DR

system was performed using a standard technique, with the AVEIR VR device positioned at the right ventricular midseptum and the AR device at the base of the right atrial appendage. An electrocardiogram and a chest radiograph are shown in Figure 1. Clinical follow-up through 5.5 months after implantation demonstrated

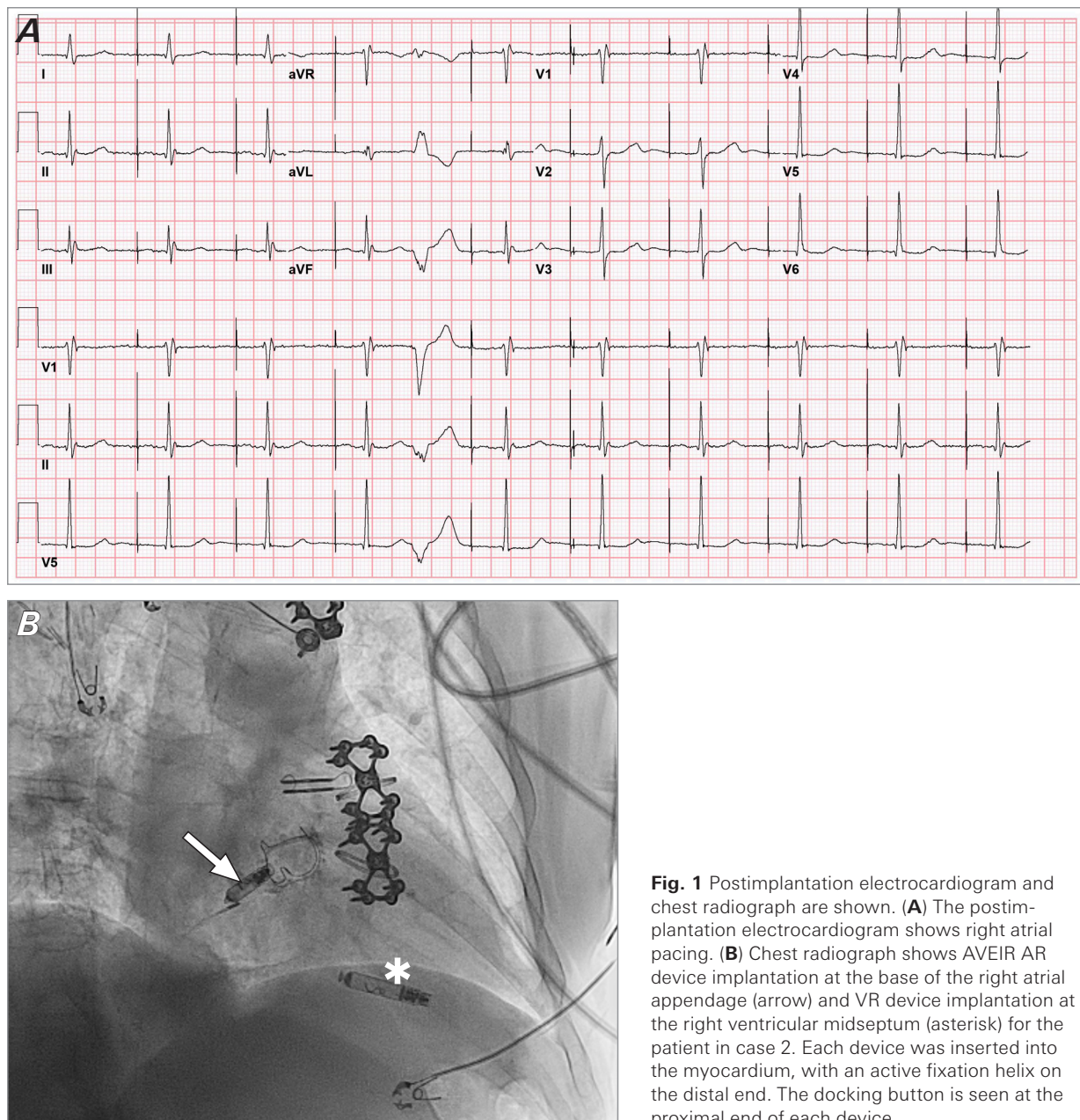


Fig. 1 Postimplantation electrocardiogram and chest radiograph are shown. **(A)** The postimplantation electrocardiogram shows right atrial pacing. **(B)** Chest radiograph shows AVEIR AR device implantation at the base of the right atrial appendage (arrow) and VR device implantation at the right ventricular midseptum (asterisk) for the patient in case 2. Each device was inserted into the myocardium, with an active fixation helix on the distal end. The docking button is seen at the proximal end of each device.

no recurrence of presyncopal symptoms or procedural or device-related complications.

Case 3

A 45-year-old man presented with daytime dizziness coinciding with prolonged sinus pauses (the longest lasting 6 seconds). The patient had a medical history of coronary artery disease, ST-segment elevation myocardial infarction 2.5 years earlier, a stent placed in his left anterior descending coronary artery, hypertension, hyperlipidemia, chronic kidney disease

(stage 2), and premature ventricular contractions monitored by implantable loop recorder and managed with a β -blocker. Metoprolol was discontinued, but sinus pauses recurred (the longest lasting 8 seconds). A physical examination was performed without evidence of substantial abnormality. Electrocardiography displayed normal sinus rhythm, with a PR interval of 162 milliseconds and a QRS complex with right bundle branch block of 160 milliseconds. Transthoracic echocardiography confirmed a normal left ventricular ejection fraction (55%-60%) without substantial

chamber or valvular abnormality. After discussion of pacing options, the patient chose LP device implantation.

The patient's atrioventricular Wenckebach cycle length measured 370 milliseconds, and his HV interval measured 70 milliseconds (Fig. 2). Implantation of the AVEIR DR system was performed using a standard technique, with the VR device positioned at the right ventricular septum and the AR device at the base of right atrial appendage. Clinical follow-up through 4 months after implantation showed no recurrence of symptoms or procedural or device-related complications. Loop recorder interrogation has not shown any pause or atrioventricular block since implantation.

Discussion

This report presented 3 cases of LP device implantation for symptomatic SND, with each patient undergoing a brief EP study before device implantation. In

case 1, assessment of the patient's HV interval and rapid atrial pacing did not suggest dysfunction at or below the atrioventricular node, so an atrial-only LP strategy was chosen. In case 2, an EP study demonstrated findings that were concerning for atrioventricular nodal and infranodal dysfunction, so a dual-chamber strategy was employed. In case 3, the patient's prolonged HV interval warned of infranodal disease, despite normal response to rapid atrial pacing, and a dual-chamber approach was chosen.

With improvements in device and implantation technology and growing implanter experience, rates of LP device implantation are likely to increase. Leadless pacemakers have advantages over transvenous systems, including a reduced rate of venous occlusion, device infection, and lead-related complications.¹⁰⁻¹⁴ Although SND is the most common indication for pacemaker implantation, the prognosticating risk of an atrioventricular block remains a primary consideration at the time of implantation. The risk of an atrioventricular block after pacemaker implantation has been reported

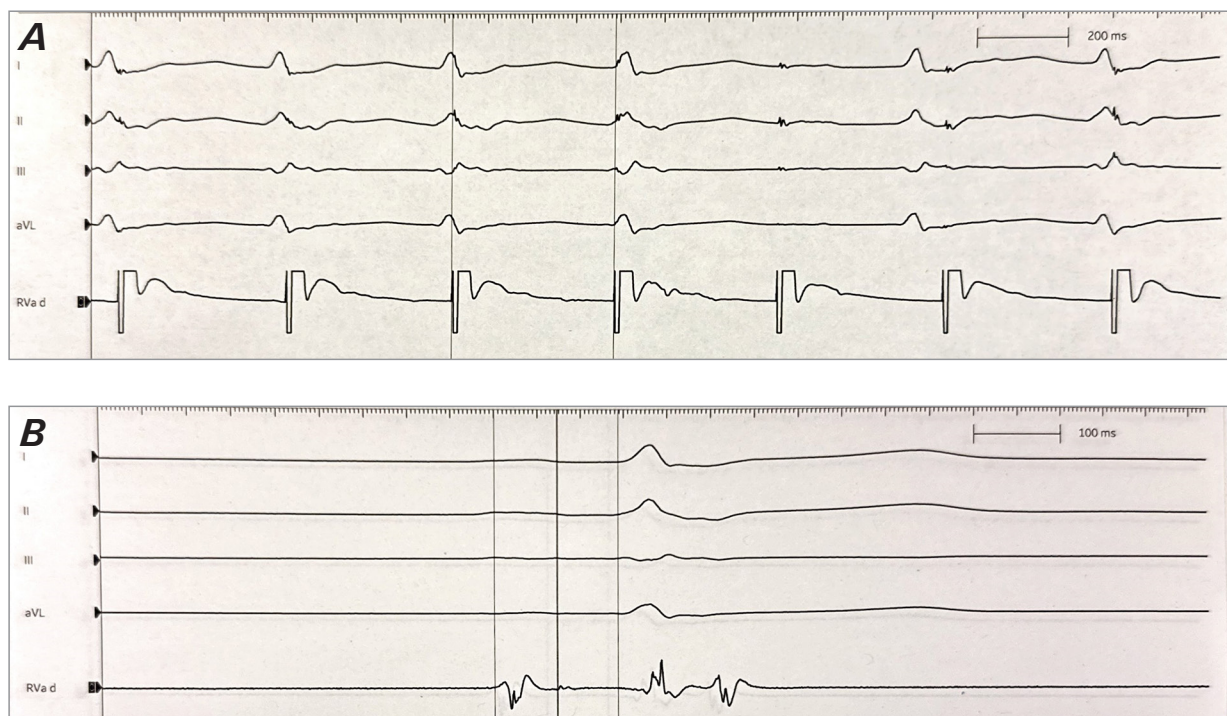


Fig. 2 The preimplantation electrophysiologic assessment performed for the patient in case 3 is shown. **(A)** Atrial pacing is performed with a quadripolar catheter labeled "RVa d." Pacing cycle length decreased from 380 milliseconds for the first 3 pacing stimuli to 370 milliseconds beginning with the fourth pacing stimulus, which captured the atrium but did not conduct to the ventricle, denoting an atrioventricular Wenckebach cycle length of 370 milliseconds. **(B)** The quadripolar catheter labeled "RVa d" recorded a septal atrial electrogram, followed by a proximal His electrogram and septal ventricular electrogram. The atrial-His interval measured 72 milliseconds, and the His-ventricular interval measured 70 milliseconds.

to be between 3% and 35% within 5 years but has also proven difficult to predict.¹ In the Danish Multicenter Randomised Study on AAI Versus DDD Pacing in Sick Sinus Syndrome (DANPACE) trial (ClinicalTrials.gov identifier NCT00236158), individuals with normal QRS duration and SND who underwent transvenous AAIR pacing were found to have nearly double the rate of pacemaker reoperation, a rate driven by the addition of a ventricular lead.^{4,5}

In considering an atrial-only LP system, implanters must weigh the upfront advantages (eg, fewer complications, lower cost, improved battery life with implant-to-implant communication turned off, shorter procedural time) against future drawbacks. Upgrading an atrial-only LP system to a dual-chamber LP system differs substantially from revision of a transvenous system; LP system upgrade carries lower risk of venous occlusion from prior implant and of device and pocket infection. One added obstacle in upgrade from AR to DR LP systems is the presence of an AR device along the implantation path to the right ventricle. An atrial-only LP system also lacks ventricular sensing, which inherently limits the detection of an atrioventricular block in the event of future symptoms or syncope.

Rapid atrial pacing has been proposed as a means of stressing the His-Purkinje system. An atrioventricular block in this setting may be a result of His-Purkinje disease or atrioventricular nodal function influenced by sympathetic tone and medication effect, particularly under general anesthesia. A block below the His bundle at pacing rates slower than 150/min is considered abnormal and suggestive of a high risk for atrioventricular block.¹⁴ Rapid atrial pacing at lower rates has previously been used to guide device management; DANPACE participants were assessed with atrial pacing at 100/min, and those participants unable to maintain 1:1 atrioventricular conduction were deemed unsuitable for AAIR pacing. Of note, individuals with a QRS duration longer than 120 milliseconds or a bundle branch block were excluded from the study.^{4,5} In another study assessing atrioventricular conduction immediately after transcatheter aortic valve replacement (including patients with an abnormal QRS duration and bundle branch block), the absence of a Wenckebach atrioventricular block during atrial pacing up to 120/min demonstrated a negative predictive value of 98.7% for permanent pacemaker implantation.¹⁵ In the current case report's protocol, a conservative threshold of 400 milliseconds was chosen for AAI candidacy.

The HV interval measures conduction from the proximal His bundle to the ventricular myocardium and is not altered by autonomic tone. A normal HV interval ranges from 35 milliseconds to 55 milliseconds in the absence of pre-excitation, and increased values suggest infranodal conduction disease.¹⁴ The results of these case reports suggest that a normal HV interval and response to rapid atrial pacing indicate normal atrioventricular nodal and infranodal conduction; for patients with these cardiologic values, an atrial-only pacing strategy may be appropriate. Brief EP testing performed immediately before device implantation is reproducible, does not require additional vascular access, and only minimally lengthens procedural time. Long-term follow-up is necessary to appreciate the prognostic value of rapid atrial pacing and HV interval measurement at the time of implantation as well as the optimal cutoffs of each, the risk of atrioventricular block, and the need for ventricular pacing in patients with symptomatic bradycardia. Additional study in patients of both sexes and ranging in age and comorbidities is needed, as well.

Article Information

Published: 12 March 2025

Open Access: © 2025 The Authors. Published by The Texas Heart Institute®. This is an Open Access article under the terms of the Creative Commons Attribution-NonCommercial License (CC BY-NC, <https://creativecommons.org/licenses/by-nc/4.0/>), which permits use and distribution in any medium, provided the original work is properly cited, and the use is noncommercial.

Author Contributions: All authors contributed to the development, drafting, and review of this manuscript.

Conflict of Interest Disclosure: The authors have no conflicts of interest to disclose.

Funding/Support: This research did not receive any specific grant from funding agencies in the public, commercial, or not-for-profit sectors.

References

1. Kusumoto FM, Schoenfeld MH, Barrett C, et al. 2018 ACC/AHA/HRS Guideline on the Evaluation and Management of Patients With Bradycardia and Cardiac Conduction Delay: a report of the American College of Cardiology/American Heart Association Task Force on Clinical Practice Guidelines and the Heart Rhythm Society. *Circulation*. 2019;140(8):e382-e482. doi:10.1161/CIR.0000000000000628
2. Manoj P, Kim JA, Kim S, et al. Sinus node dysfunction: current understanding and future directions. *Am J Physiol*

- Heart Circ Physiol.* 2023;324(3):H259-H278. doi:10.1152/ajpheart.00618.2022
3. Greenspon AJ, Patel JD, Lau E, et al. Trends in permanent pacemaker implantation in the United States from 1993 to 2009: increasing complexity of patients and procedures. *J Am Coll Cardiol.* 2012;60(16):1540-1545. doi:10.1016/j.jacc.2012.07.017
 4. Nielsen JC, Thomsen PEB, Højberg S, et al; DANPACE Investigators. A comparison of single-lead atrial pacing with dual-chamber pacing in sick sinus syndrome. *Eur Heart J.* 2011;32(6):686-696. doi:10.1093/eurheartj/ehr022
 5. Brandt NH, Kirkfeldt RE, Nielsen JC, et al. Single lead atrial vs. dual chamber pacing in sick sinus syndrome: extended register-based follow-up in the DANPACE trial. *Europace.* 2017;19(12):1981-1987. doi:10.1093/europace/euw364
 6. Knops RE, Reddy VY, Ip JE, et al; Aveir DR i2i Study Investigators. A dual-chamber leadless pacemaker. *N Engl J Med.* 2023;388(25):2360-2370. doi:10.1056/NEJMoa2300080
 7. Cantillon DJ, Gambhir A, Banker R, et al. Wireless communication between paired leadless pacemakers for dual-chamber synchrony. *Circ Arrhythm Electrophysiol.* 2022;15(7):e010909. doi:10.1161/CIRCEP.122.010909
 8. O'Connor M, Barbero U, Kramer DB, et al. Anatomic, histologic, and mechanical features of the right atrium: implications for leadless atrial pacemaker implantation. *Europace.* 2023;25(9):euad235. doi:10.1093/europace/euad235
 9. Sundaram S, Alyesh D, Walker L, Zipse MM. The 1st implantation of an atrial only leadless pacemaker in right atrial appendage. *J Interv Card Electrophysiol.* 2023;66(9):1955-1958. doi:10.1007/s10840-023-01644-3
 10. Cantillon DJ, Exner DV, Badie N, et al. Complications and health care costs associated with transvenous cardiac pacemakers in a nationwide assessment. *JACC Clin Electrophysiol.* 2017;3(11):1296-1305. doi:10.1016/j.jacep.2017.05.007
 11. Cantillon DJ, Dukkipati SR, Ip JH, et al. Comparative study of acute and mid-term complications with leadless and transvenous cardiac pacemakers. *Heart Rhythm.* 2018;15(7):1023-1030. doi:10.1016/j.hrthm.2018.04.022
 12. Piccini JP, El-Chami M, Wherry K, et al. Contemporaneous comparison of outcomes among patients implanted with a leadless vs transvenous single-chamber ventricular pacemaker. *JAMA Cardiol.* 2021;6(10):1187-1195. doi:10.1001/jamacardio.2021.2621
 13. El-Chami MF, Bockstedt L, Longacre C, et al. Leadless vs. transvenous single-chamber ventricular pacing in the Micra CED study: 2-year follow-up. *Eur Heart J.* 2022;43(12):1207-1215. doi:10.1093/eurheartj/ehab767
 14. Callans D. *Josephson's Clinical Cardiac Electrophysiology: Techniques and Interpretations.* 6th ed. Wolters Kluwer Health; 2020.
 15. Krishnaswamy A, Sammour Y, Mangieri A, et al. The utility of rapid atrial pacing immediately post-TAVR to predict the need for pacemaker implantation. *JACC Cardiovasc Interv.* 2020;13(9):1046-1054. doi:10.1016/j.jcin.2020.01.215