

Case Reports

Cardiac Mass in a 78-Year-Old Patient With a History of Cancer: Diagnostic and Treatment Challenges

Bihong Zhao, MD, PhD¹; Ayah Zaqqqa, MD¹; Michelle M. McDonald, DO²; Ismael A. Salas de Armas, MD³; Igor D. Gregoric, MD³; L. Maximilian Buja, MD⁴

¹Department of Pathology and Laboratory Medicine, University of Texas Health Science Center at Houston, Houston, Texas

²Harris County Institute of Forensic Sciences, Houston, Texas

³Department of Advanced Cardiopulmonary Therapies and Transplantation, University of Texas Health Science Center at Houston, Houston, Texas

⁴Cardiovascular Pathology, The Texas Heart Institute, Houston, Texas



Abstract

Primary cardiac angiosarcoma is a rare, aggressive malignancy that commonly metastasizes to various organs. The presenting symptoms are typically nonspecific, so a comprehensive examination is required to confirm the diagnosis promptly. This case report describes the presentation of an older patient with a history of neoplasms. Echocardiography and biopsy were performed, but despite surgical intervention to resect a large right atrial mass, the patient died. A final diagnosis of primary angiosarcoma was made based on the resected specimen.

Keywords: Heart neoplasms; neoplasm metastasis; diagnosis

Case Report

Presentation and Physical Examination

A 78-year-old man presented with shortness of breath, fatigue, and facial swelling. Transthoracic echocardiography revealed a large, well-defined mass attached to the interatrial septum (IAS) and protruding into the right atrium (RA), with partial obstruction of the superior vena cava (SVC) (Fig. 1). He was referred to the University of Texas Health Science Center at Houston for a second opinion.

Medical History

The patient had a history of bladder and prostate cancer status postprostatectomy, dysplastic colon polyp status post–partial colectomy, atrial fibrillation and sick sinus syndrome status post–permanent pacemaker implantation, chronic obstructive pulmonary disease, and lung nodules.

Technique

Following admission, the patient underwent right heart catheterization, with mass biopsy and left heart catheterization. Because of poor sampling, mass biopsy revealed fibrotic cardiac tissue on microscopic examination.

Mass excision and IAS, RA, and proximal SVC reconstruction were performed. The excision was extended into the left atrium and proximal portion of the inferior pulmonary vein (Fig. 2). At the end of the procedure, coagulopathy was noted, but the patient was hemodynamically stable and the chest was temporarily closed.

Citation: Zhao B, Zaqqqa A, McDonald MM, Salas de Armas IA, Gregoric ID, Buja LM. Cardiac mass in a 78-year-old patient with a history of cancer: diagnostic and treatment challenges. *Tex Heart Inst J*. 2024;51(2):e238299. doi:10.14503/THIJ-23-8299

Corresponding author: L. Maximilian Buja, MD, 6431 Fannin St, MSB2.276, Houston, Texas 77030 (l.maximilian.buja@uth.tmc.edu)

A gross examination of the excised tissue showed a $1.8 \times 1.4 \times 1.4$ -cm tan-brown pedunculated lesion extending from the endocardial surface of the RA overlying the interatrial tumor mass. Sectioning of the specimen revealed a $6.0 \times 3.8 \times 3.0$ -cm brown, hemorrhagic, focally cystic, ill-defined mass within the IAS (Fig. 3).

Microscopic examination of the right atrial mass showed irregular, sieve-like, anastomosing vascular channels and solid growth infiltrating the myocardium (Fig. 4). The tumor cells were spindled, with a high nuclear-cytoplasmic ratio, intracytoplasmic lumina, and nuclear hyperchromasia and enlargement. Tumor necrosis and hemorrhage were extensive. Abundant mitosis (>20 cells/10 high-power fields) and apoptotic debris were noted. Results of immunohistochemistry staining for CD31 and ERG were positive, confirming the tumor's endothelial origin. The Ki-67 labeling index was greater than 80%, reflecting the tumor's highly proliferative nature (Fig. 5).

Additional immunohistochemistry staining performed to screen for alternative primary tumors and metastatic disease included SMA, AE1/AE3, CK7, CK20, GATA-3, NKX3.1, and S100; all results were negative. High-grade angiosarcoma was diagnosed, with an American Joint Committee on Cancer histologic tumor grade of G2 (moderately differentiated).

Outcome

The immediate postoperative course was remarkable for progressive, severe metabolic derangements, including

Key Points

- Primary cardiac angiosarcoma is a rare, aggressive malignancy with nonspecific symptoms and commonly metastasizes to various organs.
- A comprehensive examination combining clinical, radiologic, and histopathologic findings is required to confirm the diagnosis promptly.

Abbreviations and Acronyms

IAS	interatrial septum
RA	right atrium
SVC	superior vena cava

profound lactic acidosis, hyperkalemia, and profound vasoplegia, with an ejection fraction of 40% to 45%. Asystole occurred, and the patient was pronounced dead; consent was obtained for an autopsy restricted to the chest and abdomen.

Autopsy Findings

Autopsy revealed cardiomegaly (heart weight, 620 g) and fibrinous pericardial exudate, scattered blood clots, and a substantial increase in epicardial fat. Evidence of surgical intervention showed complete resection and reconstruction of the entire RA, IAS, and proximal vena cava, with intact anastomoses and suture lines (Fig. 6). Residua from the resected mass were detected at the SVC anastomosis site, and examination revealed a firm, pedunculated, vaguely papillary piece of tissue, 0.7 cm in maximal dimension, emerging from the vessel wall.

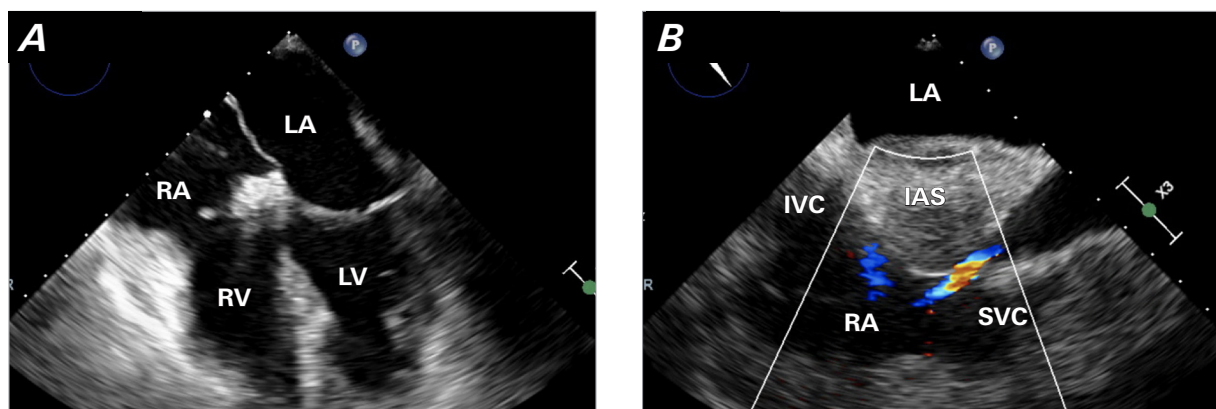


Fig. 1 Preoperative transthoracic echocardiogram. **A)** The 4-chamber view of the heart shows the tumor on the IAS projecting toward the right atrium. **B)** The bicaval view of the heart shows the tumor on the IAS creating a stenosis on the SVC/right atrial junction.

IAS, interatrial septum; IVC, inferior vena cava; LA, left atrium; LV, left ventricle; RA, right atrium; RV, right ventricle; SVC, superior vena cava.

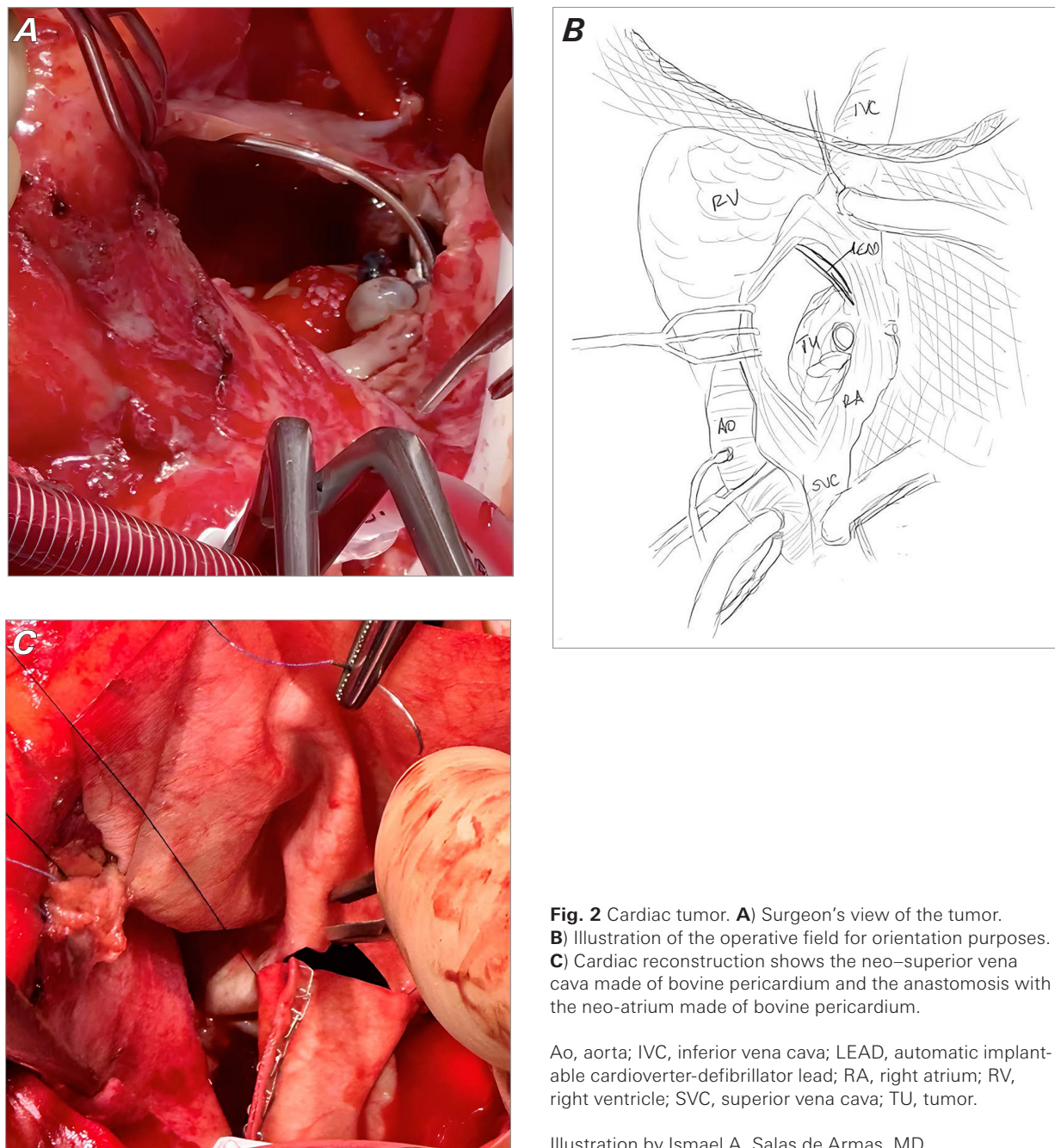


Fig. 2 Cardiac tumor. **A)** Surgeon's view of the tumor. **B)** Illustration of the operative field for orientation purposes. **C)** Cardiac reconstruction shows the neo-superior vena cava made of bovine pericardium and the anastomosis with the neo-atrium made of bovine pericardium.

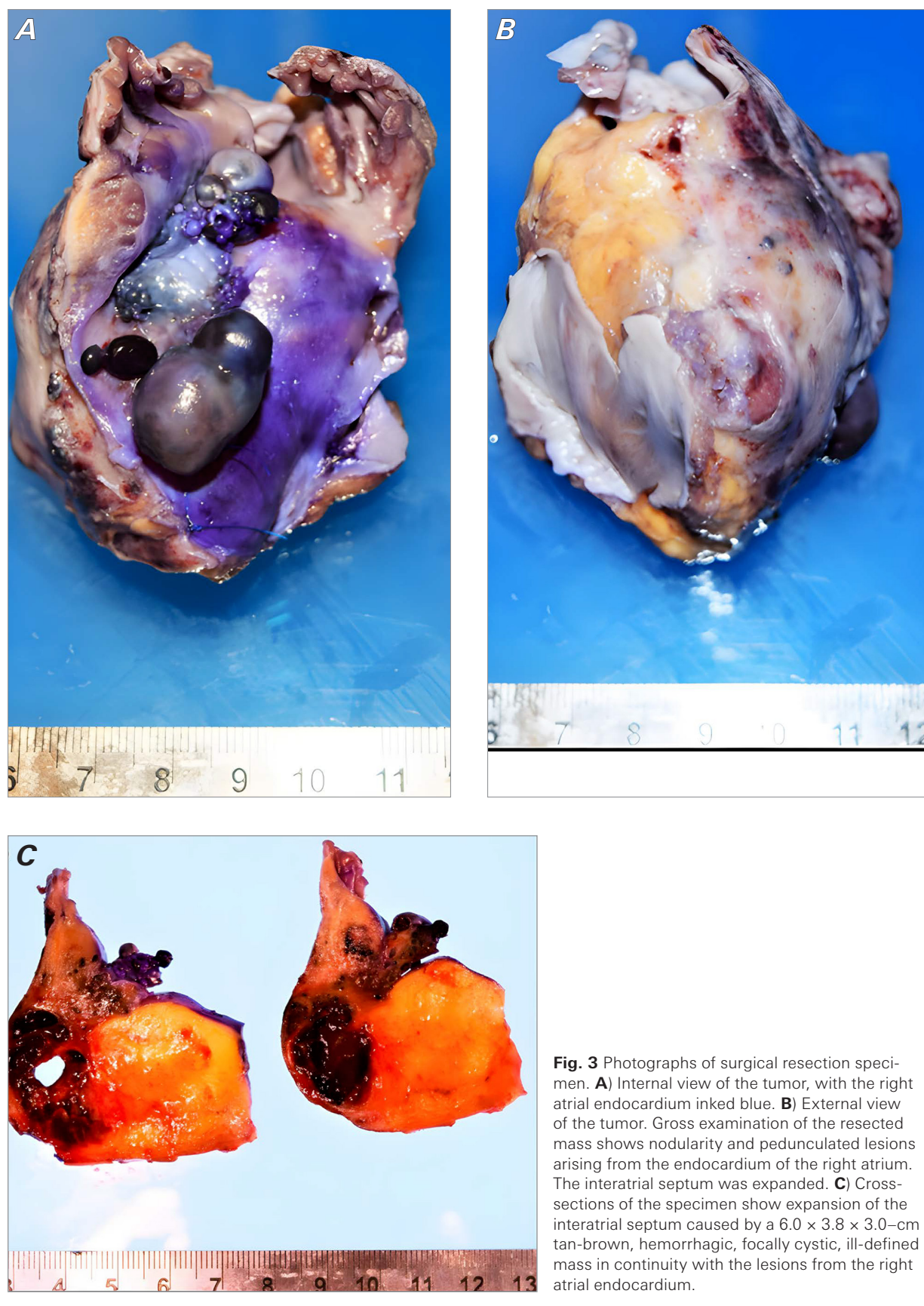Ao, aorta; IVC, inferior vena cava; LEAD, automatic implantable cardioverter-defibrillator lead; RA, right atrium; RV, right ventricle; SVC, superior vena cava; TU, tumor.

Illustration by Ismael A. Salas de Armas, MD.

Moderate to severe atherosclerosis was noted, with stenoses in multiple coronary arteries, including the left anterior descending (60%), left circumflex (20%), and right coronary (80%) arteries. No defects were found in any of the vessels, and no intravascular thrombi were identified.

Sectioning of the heart from apex to base revealed multiple focal lesions, with hemorrhagic discoloration within the myocardium that was grossly consistent

with areas of acute infarction; the largest area involved the posterior wall of the left ventricle and measured $3.3 \times 3.0 \times 1.0$ cm. Histologic examination confirmed an acute myocardial infarction in the interventricular septum; the right ventricle also had areas of acute infarction. The papillary tissue found at the SVC anastomosis site was histologically confirmed as a residual tumor. Metastatic tumor emboli were found in the hilar vessels of the upper lobe of the right lung (Fig. 7).



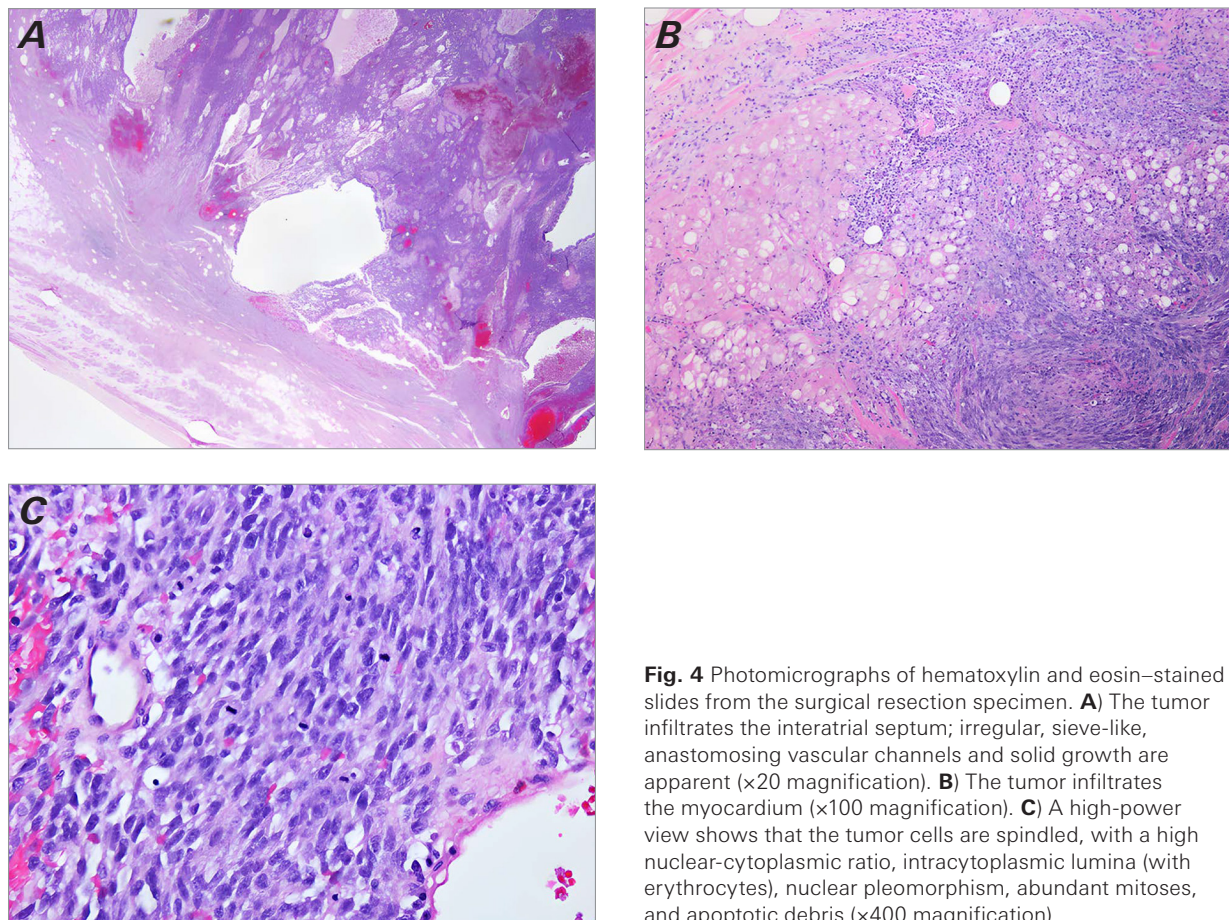


Fig. 4 Photomicrographs of hematoxylin and eosin–stained slides from the surgical resection specimen. **A)** The tumor infiltrates the interatrial septum; irregular, sieve-like, anastomosing vascular channels and solid growth are apparent (×20 magnification). **B)** The tumor infiltrates the myocardium (×100 magnification). **C)** A high-power view shows that the tumor cells are spindled, with a high nuclear-cytoplasmic ratio, intracytoplasmic lumina (with erythrocytes), nuclear pleomorphism, abundant mitoses, and apoptotic debris (×400 magnification).

Discussion

Primary malignant tumors are among the rarest intracardiac masses to be diagnosed.¹ Symptoms of heart tumors are nonspecific and manifest based on the size and location of the mass rather than histologic type.² Detailed collection of a patient's complete medical history is essential for physicians to understand the full context in which a malignancy arises and to reach an accurate diagnosis. This case describes a primary cardiac angiosarcoma in a patient with a history of multiple noncardiac neoplasms.

Cardiac angiosarcoma can be diagnosed in patients of any age, with peak incidence in the fourth and fifth decades of life.³ Symptom severity is correlated with the degree of myocardial and regional involvement and metastatic invasion.⁴ Chest pain, dyspnea, and constitutional symptoms are the most common clinical manifestations; however, angiosarcoma may be asymptomatic if the tumor is small.³ Angiosarcoma metastasis

is frequent and widespread, occurring in up to 80% of cases.⁵ Hematogenous spread to the lungs can produce secondary signs and symptoms, including pulmonary effusion, nodules, fibrosis, and hemoptysis secondary to diffuse pulmonary hemorrhage.^{4,6}

Unlike benign and other malignant sarcomas of the heart, which commonly present on the left,² angiosarcomas are almost exclusively found in the RA and frequently invade the pericardium, vena cava, and tricuspid valve.⁷ Because of the tumor's predilection for the RA, symptoms of right-sided heart failure and SVC obstruction may occur.⁸ Bleeding often happens because of the friability of the lesion,² frequently resulting in hemorrhaging into the pericardium and manifesting as hypotension, tachycardia, pulsus paradoxus, and neck vein congestion. In severe cases, this pericardial effusion may increase intrapericardial pressure and produce clinical symptoms of cardiac tamponade.^{8,9}

Angiosarcomas are aggressive and have a poor prognosis. They must be recognized early and treated aggressively

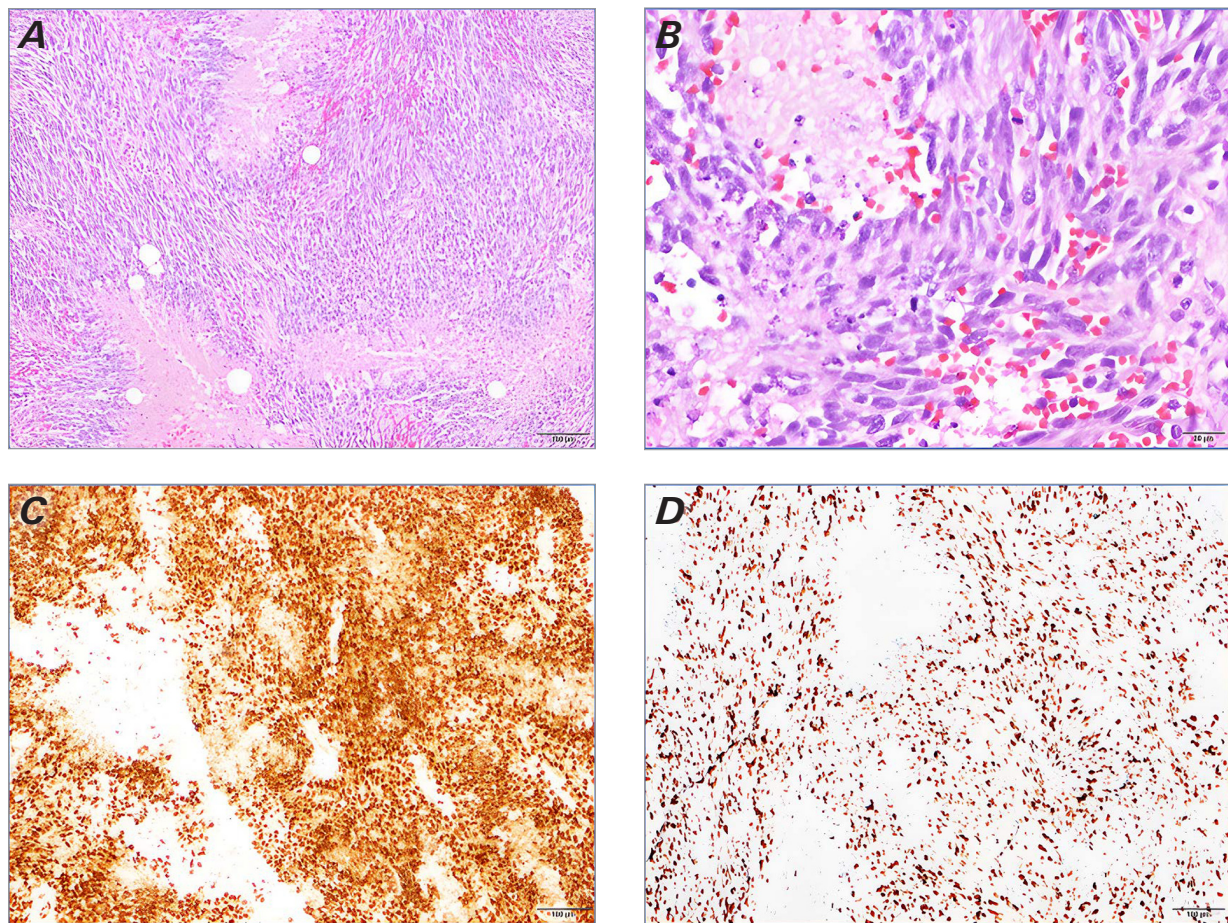


Fig. 5 Photomicrographs. **A)** A low-power view of the lesion shows a spindle cell neoplasm with geographic necrosis and moderate nuclear atypia (×100 magnification). **B)** A high-power view of the lesion reveals a spindle cell neoplasm with frequent atypical mitosis, apoptosis, necrosis, and extravasation of red blood cells (×400 magnification). **C)** Immunohistochemistry staining for ERG shows diffuse and strong nuclear staining (×100 magnification). **D)** Immunohistochemistry staining for Ki-67 revealed more than 80% nuclear staining in the tumor cell and provided evidence of high-grade malignant cells (×100 magnification).

to maximize survival outcomes. The differentials to consider based on patient presentation are wide because of the lack of symptom specificity. When a cardiac lesion is detected on imaging, the physician must consider intracardiac masses, coronary artery disease, pulmonary embolism, pericarditis, and constrictive cardiomyopathy¹⁰ as well as vegetations, thrombi, foreign bodies, and endocarditis.⁹ Malignancy must not be overlooked, however, especially if an intracardiac mass shows signs of pericardial invasion.

The best diagnostic method for cardiac tumors is echocardiography.³ Common findings include cardiomegaly, right-sided heart enlargement, widened mediastinum, hilar adenopathy, pulmonary congestion, and pleural effusion.³ Transesophageal echocardiography and trans-thoracic echocardiography¹¹ are commonly used to ac-

curately visualize the extent of regional tumor invasion. Invasion into the pericardium and regional structures indicates a malignant process as opposed to limited involvement of intracavitary, mural, or epicardial focal benign lesions.¹² Computed tomography, magnetic resonance imaging, angiography, and positron emission tomography can aid in diagnosis.³ Pericardial fluid cytology is rarely used because of the risk of bleeding and the technology's low sensitivity.¹

Biopsy is the gold standard of diagnosis. Transesophageal echocardiography–guided transvenous endomyocardial biopsy can substantially lower the risk associated with diagnostic surgical excision.¹³ Microscopic evaluation of a biopsied angiosarcoma specimen reveals malignant endothelial cells forming papillary structures or irregular, anastomosing, and sinusoidal vascular

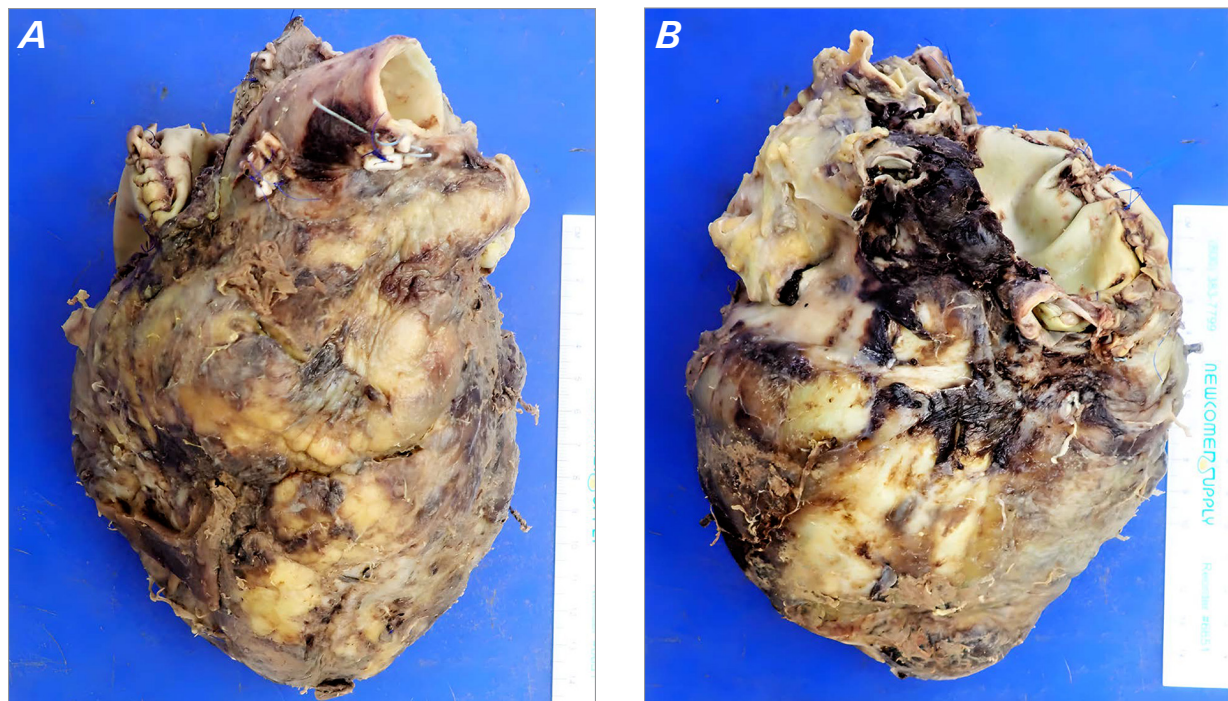


Fig. 6 Autopsy findings. **A)** Photographs of the heart (anterior); all elements of the reconstruction were found to be intact. **B)** Posterior view of the heart.

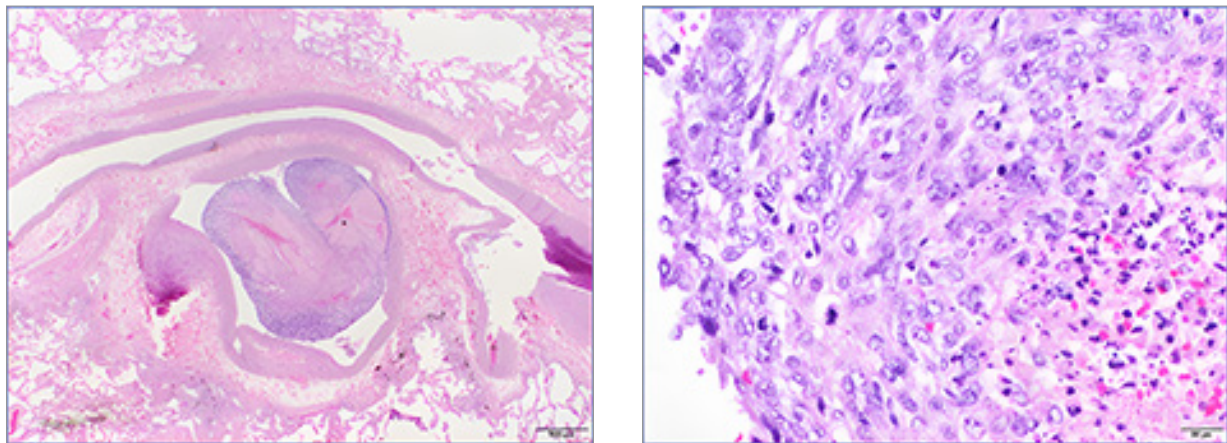


Fig. 7 Photomicrographs of findings from autopsy. **A)** Tumor emboli in the pulmonary artery (x10 magnification). **B)** Morphologic features are identical to the primary tumor (x400 magnification).

channels in the background of anaplastic spindle cells. Tumor biopsies from an angiosarcoma metastasizing into distant organs are considered powerful diagnostic tools, showing areas of better differentiation and greater vasoformation.³

Differentiating between primary and secondary heart tumors is a substantial challenge, considering that the presentation of all intracardial lesions is nonspecific.

Secondary cardiac masses erupting from a metastasizing mass in another organ are 20 to 40 times more common than primary heart tumors²; thus, radiologic-clinical correlation is essential for accurate diagnosis, especially when the symptoms of metastasis are the first presentation of illness.¹⁴ Nonetheless, histologic analysis is necessary to identify and confirm the primary origin of the malignancy. The most frequent cause

of secondary heart tumors is regional invasion from pericardial tumors.¹⁵ Cardiac metastases from distant organs are also commonly reported in many malignant tumors. The patient in this case report had prior diagnoses of bladder and prostate cancer, and cardiac metastases develop in 6% and 4% of patients with these types of cancers, respectively.¹⁵ Histopathologic analysis, however, confirmed a diagnosis consistent with primary cardiac malignancy.

No standard recommended treatment for cardiac angiosarcoma currently exists, but early and complete tumor resection with neoadjuvant therapy increases survival rates. Patients who have undergone complete resection have been shown to have a survival period of 24 months compared with 10 months following incomplete resection in which tumor accessibility was limited.⁴ In right-sided angiosarcomas, resection of the RA, right coronary artery, tricuspid valve, and up to one-third of the ventricular wall, followed by patch reconstruction of the heart, is required to combat the aggressive nature of this cancer.¹⁵ Treatment of metastatic disease of the heart varies and is mainly focused on treating the primary cancer.¹⁶ To preserve heart function, a conservative, symptomatic approach is often considered for metastatic masses in the heart. In contrast, surgical resection is reserved for malignant tumors causing acute obstructive symptoms.¹⁵

Conclusions

Clinical, radiologic, and histopathologic findings are crucial elements in the diagnostic process that allow the physician to paint a complete picture. Masses of the heart discovered in a patient with a history of noncardiac malignancy must be thoroughly evaluated to determine the tumor's primary origin. With such diagnostic assessment, the treating physician can determine an appropriate plan of care that effectively balances quality of life and survival outcomes.

Article Information

Published: 2 August 2024

Open Access: © 2024 The Authors. Published by The Texas Heart Institute®. This is an Open Access article under the terms of the Creative Commons Attribution-NonCommercial License (CC BY-NC, <https://creativecommons.org/licenses/by-nc/4.0/>), which permits use and distribution in any medium, provided the original work is properly cited, and the use is noncommercial.

Author Contributions: A.Z., drafting of manuscript, autopsy; M.M., manuscript revision, autopsy; I.A.S., manuscript revision, surgeon; B.Z., manuscript revision, clinical expertise; I.D.G., manuscript revision, surgeon; L.M.B., manuscript revision, clinical expertise.

Conflict of Interest Disclosure: I.A.S. is a consultant for Abiomed, Inc.; I.D.G. has received institutional grants from Abbott Laboratories, Medtronic LABS, and CryoLife.

Funding/Support: No funding was received for the creation of this manuscript.

Acknowledgments: The authors thank Drs Biswajit Kar and Rajko Radovancevic for clinical expertise and Michelle Gehring, PhD, ELS, and Jessica Moody, PhD, for editorial and submission support.

References

1. Linfeng Q, Xingjie X, Henry D, Zhedong W, Hongfei X, Haige Z. Cardiac angiosarcoma: a case report and review of current treatment. *Medicine (Baltimore)*. 2019;98(49):e18193. doi:10.1097/MD.00000000000018193
2. Paraskevaidis IA, Michalakeas CA, Papadopoulos CH, Anastasiou-Nana M. Cardiac tumors. *ISRN Oncol*. 2011;2011:208929. doi:10.5402/2011/208929
3. Burke A, Tavora FR, Maleszewski JJ, Frazier AA. *Tumors of the Heart and Great Vessels. AFIP Atlas of Tumor Pathology*. American Registry of Pathology; 2015. doi:10.55418/9781933477336
4. Herrmann MA, Shankerman RA, Edwards WD, Shub C, Schaff HV. Primary cardiac angiosarcoma: a clinicopathologic study of six cases. *J Thorac Cardiovasc Surg*. 1992;103(4):655-664.
5. Antonuzzo L, Rotella V, Mazzoni F, et al. Primary cardiac angiosarcoma: a fatal disease. *Case Rep Med*. 2009;2009:591512. doi:10.1155/2009/591512
6. Adem C, Aubry MC, Tazelaar HD, Myers JL. Metastatic angiosarcoma masquerading as diffuse pulmonary hemorrhage: clinicopathologic analysis of 7 new patients. *Arch Pathol Lab Med*. 2001;125(12):1562-1565. doi:10.5858/2001-125-1562-MAMADP
7. Glancy DL, Morales JB Jr, Roberts WC. Angiosarcoma of the heart. *Am J Cardiol*. 1968;21(3):413-419. doi:10.1016/0002-9149(68)90144-6
8. Brandt RR, Arnold R, Bohle RM, Dill T, Hamm CW. Cardiac angiosarcoma: case report and review of the literature. *Z Kardiol*. 2005;94(12):824-828. doi:10.1007/s00392-005-0296-0
9. Reynen K, Kockeritz U, Strasser RH. Metastases to the heart. *Ann Oncol*. 2004;15(3):375-381. doi:10.1093/annonc/mdh086
10. Best AK, Dobson RL, Ahmad AR. Best cases from the AFIP: cardiac angiosarcoma. *Radiographics*. 2003;23 Spec No:S141-S145. doi:10.1148/rg.23si035140
11. Meng Q, Lai H, Lima J, Tong W, Qian Y, Lai S. Echocardiographic and pathologic characteristics of primary cardiac tumors: a study of 149 cases. *Int J Cardiol*. 2002;84(1):69-75. doi:10.1016/s0167-5273(02)00136-5
12. Grebenc ML, Rosado de Christenson ML, Burke AP, Green CE, Galvin JR. Primary cardiac and pericardial neoplasms: radiologic-pathologic correlation. *Radiographics*. 2000;20(4):1073-1103; quiz 1110-1111. doi:10.1148/radiographics.20.4.g00jl081073

13. Savoia MT, Liguori C, Nahar T, et al. Transesophageal echocardiography-guided transvenous biopsy of a cardiac sarcoma. *J Am Soc Echocardiogr.* 1997;10(7):752-755. doi:10.1016/s0894-7317(97)70120-2
14. Crenitte MRF, Galvao MD, Bernardi FDC, da Fonseca LG. Cardiac angiosarcoma: an unexpected diagnosis. *Autops Case Rep.* 2014;4(3):53-58. doi:10.4322/acr.2014.029
15. Yanagawa B, Mazine A, Chan EY, et al. Surgery for tumors of the heart. *Semin Thorac Cardiovasc Surg.* 2018;30(4):385-397. doi:10.1053/j.semtcvs.2018.09.001
16. Yanagawa B, Chan EY, Cusimano RJ, Reardon MJ. Approach to surgery for cardiac tumors: primary simple, primary complex, and secondary. *Cardiol Clin.* 2019;37(4):525-531. doi:10.1016/j.ccl.2019.07.001