

Case Series

Dronedaronone for the Treatment of Atrial Arrhythmias in Adults With Congenital Heart Disease

Mahdi S. Agha, MD¹; Peter R. Ermis, MD^{2,3}; Wayne J. Franklin, MD⁴; Dhaval R. Parekh, MD^{2,3}; Angeline D. Opina, MD^{2,3}; Jeffrey J. Kim, MD²; Christina Y. Miyake, MD, MS²; Santiago O. Valdes, MD²; Wilson W. Lam, MD^{2,3}

¹Department of Medicine, Baylor College of Medicine, Houston, Texas

²Department of Pediatrics, Division of Cardiology, Baylor College of Medicine, Houston, Texas

³Department of Medicine, Division of Cardiology, Baylor College of Medicine, Houston, Texas

⁴Department of Pediatrics, Division of Cardiology, The University of Arizona College of Medicine, Phoenix, Arizona



Abstract

Background: Atrial tachyarrhythmias are common and difficult to treat in adults with congenital heart disease. Dronedaronone has proven effective in patients without congenital heart disease, but data are limited about its use in adults with congenital heart disease of moderate to great complexity.

Methods: A single-center, retrospective chart review of 21 adults with congenital heart disease of moderate to great complexity who were treated with dronedaronone for atrial tachyarrhythmias was performed.

Results: The median (IQR) age at dronedaronone initiation was 35 (27.5-39) years. Eleven patients (52%) were male. Ten patients (48%) had New York Heart Association class I disease, 10 (48%) had class II disease, and 1 (5%) had class III disease. Ejection fraction at initiation was greater than 55% in 11 patients (52%), 35% to 55% in 9 patients (43%), and less than 35% in 1 patient (5%). Prior treatments included β -blockers (71%), sotalol (38%), amiodaronone (24%), digoxin (24%), and catheter ablation (38%). Rhythm control was complete in 5 patients (24%), partial in 6 (29%), and inadequate in 10 (48%). Two patients (10%) experienced adverse events, including nausea in 1 (5%) and cardiac arrest in 1 (5%), which occurred 48 months after initiation of treatment. There were no deaths during the follow-up period. The median (IQR) follow-up time for patients with complete or partial rhythm control was 20 (1-54) months.

Conclusion: Dronedaronone can be effective for adult patients with congenital heart disease and atrial arrhythmias for whom more established therapies have failed, and with close monitoring it can be safely tolerated.

Keywords: Dronedaronone; heart defects, congenital; atrial fibrillation; atrial flutter; arrhythmias, cardiac

Introduction

Atrial tachyarrhythmias such as atrial fibrillation (AF), atrial flutter, and intra-atrial re-entrant tachycardia (IART) are common in adults with congenital heart disease (CHD), and their management poses a major challenge. Arrhythmias can be intrinsic to the abnormal underlying anatomical substrate, develop as a result of surgical scars, or arise from chronic pressure and volume overload.¹ Current management strategies include β -blockers, sotalol, amiodaronone, digoxin, and catheter ablation, but these treatments can be ineffective or create unfavorable adverse effects. Additional treatment options are needed.

Dronedaronone is a class III antiarrhythmic medication that is effective in treating paroxysmal atrial fibrillation.² Because of its increased mortality risks, however, it is contraindicated in patients with New York Heart Association (NYHA) class III to IV heart failure and an ejection fraction less than 35%.³ Because of these findings in the general adult population, the 2014 Pediatric and Congenital Electrophysiology Society/Heart Rhythm Society expert

Citation: Agha MS, Ermis PR, Franklin WJ, Parekh DR, Opina AD, Kim JJ, Miyake CY, Valdes SO, Lam WW. Dronedaronone for the treatment of atrial arrhythmias in adults with congenital heart disease. *Tex Heart Inst J.* 2024;51(1):e227993. doi:10.14503/THIJ-22-7993

Corresponding author: Mahdi Agha, MD, Baylor College of Medicine, 1 Baylor Plaza, Houston, TX 77030 (mahdiagha@utexas.edu)

consensus guidelines give a class III contraindication for dronedarone use in adults with CHD of moderate to great complexity, regardless of NYHA class or ejection fraction, although no prior trials have evaluated the safety and efficacy of dronedarone specifically in the adult population with CHD.⁴ This study sought to present data on the safety and efficacy of dronedarone for the treatment of atrial tachyarrhythmias in the adult population with CHD.

Patients and Methods

This was a single-center, retrospective chart review of adult patients with CHD treated with dronedarone at Texas Children's Hospital and Baylor St Luke's Medical Center in Houston between 2011 and 2020. The study was approved by the institutional review board at Texas Children's Hospital. The decision to initiate dronedarone was made by the treating physician. Criteria for inclusion in the study were being older than 18 years of age, having CHD of moderate to great complexity, a history of atrial tachyarrhythmia, and prior or current treatment with dronedarone. The complexity of CHD was classified based on the 2018 American College of Cardiology and American Heart Association guidelines.⁵ Electronic health records were reviewed to collect patient demographics, CHD type and severity, atrial arrhythmia type, left ventricular ejection fraction, prior and current treatment, major adverse events, reason for discontinuation of dronedarone, hospitalizations during treatment, and degree of rhythm control.

The starting dose of dronedarone and subsequent dose increases were determined by the treating clinician. Follow-up and monitoring of patients were performed according to the drug manufacturer's recommendations. Because there is no recommended schedule for the monitoring of electrolytes, liver function, kidney function, electrocardiography, or echocardiography after the initiation of dronedarone, these results were obtained at the clinician's discretion. Patients had routine follow-up with their cardiologist to monitor degree of rhythm control, symptom control, and development of adverse events. An adverse event was defined as patient death while on treatment or any event that led to discontinuation of the medication.

Complete rhythm control was defined as conversion to or maintenance of normal sinus rhythm without substantial episodes of arrhythmia based on patient-reported symptoms and Holter monitor data. Partial rhythm control was defined as a clinically significant reduction

Key Points

- Atrial tachyarrhythmias are common and difficult to treat in adults with CHD.
- Dronedarone has proven effective in patients without CHD, but data on its use in adults with CHD are limited.
- Dronedarone can be effective for adult patients with CHD with atrial arrhythmias for whom more established therapies have failed, and with close monitoring it can be safely tolerated.

Abbreviations and Acronyms

AF	atrial fibrillation
CHD	congenital heart disease
IART	intra-atrial re-entrant tachycardia
NYHA	New York Heart Association

in the frequency or duration of the arrhythmia based on patient-reported symptoms and Holter monitor data, such that the clinician considered the medication worth continuing rather than switching to an alternative rhythm control medication or ablation.

Statistical Analysis

Outcomes are presented in a descriptive manner. Median (IQR) values are provided when the data are not expected to follow a normal distribution. Mean (SD) values are provided when the data are expected to follow a normal distribution.

Results

Twenty-nine adults with CHD of moderate to great complexity who were prescribed dronedarone for atrial tachyarrhythmias were identified. Of the 29 adults who met the selection criteria, 8 were excluded for any of several reasons, including incomplete records regarding treatment (n = 5), transfer of care to a different institution (n = 2), and inability to afford the medication (n = 1). Twenty-one patients were included in the study. Table I presents the types of CHD of moderate to great complexity in the study sample. The median (IQR) age of initiation of dronedarone was 35 (27.5-39) years. Eleven patients (52%) were men, and 10 (48%) were women. By anatomic complexity, 8 patients (38%) had CHD of moderate complexity, and 13 (62%) had lesions of great complexity. Ten patients (48%) had NYHA class I disease; 10 (48%) had class II disease; and 1 (5%) had class III disease. Ejection fraction at initiation was greater than 50% in

TABLE I. Congenital Heart Disease Characteristics, by Complexity Type

Congenital malformation	Patients, No. (%) ^a (N = 21)
D-transposition of the great arteries	9 (43)
Tetralogy of Fallot	4 (19)
Shone complex	2 (10)
Pulmonary atresia	2 (10)
L-transposition of the great arteries	1 (5)
Tricuspid atresia	1 (5)
Partial atrioventricular canal	1 (5)
Aortic stenosis	1 (5)

^a Percentages may not add up to 100% because of rounding.

15 patients (71%); 40% to 49% in 4 patients (19%); 30% to 39% in 1 patient (5%); and less than 30% in 1 patient (5%). Dronedarone was used for the treatment of AF only in 5 patients (24%), atrial flutter only in 5 patients (24%), IART only in 8 patients (38%), both AF and atrial flutter in 2 patients (10%), and both IART and atrial flutter in 1 patient (5%). Patients were previously treated with β -blockers (71%), sotalol (38%), amiodarone (24%), digoxin (24%), and diltiazem (5%). Eight patients (38%) had undergone prior catheter ablation. Four patients (19%) had prior implantable cardioverter-defibrillator placement, and 11 patients (52%) had prior permanent pacemaker placement. All patients had had prior surgical repair. The Maze procedure had been performed in 3 patients (14%). The mean (SD) number of surgical procedures, including Maze procedures, was 1.81 (0.98). Six patients (29%) had previously undergone tetralogy of Fallot–like repair; 5 patients (24%) had had prior atrial switch operations; 5 patients (24%) had had prior Fontan procedures; 3 patients (14%) had had prior biventricular congenitally corrected transposition of the great arteries repair; and 1 patient (5%) had had prior atrioventricular septal defect repair. Table II summarizes patient demographics.

The standard dosage of dronedarone is 400 mg twice daily. Sixteen patients (76%) were initiated on the standard dose without dose adjustment. One patient (5%) was started on the standard dose and increased to

400 mg in the morning, 200 mg at noon, and 400 mg in the evening. One patient (5%) was started on 400 mg daily and increased to the standard dosage. One patient (5%) was started on 200 mg twice per day and increased to the standard dosage. Two patients (10%) were started on 200 mg twice per day and did not increase to the standard dosage.

Treatment was initiated in an outpatient setting for 18 patients (86%), in an inpatient one for 1 patient (5%), and in an unknown setting for 2 patients (10%). Median (IQR) QT interval corrected for heart rate was 474 (451-494) milliseconds before initiation and 486 (460-538) milliseconds after initiation.

Complete rhythm control was achieved in 5 patients (24%). Of these 5 patients, 1 was treated for AF, 1 was treated for atrial flutter, 1 was treated for both AF and flutter, and 2 were treated for IART. Four patients (19%) had remained on therapy by the study end date, and 1 patient (5%) discontinued therapy as a result of pregnancy.

Dronedarone was discontinued in 10 patients (48%) because of inadequate rhythm control. The median (IQR) duration of therapy in patients who discontinued dronedarone as a result of inadequate control was 14 (2-27) months, with 40% of those patients discontinuing therapy within 3 months.

Partial rhythm control was achieved in 6 patients (29%). Of these 6 patients, 4 (19%) discontinued therapy after receiving catheter ablation, and 2 (10%) discontinued therapy as a result of adverse events. There were no deaths during the follow-up period.

One patient discontinued treatment because of nausea, which was documented 6 months after initiation. One patient experienced an out-of-hospital ventricular fibrillation cardiac arrest and was successfully resuscitated. His congenital malformation was dextrotransposition of the great arteries, double-outlet right ventricle, ventricular septal defect, and left ventricular outflow obstruction. The patient had no history of ventricular arrhythmia. Holter monitoring performed 1 year after initiation of dronedarone showed 0.8% premature ventricular contraction and no ventricular arrhythmias. The patient had NYHA class II disease and a normal ejection fraction on initiation of dronedarone. The patient was on standard dosing of dronedarone. The event occurred 48 months after initiation of dronedarone. The patient's QRS duration was 138 milliseconds before drug initiation

TABLE II. Patient Characteristics

Characteristic	Patients ^a (N = 21)
Age, median (IQR), y	35 (27.5-39)
Sex, No. (%)	
Male	11 (52)
Female	10 (48)
NYHA class, No. (%)	
I	10 (48)
II	10 (48)
III	1 (5)
Ejection fraction, No. (%)	
>55%	11 (52)
35%-55%	9 (43)
<35%	1 (5)
Arrhythmia type, No. (%)	
AF	7 (33)
Atrial flutter	8 (38)
IART	–
Prior treatments, ^b No. (%)	
β-blockers	15 (71)
Sotalol	8 (38)
Amiodarone	5 (24)
Digoxin	5 (24)
Catheter ablation	8 (38)

AF, atrial fibrillation; IART, intra-atrial re-entrant tachycardia; NYHA, New York Heart Association.

^a Percentages may not add up to 100% because of rounding.

^b Patients may have received multiple prior treatments.

and 148 milliseconds after. His QT interval corrected for heart rate was 467 milliseconds before initiation of dronedarone, 490 milliseconds after initiation, 504 milliseconds on the day before his cardiac arrest, and 507 milliseconds on admission to the hospital. The patient's potassium level on admission to the hospital was 3.0 mmol/L (3.0 mEq/L). The incidence of sudden cardiac arrest in the study was 2.5 per 100 patient-years on treatment.

Figure 1 summarizes the efficacy and safety outcomes of the study. The median (IQR) duration of therapy for patients with complete or partial rhythm control was 20 (1-54) months. The maximum duration of therapy was 5.5 years.

Discussion

Dronedarone is an established treatment in patients without CHD for paroxysmal AF and atrial flutter, but it is contraindicated in patients with NYHA class III to IV heart failure or an ejection fraction less than 35% because of evidence of increased mortality.³ Current guidelines also give a class III contraindication against dronedarone in CHD of moderate to great complexity, regardless of NYHA class or ejection fraction, although there are no previous trials evaluating its safety or efficacy in adult patients with CHD to support this recommendation.⁴ All patients included in this study had CHD of moderate to great complexity.

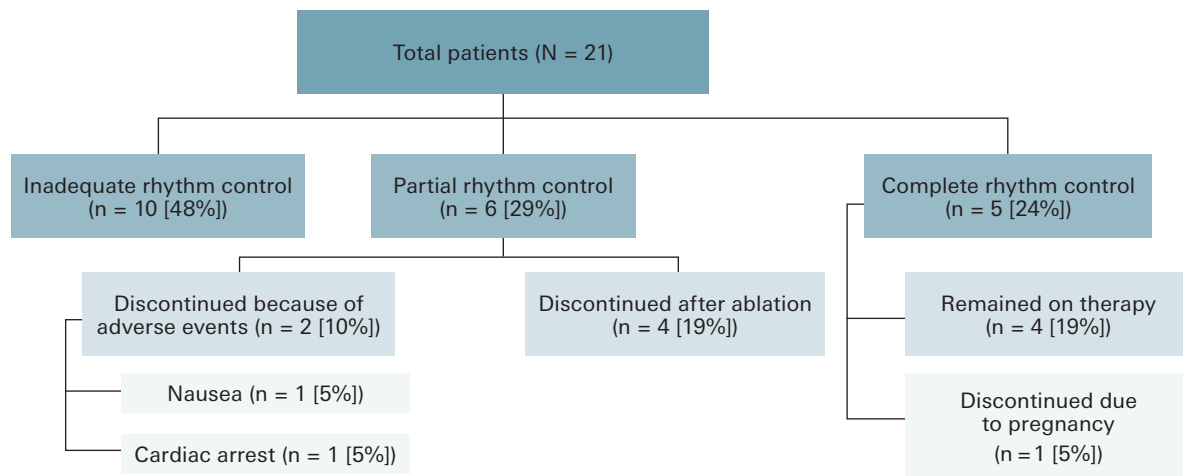


Fig. 1 A flowchart presents the efficacy and safety outcomes of dronedarone in the study.

The study sample was representative of an adult population with CHD with difficult-to-treat atrial tachyarrhythmia. All patients in the study had undergone cardiac surgery, the majority of these surgeries being complex procedures. All patients had also had prior treatment for atrial tachyarrhythmias that were either ineffective or unfavorable as a result of side effect profiles.

Despite prior treatments that had failed, the majority of patients in the study did achieve at least partial rhythm control with dronedarone, and 5 patients (24%) achieved complete rhythm control. Dronedarone is not as efficacious as more established therapies, such as amiodarone,⁶ but it does benefit from a more favorable side effect profile and can be easily initiated in the outpatient setting, in contrast to dofetilide, for example.⁷⁻⁹

The most common reason for discontinuation was inadequate rhythm control. There were no deaths during the study period, although there was 1 out-of-hospital cardiac arrest (the patient was successfully resuscitated). Though it is impossible to conclude from this case series whether dronedarone contributed to this patient's cardiac arrest, it is well established that patients with CHD of moderate to great complexity are at increased baseline risk for ventricular tachyarrhythmias and cardiac arrest. For comparison, the incidence of death reported in patients without CHD but with additional cardiac risk factors being treated with dronedarone was reported to be 5.0%.¹⁰ Patients with CHD initiated on dronedarone nonetheless warrant close monitoring.

Study Limitations

The study was limited by its small sample size (N = 21) and retrospective, single-center design. Patients were initiated on dronedarone at their clinician's discretion, which could introduce sampling bias. One patient was excluded because of their inability to afford the medication, which could also introduce sampling bias. Congenital heart disease is furthermore an inherently heterogeneous disease, making it difficult to interpret data, make generalizations, and perform randomized studies. As dronedarone becomes more frequently used in patients with CHD, it is the authors' hope to present larger studies on this therapy.

Conclusion

This study's results show that dronedarone can be effective for some patients with atrial arrhythmias for whom other therapies have failed, and with close monitoring it can be safely tolerated. It is suggested that dronedarone may provide a mild benefit in the treatment of atrial tachyarrhythmias in adults with CHD for whom more established therapies have failed.

Article Information

Published: 30 April 2024

Open Access: © 2024 The Authors. Published by The Texas Heart Institute®. This is an Open Access article under the terms

of the Creative Commons Attribution-NonCommercial License (CC BY-NC, <https://creativecommons.org/licenses/by-nc/4.0/>), which permits use and distribution in any medium, provided the original work is properly cited, and the use is noncommercial.

Author Contributions: Mahdi Agha was responsible for data collection, data analysis and interpretation, drafting the article, and critical revision. Wilson Lam was responsible for the study design, data analysis and interpretation, critical revision, and approval of the article. Peter Ermis, Wayne Franklin, Dhaval Parekh, Angeline Opina Gonzalez, Jeffrey Kim, Christina Miyake, and Santiago Valdes were responsible for critical revision and approval of the article.

Conflict of Interest Disclosure: None.

Funding/Support: None.

References

- Walsh EP, Cecchin F. Arrhythmias in adult patients with congenital heart disease. *Circulation*. 2007;115(4):534-545. doi:10.1161/CIRCULATIONAHA.105.592410
- Preobrazhenskii DV. Efficacy of dronedarone for maintenance of sinus rhythm in atrial fibrillation or flutter. Results of the EURIDIS and ADONIS. Article in Russian. *Kardiologiya*. 2008;48(7):58-59.
- Køber L, Torp-Pedersen C, McMurray JJV, et al; Dronedarone Study Group. Increased mortality after dronedarone therapy for severe heart failure. *N Engl J Med*. 2008;358(25):2678-2687. doi:10.1056/NEJMoa0800456
- Khairy P, Van Hare GF, Balaji S, et al. PACES/HRS expert consensus statement on the recognition and management of arrhythmias in adult congenital heart disease: developed in partnership between the Pediatric and Congenital Electrophysiology Society (PACES) and the Heart Rhythm Society (HRS). Endorsed by the governing bodies of PACES, HRS, the American College of Cardiology (ACC), the American Heart Association (AHA), the European Heart Rhythm Association (EHRA), the Canadian Heart Rhythm Society (CHRS), and the International Society for Adult Congenital Heart Disease (ISACHD). *Heart Rhythm*. 2014;11(10):e102-e165. doi:10.1016/j.hrthm.2014.05.009
- Stout KK, Daniels CJ, Aboulhosn JA, et al. 2018 AHA/ACC guideline for the management of adults with congenital heart disease: executive summary: a report of the American College of Cardiology/American Heart Association Task Force on Clinical Practice Guidelines. *J Am Coll Cardiol*. 2019;73(12):1494-1563. doi:10.1016/j.jacc.2018.08.1028
- Moore BM, Cordina RL, McGuire MA, Celermajer DS. Adverse effects of amiodarone therapy in adults with congenital heart disease. *Congenit Heart Dis*. 2018;13(6):944-951. doi:10.1111/chd.12657
- El-Assaad I, Al-Kindi SG, Abraham JE, et al. Use of dofetilide in adult patients with atrial arrhythmias and congenital heart disease: a PACES collaborative study. *Heart Rhythm*. 2016;13(10):2034-2039. doi:10.1016/j.hrthm.2016.07.016
- Banchs JE, Baquero GA, Nickolaus MJ, et al. Clinical efficacy of dofetilide for the treatment of atrial tachyarrhythmias in adults with congenital heart disease. *Congenit Heart Dis*. 2014;9(3):221-227. doi:10.1111/chd.12129
- Wells R, Khairy P, Harris L, Anderson CC, Balaji S. Dofetilide for atrial arrhythmias in congenital heart disease: a multicenter study. *Pacing Clin Electrophysiol*. 2009;32(10):1313-1318. doi:10.1111/j.1540-8159.2009.02479.x
- Hohnloser SH, Crijns HJGM, van Eickels M, et al; ATHENA Investigators. Effect of dronedarone on cardiovascular events in atrial fibrillation. *N Engl J Med*. 2009;360(7):668-678. doi:10.1056/NEJMoa0803778