

# Off-Pump Continuous-Flow Left Ventricular Assist Device Implantation

Ismael A. Salas De Armas, MD<sup>1,2</sup>; Jayeshkumar A. Patel, MD<sup>1,2</sup>; Mehmet H. Akay, MD<sup>1,2</sup>; Manish K. Patel, MD<sup>1,2</sup>; Keshava Rajagopal, MD, PhD<sup>1,2</sup>; Mehmet N. Karabulut, MD<sup>1,2</sup>; Biswajit Kar, MD<sup>1,2</sup>; Igor D. Gregoric, MD<sup>1,2</sup>

<sup>1</sup>Department of Advanced Cardiopulmonary Therapies and Transplantation, University of Texas Health Science Center at Houston, Houston, Texas

<sup>2</sup>Center for Advanced Heart Failure, Memorial Hermann Hospital–Texas Medical Center, Houston, Texas

*Continuous-flow left ventricular assist device implantation is the typical treatment for end-stage heart failure. Improvements in device engineering and technology, surgical experience and technique, and perioperative management have advanced the field, and short-term results approach those of heart transplantation. Further improvements may be achieved by minimizing adverse physiologic effects associated with cardiopulmonary bypass. Therefore, we have developed an off-pump implantation approach for continuous-flow left ventricular assist devices. We detail our surgical technique for off-pump implantation of the HeartWare device. (Tex Heart Inst J 2021;48(1):e197033)*

**Citation:**

Salas De Armas IA, Patel JA, Akay MH, Patel MK, Rajagopal K, Karabulut MN, Kar B, Gregoric ID. Off-pump continuous-flow left ventricular assist device implantation. *Tex Heart Inst J* 2021;48(1):e197033. doi: [10.14503/THIJ-19-7033](https://doi.org/10.14503/THIJ-19-7033)

**Key words:** Cardiopulmonary bypass/adverse effects; equipment design; heart failure/surgery; heart-assist devices; postoperative complications/prevention & control; prosthesis implantation/methods; treatment outcome

**Corresponding author:**

Igor D. Gregoric, MD, 6400 Fannin St., Suite 2350, Houston, TX 77030

**E-mail:** [igor.d.gregoric@uth.tmc.edu](mailto:igor.d.gregoric@uth.tmc.edu)

© 2021 by the Texas Heart<sup>®</sup> Institute, Houston

**C**ontinuous-flow (CF) left ventricular assist device (LVAD) implantation has traditionally been performed through a median sternotomy with use of normothermic full cardiopulmonary bypass (CPB) support under beating-heart conditions. Induced diastolic cardiac arrest by means of aortic cross-clamping and administering cardioplegic solution is generally used selectively when a concomitant left-sided intracardiac procedure is necessary. Alternative minimally invasive approaches to CF-LVAD implantation include the following: left anterior thoracotomy in conjunction with an upper hemisternotomy, left anterior thoracotomy and a right upper intercostal approach, and simple left thoracotomy with an outflow-graft anastomosis to the descending thoracic aorta or to the left subclavian or axillary artery.<sup>1-3</sup> Regardless of the approach, most CF-LVAD implantations are performed with use of CPB.<sup>1-3</sup>

The detrimental effects and complications of CPB are well characterized. These include systemic immune inflammatory response with platelet damage, sequestration, and fibrinolysis, which cause end-organ damage; acute lung injury; renal dysfunction; and stroke.<sup>4,5</sup> The heparin requirements to initiate and maintain CPB, as well as the platelet dysfunction and coagulopathy that occur after CPB, increase the risk of perioperative bleeding and the need for blood transfusion, which in turn contribute to volume overload and possible right ventricular dysfunction and failure.<sup>6</sup> Advances in engineering and technology have enabled the development of more efficient and durable CF-LVADs, with coinciding improvements in clinical outcomes.<sup>7</sup> The HeartWare HVAD (Medtronic), an LVAD system for advanced heart failure management, has been approved by the United States Food and Drug Administration for bridge-to-transplant and destination therapy. Its intrapericardial placement, small size, and cylindrical coring ventricular knife with a conical anvil make it favorable for implantation without CPB. Furthermore, we have experience in placing the HVAD's inflow cannula into the inferior diaphragmatic surface of the LV while an off-pump retractor is placed close to the LV apex.<sup>8</sup> However, the inflow cannula can also be placed in the standard apical LV position without CPB.

We present our modified invasive technique for off-pump implantation of the HeartWare HVAD inflow cannula into the LV diaphragmatic surface.

## Technique

The patient is placed under general anesthesia and is supine on the operating table. Transesophageal echocardiography (TEE) is performed to evaluate ventricular function, valvular function, and intracardiac abnormalities such as shunts and intracavitary thrombus, to confirm that no concomitant intracardiac procedure is needed.

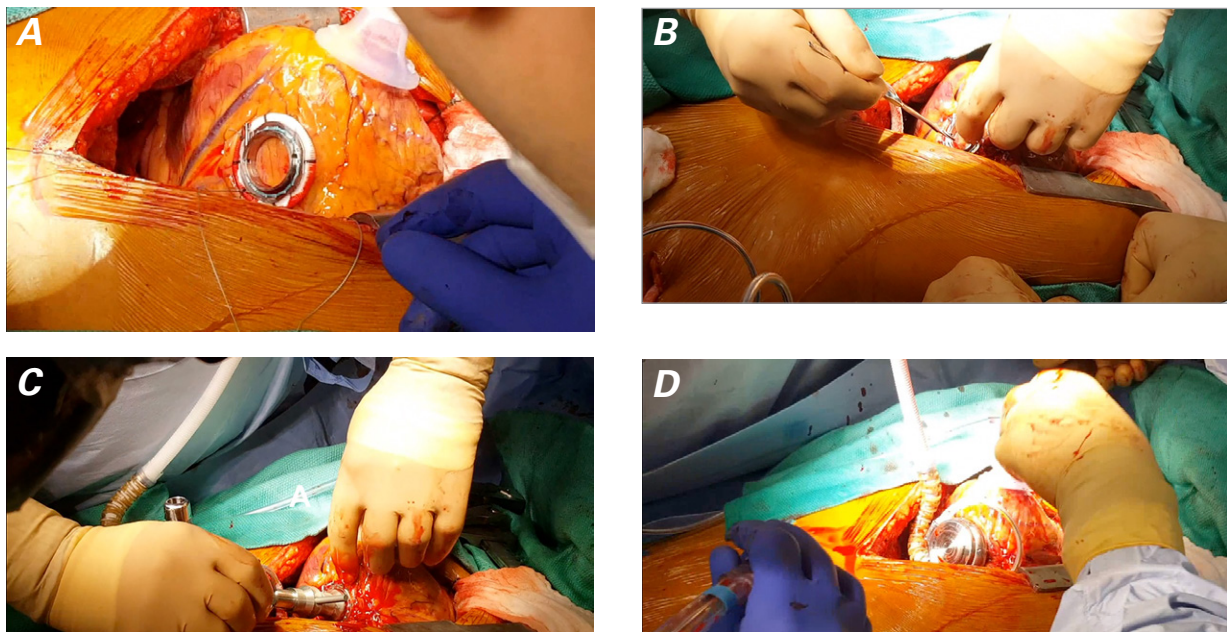
A standard median sternotomy is performed. For greater exposure during inflow cannula placement, the midline incision is extended 1 to 2 cm below the xiphoid process. The sternum is divided, and a sternal retractor is placed with the bar superior to the incision, thus clearing access to the LV and providing an anchor for the off-pump retractor. The pericardium is opened longitudinally from the diaphragm to its reflection at the great vessels and transversely rightward and leftward.

To create a site for the driveline exit, a transverse stab incision is made on the left abdominal wall, extending to the rectus abdominis. A Sarot clamp is inserted through the abdominal wall, then advanced behind the fascia and into the mediastinum. A 28F chest tube is passed through this tract. A tunneler device is advanced through the chest tube and is used to guide the driveline until it exits and is connected to the controller.

The patient is systemically anticoagulated with an intravenous bolus of 100 U/kg of heparin; an activated clotting time >200 sec should be obtained. The implantation procedure then begins (Fig. 1). The cardiac apex is elevated anterosuperiorly to expose the LV dia-

phragmatic surface. During this maneuver, the patient's systemic venous return may be impeded; typically, this is transient and responds to judicious volume-loading and manipulation of inotropic and vasoactive support. A laparotomy sponge is placed behind the heart on the left pericardial surface. A Hercules 3 Universal Stabilizer Arm (Terumo Cardiovascular Systems Corporation) is placed on the cardiac apex for stabilization. The inflow cannulation site is determined by locating the point on the diaphragmatic surface of the LV that lies approximately two thirds of the distance from the base to the apex of the heart. This site should be 1 cm left of the posterior descending coronary artery. Next, the sewing ring is secured to the inferior LV surface. Interrupted pledgeted horizontal mattress sutures are placed around the planned inflow cannulation site in deep partial thicknesses of the LV myocardium, sequentially passed through the sewing ring, and tied down. For expedient tying, an automated fastener device may be used. The integrated screw of the sewing ring is oriented perpendicular to the posterior descending coronary artery.

The HVAD is de-aired by irrigating the outflow graft with saline solution until it flows through the inflow portion. The outflow graft is clamped while the surgical assistant holds it so that it points anteriorly, to minimize the risk of air entering the LV cavity during implantation. A 15-blade scalpel is used to create a cruciate stab incision in the LV within the inner metal ring of the HVAD's sewing ring. An autotransfusion device is placed in the pericardial cavity to retrieve the ventriculotomy blood for later transfusion back into the



**Fig. 1** Intraoperative photographs. **A)** The cardiac apex is elevated, and the sewing ring of the HeartWare HVAD is secured to the diaphragmatic surface of the left ventricle. **B)** A scalpel is used to make a cruciate stab incision within the sewing ring. **C)** The coring knife and conical anvil are inserted into the left ventricle, with the cylindrical knife open. **D)** The HeartWare inflow cannula is placed to engage the metal ring while the saline-filled outflow graft is directed anteriorly.

patient. Immediately after making the cruciate incision, the surgeon inserts an index finger through the left ventriculotomy to evaluate LV wall thickness and to locate the interventricular septum in relation to the ventriculotomy. The interventricular septum should be parallel to the inflow cannulation site.

Immediately after the surgeon's finger is withdrawn, the conical anvil of the HeartWare coring knife is inserted into the LV through the sewing ring, with the cylindrical knife open. The blade is closed, a plug of the myocardium is excised, and the knife is rapidly retrieved. Next, the HVAD inflow cannula is inserted into the LV and advanced until the HVAD engages the inner metal ring of the sewing ring. When device position is satisfactory, the bolt on the inner middle part of the sewing ring is tightened until a click is heard. The retractor is then removed, and the heart is returned to its natural position.

A partial-occlusion clamp is placed on the ascending thoracic aorta, and the outflow graft is clamped proximally. The outflow graft is then cut to an appropriate length and sharply beveled. An axial aortotomy and an end-to-side outflow graft-to-ascending aorta anastomosis are created in standard fashion. The patient is placed in the Trendelenburg position, the partial-occlusion clamp is removed, and hemostasis is checked. The pump is started at 1,800 rpm, and de-airing is performed under TEE guidance. An 18G needle is placed in the outflow graft, and the graft clamp is released slowly, to ensure that no air is detected on TEE. The HVAD speed is increased incrementally. Final speed is established in accordance with these factors, in decreasing order of importance: overall hemodynamic status (satisfactory mean arterial pressure, HVAD flow rate and cardiac index, and pulmonary artery oxygen saturation), minimization of mitral valve regurgitation and at least intermittent opening of the aortic valve, and atrial and ventricular septal position. Protamine is administered, the HVAD is covered with a thin Gore-Tex membrane (W.L. Gore & Associates, Inc.), and routine closure is performed.

---

## Discussion

Little has been published on CF-LVAD implantation without CPB. Our group<sup>9</sup> has reported encouraging short-term results, including safety, shorter operative and mechanical ventilation times, less bleeding, and less need for transfusion. Of importance, avoidance of blood-product transfusions is associated with better outcomes in general cardiac surgery, and it results in less allosensitization in patients who undergo heart transplantation.<sup>9</sup>

Strueber and colleagues<sup>10</sup> reported their use of a minimally invasive approach (thoracotomy or ministernotomy) when implanting 26 HVADs off-pump. Their

patient population included individuals with Interagency Registry for Mechanically Assisted Circulatory Support (INTERMACS) scores of 2 or 3,<sup>10</sup> whereas our technique has also been used in higher-risk patients who had INTERMACS scores of 1.<sup>9</sup> However, in contrast with Strueber and colleagues, we prefer an invasive approach. Median sternotomy enables rapid access to the major anatomic structures for immediate cannulation. Full sternotomy enables open cardiac massage and internal defibrillation, and CPB can be reestablished rapidly in cases of hemodynamic instability, especially in INTERMACS 1 and 2 patients. Finally, sternotomy enables the anastomosis to the ascending aorta, instead of to the descending aorta as is done in some minimally invasive procedures. Of note are our additional modifications to earlier techniques: our use of a retractor aids stabilization, and digital exploration of the cavity enables improved placement of the inflow cannula.

Off-pump CF-LVAD implantation can improve surgical outcomes in patients with advanced heart failure who do not need concomitant intracardiac procedures. Avoiding CPB prevents major inflammatory cascade activation and decreases the risks of vasoplegia and coagulopathy after LVAD implantation in these high-risk patients.

---

## Acknowledgment

We thank R. Michelle Sauer, PhD, ELS, for her editorial assistance.

**Published:** 4 May 2021

## References

1. Ghodsizad A, Kar BJ, Loyalka P, Okur A, Gonzales J, Bara C, et al. Less invasive off-pump implantation of axial flow pumps in chronic ischemic heart failure: survival effects. *J Heart Lung Transplant* 2011;30(7):834-7.
2. Gregoric ID, La Francesca S, Myers T, Cohn W, Loyalka P, Kar B, et al. A less invasive approach to axial flow pump insertion. *J Heart Lung Transplant* 2008;27(4):423-6.
3. Maltais S, Davis ME, Haglund N. Minimally invasive and alternative approaches for long-term LVAD placement: the Vanderbilt strategy. *Ann Cardiothorac Surg* 2014;3(6):563-9.
4. Belhaj A. Actual knowledge of systemic inflammation reaction during cardiopulmonary bypass. *Recent Pat Cardiovasc Drug Discov* 2012;7(3):165-9.
5. Rossaint J, Berger C, Van Aken H, Scheld HH, Zahn PK, Rukosujew A, Zarbock A. Cardiopulmonary bypass during cardiac surgery modulates systemic inflammation by affecting different steps of the leukocyte recruitment cascade. *PLoS One* 2012;7(9):e45738.
6. Boyle AJ, Ascheim DD, Russo MJ, Kormos RL, John R, Naka Y, et al. Clinical outcomes for continuous-flow left ventricular assist device patients stratified by pre-operative INTERMACS classification. *J Heart Lung Transplant* 2011;30(4):402-7.
7. Lampert BC, Teuteberg JJ. Right ventricular failure after left ventricular assist devices. *J Heart Lung Transplant* 2015;34(9):1123-30.

8. Gregoric ID, Cohn WE, Frazier OH. Diaphragmatic implantation of the HeartWare ventricular assist device. *J Heart Lung Transplant* 2011;30(4):467-70.
9. Gregoric ID, Radovancevic R, Akay MH, Jezovnik MK, Nathan S, Patel M, et al. Short-term experience with off-pump versus on-pump implantation of the HeartWare left ventricular assist device. *ASAIO J* 2017;63(1):68-72.
10. Strueber M, Meyer AL, Feussner M, Ender J, Correia JC, Mohr FW. A minimally invasive off-pump implantation technique for continuous-flow left ventricular assist devices: early experience. *J Heart Lung Transplant* 2014;33(8):851-6.