

Optimizing P2 Neochordal Length and Stability in Mitral Valve Repair

With Use of a Polypropylene Loop

Anil Ozen, MD
Ertekin Utku Unal, MD
Hamdi Mehmet Ozbek, MD
Gorkem Yigit, MD
Hakki Zafer Iscan, MD

Determining the optimal length of artificial chordae tendineae and then effectively securing them is a major challenge in mitral valve repair. Our technique for measuring and stabilizing neochordae involves tying a polypropylene suture loop onto the annuloplasty ring. We used this method in 4 patients who had moderate-to-severe mitral regurgitation from degenerative posterior leaflet (P2) prolapse and flail chordae. Results of intraoperative saline tests and postoperative transesophageal echocardiography revealed only mild insufficiency. One month postoperatively, echocardiograms showed trivial regurgitation in all 4 patients. We think that this simple, precise method for adjusting and stabilizing artificial chordae will be advantageous in mitral valve repair. (Tex Heart Inst J 2020;47(3):207-9)

Surgical mitral valve (MV) repair is recommended for patients who have chronic, severe primary mitral regurgitation (MR) that is limited to the posterior leaflet (P2).¹ Implanting expanded polytetrafluoroethylene (ePTFE) artificial chordae tendineae is an established treatment²; however, accurately measuring artificial chordae and attaining a secure attachment is challenging. Even though several methods for measuring and adjusting neochordal length have been developed,³⁻⁶ none are ideal. We describe a simple technique, which we used successfully in 4 patients, that may prove useful to other surgeons.

Technique

Four patients who had moderate-to-severe mitral insufficiency due to prolapse of the P2 segment and flail chordae tendineae were treated from June through November 2018. The patients were 2 men (aged 52 and 58 yr) and two women (aged 45 and 48 yr). Each provided written informed consent before treatment.

After placing the patient under general anesthesia, we performed a median sternotomy, then instituted bicaval cannulation, started cardiopulmonary bypass, and cooled the patient to 32 °C. Next, we cross-clamped the aorta and achieved cardiac arrest by means of cardioplegia. Through an incision in the Waterston groove, we resected redundant MV tissue in a triangular or quadrangular fashion and began primary repair. We placed sutures for the annuloplasty ring on the mitral annulus, then measured the annulus for ring size. After verifying that the posteromedial papillary muscle adjacent to the flail chorda was intact and functional, we placed a single 5-0 ePTFE suture (the future neochorda) with 2 felt pledgets onto the head of the muscle and tied it. We passed the ring sutures through the annuloplasty ring, and as we lowered it, we passed the ePTFE suture through the opening of the ring. Finally, we tied the ring sutures to fasten the ring to the annulus.

At this point, we modified the conventional procedure for measuring and fastening the neochorda. We used a 3-0 polypropylene suture to create a small loop posteriorly on the annuloplasty ring at the level of the P2 segment (Fig. 1A). Referring to an adjacent native chorda to estimate neochordal length, we marked the measurement in ink on the 5-0 ePTFE suture. We then passed both ePTFE needles through the prolapsed leaflet from the ventricular side to the atrial side and upward through the polypropylene loop, and repeated this action (Fig. 1A-B). Gently pulling up both sides of the ePTFE suture eliminated slack and brought the mark on the suture to the approximate level of the MV (Fig. 1C).

Key words: Cardiac surgical procedures/methods; chordae tendineae/surgery; mitral valve/surgery; polytetrafluoroethylene; prosthesis fitting; suture techniques; treatment outcome

From: Department of Cardiovascular Surgery, Turkiye Yuksek Ihtisas Training and Research Hospital, 06230 Ankara, Turkey

Address for reprints:
Anil Ozen, MD,
Park Sitesi, Bilkent 2 Ihsan
Dogramaci Blv., Universiteler
Mahallesi, 06800 Ankara,
Turkey

E-mail:
anil_ozen@hotmail.com

© 2020 by the Texas Heart®
Institute, Houston

Before tying the suture on the atrial side, we looked through the ventricular side to ensure that the papillary muscle had not been strained and that the neochordal length matched that of the adjacent chorda. We then tied the ePTFE suture to the valve's atrial surface (Fig. 1D). To ensure stability, we passed both needles to the ventricular side of the valve and tied the suture again. Finally, we cut and removed the polypropylene loop and completed the surgical procedure.

Intraoperatively, saline testing revealed that all patients had only mild MR, and this was confirmed on transesophageal echocardiograms after cardiopulmonary bypass was stopped. All patients recovered uneventfully and were discharged from the hospital. Their echocardiograms at one month showed trivial MR.

Discussion

Valve repair is the first treatment option for patients who have myxomatous MV disease, and it often involves using ePTFE sutures to replace chordae tendineae.⁶ Imprecise neochordal length and sliding after knotting are major challenges, and various proposed solutions have been suboptimal.

New techniques and minimally invasive surgery have helped to refine neochordal placement. An early repair method, in which a small tourniquet was used to adjust suture length, proved unsuitable when prolapsed areas were wide.⁷ In addition, using curved hemostatic forceps damaged ePTFE sutures, and knots slid when the suture was held gently during fixation.

Von Oppell and Mohr⁸ created an ePTFE chordal loop after using a ruler to measure for length. This widely used technique is the basis for many others; however, the suture loop can distort the leaflet.⁹

Surgeons have also referred to the MV annular plane when adjusting neochordal length. Rodriguez-Roda and colleagues¹⁰ passed threads of the annuloplasty ring's P2 central segment suture down into the ring with a 90° dissector and pulled them out at the commissural level beneath, thus keeping the threads in the annular plane. Instead, we used the mitral ring as the annular plane of reference. Placing the 3-0 polypropylene suture loop posteriorly on the annuloplasty ring at the level of the prolapsed P2 segment enabled us to attain the appropriate basal-marginal chordal correspondence. After passing the neochordal suture twice through the mitral leaflet and polypropylene loop, we eliminated

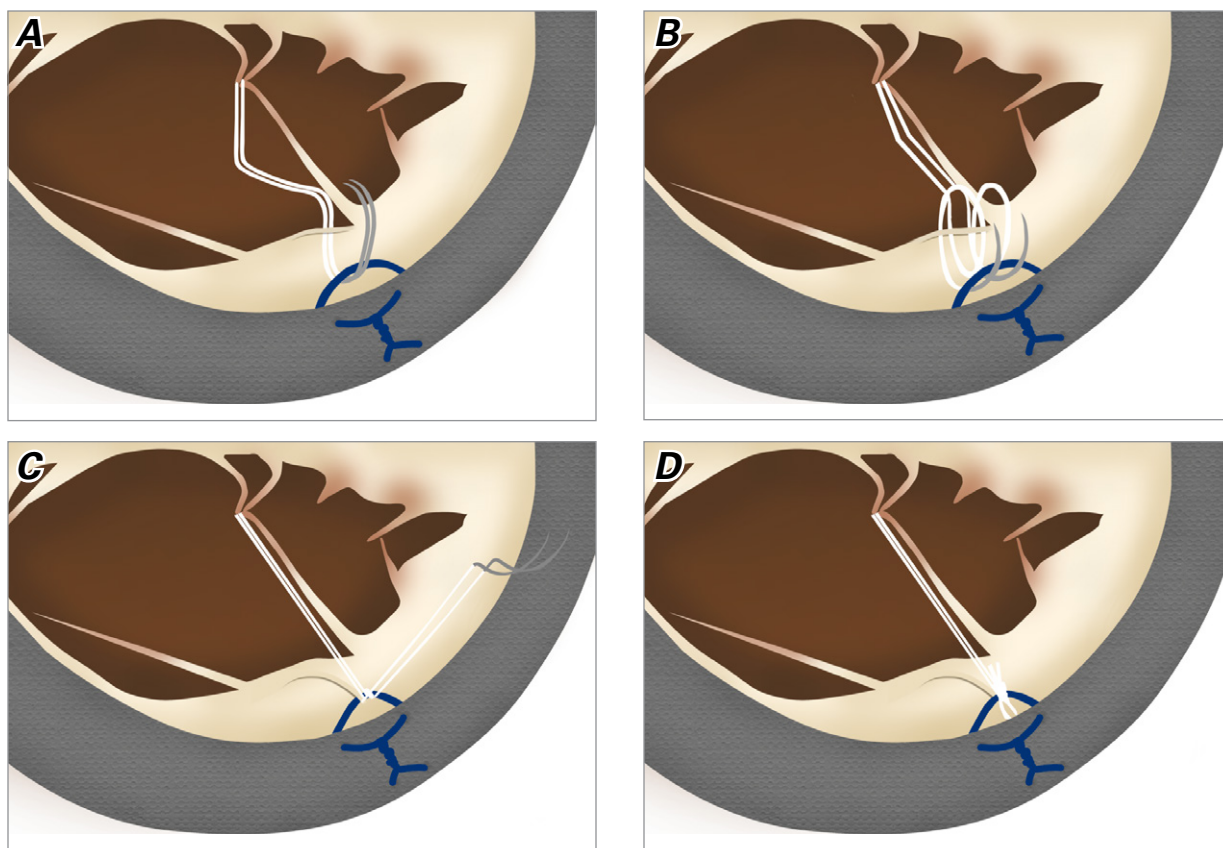


Fig. 1 Illustration shows **A**) both needles for the 5-0 expanded polytetrafluoroethylene (ePTFE) suture being passed upward through the mitral leaflet and the specially created 3-0 polypropylene loop once, **B**) then repeated. **C**) Both sides of the ePTFE suture are gently pulled up to eliminate slack, and after neochordal length and papillary muscle position are inspected through the ventricular side, **D**) the suture is tied onto the valve's atrial surface.

slack by pulling up both sides of the suture before tying the knot. In addition, marking the length of an adjacent chorda on the suture enabled neochordal adjustment.

When MR involves the P1 and P3 segments, patients need to undergo more complex procedures with more neochordae, increasing the challenge. We decided to apply our technique to P2 prolapse only. We did not consider using it in patients who had undergone previous MV surgery, had wide prolapse, or were elderly.

We think that our use of a polypropylene loop to adjust neochordal length and ensure stability is simple, effective, and advantageous for surgeons who perform MV repair.

Acknowledgment

We thank Damla Unal for her drawings of the repair process.

References

1. Nishimura RA, Otto CM, Bonow RO, Carabello BA, Erwin JP 3rd, Guyton RA, et al. 2014 AHA/ACC Guideline for the management of patients with valvular heart disease: a report of the American College of Cardiology/American Heart Association Task Force on Practice Guidelines [published errata appear in *Circulation* 2014;129(23):e651 and *Circulation* 2014;130(13):e120]. *Circulation* 2014;129(23):e521-e643.
2. Braun EU, Voss B, Mayer H, Knoll A, Bauernschmitt R, Lange R. Adjustment of artificial chordae to the mitral valve with advanced tactile technique. *Comput Cardiol* 2008;35:273-4.
3. Calafiore AM, Scandura S, Iaco AL, Contini M, Di Mauro M, Bivona A, et al. A simple method to obtain the correct length of the artificial chordae in complex chordal replacement. *J Card Surg* 2008;23(3):204-6.
4. Gillinov AM, Banbury MK. Pre-measured artificial chordae for mitral valve repair. *Ann Thorac Surg* 2007;84(6):2127-9.
5. Fattouch K, Bianco G, Sbraga F, Sampognaro R, Ruvolo G. Simple, safe and easy technique to ensure the correct length of artificial chordae in mitral valve repair. *Ann Thorac Surg* 2007;83(5):1902-3.
6. Matsui Y, Fukada Y, Naito Y, Sasaki S, Yasuda K. A new device for ensuring the correct length of artificial chordae in mitral valvuloplasty. *Ann Thorac Surg* 2005;79(3):1064-5.
7. Kasegawa H, Kamata S, Hirata S, Kobayashi N, Mannouji E, Ida T, Kawase M. Simple method for determining proper length of artificial chordae in mitral valve repair. *Ann Thorac Surg* 1994;57(1):237-9.
8. von Oppell UO, Mohr FW. Chordal replacement for both minimally invasive and conventional mitral valve surgery using premeasured Gore-Tex loops. *Ann Thorac Surg* 2000;70(6):2166-8.
9. Matsui Y, Kubota S, Sugiki H, Wakasa S, Ooka T, Tachibana T, Sasaki S. Measured tube technique for ensuring the correct length of slippery artificial chordae in mitral valvuloplasty. *Ann Thorac Surg* 2011;92(3):1132-4.
10. Rodriguez-Roda J, Miguelena J, Lopez J, Martin M, Munoz R. How to adjust neochordae length accurately in degenerative mitral regurgitation. *Ann Thorac Surg* 2018;105(4):e183-4.