

# Effectiveness of Artificial Neochordae Implantation in Tricuspid Valve Repair

Salih Salihi, MD  
H. Tarik Kiziltan, MD  
Ahmad Huraibat, MD  
Askin Ali Korkmaz, MD  
Ibrahim Kara, MD  
Mustafa Guden, MD

**Key words:** Cardiac surgical procedures/methods; chordae tendineae/surgery; disease-free survival; heart valve prosthesis implantation; prognosis; suture techniques; treatment outcome; tricuspid valve/pathology/physiopathology; tricuspid valve insufficiency/etiology/surgery

**From:** Department of Cardiovascular Surgery (Drs. Korkmaz and Salihi), Okan University Hospital, 34947 Istanbul; Department of Cardiovascular Surgery (Dr. Kiziltan), Ozel Adana Hospital, 01060 Adana; Department of Cardiology (Dr. Huraibat), Artvin State Hospital, 08000 Artvin; Department of Cardiovascular Surgery (Dr. Kara), Sakarya University, 54000 Sakarya; and Department of Cardiovascular Surgery (Dr. Guden), Medipol University, 34214 Istanbul; Turkey

**Address for reprints:** Salih Salihi, MD, Department of Cardiovascular Surgery, Okan University Hospital, 34947 Istanbul, Turkey

**E-mail:** drssalihi@yahoo.com

© 2019 by the Texas Heart<sup>®</sup> Institute, Houston

Various techniques for treating tricuspid regurgitation have been described; however, because of scarce data about the long-term outcomes of different repairs, the optimal technique has not been established. We evaluated the effectiveness and durability of artificial neochordae implantation in the treatment of tricuspid regurgitation.

From 2009 through 2014, 507 patients underwent tricuspid valve repair at our institution. Of those, 48 patients implanted with artificial neochordae were included in our study. The median age of the participants was 62 years (range, 4–77 yr) and 50% were women. Thirty patients (63%) were in New York Heart Association functional class III, and 11 (23%) were in class II. The cause of tricuspid regurgitation was functional in 33 patients (69%) and rheumatic in 15 (31%). In 46 patients, neochordae implantation was performed in addition to Kay annuloplasty (n=13) or ring annuloplasty (n=33).

Forty-two patients were discharged from the hospital with absent or mild tricuspid regurgitation. The mean follow-up period was 44.3 ± 20.2 months. Follow-up echocardiograms revealed that tricuspid regurgitation was absent, minimal, or mild in 38 patients (80.8%), moderate in 7, and severe in 2.

Our results indicate that the use of artificial neochordae implantation as an adjunct procedure to annuloplasty leads to effective and durable repair in comparison with conventional techniques for treating tricuspid regurgitation. (**Tex Heart Inst J 2019;46(2):100-6**)

**T**ricuspid regurgitation (TR) caused by primary lesions (organic disease) of the tricuspid valve (TV) is increasingly rare, particularly in western countries. However, rheumatic valve disease remains one of the most typical causes of primary TR in developing countries. In patients with this pathologic condition, TV motion is restricted by commissure fusion, chordae fusion, and thickening of the leaflets.<sup>1</sup> Tricuspid regurgitation typically develops secondary to other valvular disease (most often, mitral valve [MV] disease) that affects the left side of the heart.<sup>2</sup> The optimal timing and procedure for the surgical management of secondary TR are not established.<sup>3,4</sup> The correction of left-sided valvular disease without concomitant correction of functional TR is associated with significant late morbidity and mortality rates because of progressive right ventricular (RV) dysfunction and an increasing need for reoperation.<sup>5,6</sup> Several annuloplasty techniques have been used to correct TV dysfunction. Because severe dilation of the tricuspid annulus has been identified as the predominant lesion, these techniques have been aimed primarily at narrowing the orifice to achieve leaflet coaptation.<sup>3,7</sup> However, recurrence rates of 15% to 30% have been reported after tricuspid ring annuloplasty for the treatment of severe TR, and severe leaflet tethering is an independent predictor of TR recurrence after TV annuloplasty.<sup>8,9</sup> Implantation of neochordae made from polytetrafluoroethylene (PTFE), which are widely used in MV repair, is an option for replacing the chordae tendineae in patients with TV prolapse. The purpose of this study was to evaluate the effectiveness and durability of this technique in the treatment of TR.

## Patients and Methods

After our Institutional Ethics Committee's approval of this retrospective study, we searched our hospital's database for demographic, preoperative, intraoperative, and postoperative data on patients with TR. Of 507 who had undergone TV surgical repair at our hospital from January 2009 through December 2014, 48 also underwent implantation of expanded PTFE (e-PTFE) neochordae. These 48 patients had under-

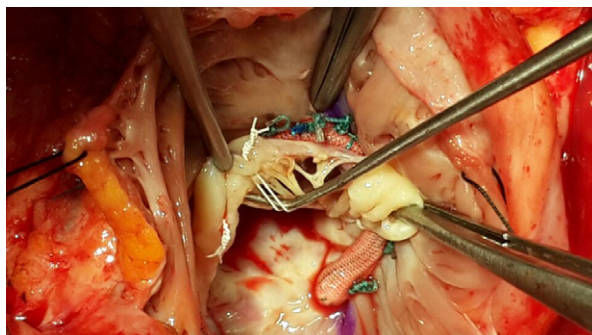
gone transthoracic echocardiography (TTE) preoperatively and before discharge from the hospital, as well as intraoperative transesophageal echocardiography (TEE) before and after repair.

### Surgical Techniques

All patients underwent median sternotomy. All procedures were performed with use of cardiopulmonary bypass (CPB) and moderate hypothermia. After an oblique right atriotomy was performed for optimal exposure, MV repair and concomitant procedures were completed through a transeptal approach. Subsequently, the structure and function of the TV were evaluated by means of intraoperative saline injection leak-testing. We clamped the pulmonary artery while the RV was filled with saline solution. Secondary TV regurgitation was corrected by ring annuloplasty or bicuspidization (Kay annuloplasty). Our strategy for TV repair was to perform Kay annuloplasty in patients who had a tricuspid annular diameter  $\geq 40$  mm and mild TR. If TR was moderate or severe, we performed ring annuloplasty.

In performing tricuspid ring annuloplasty, we determined the appropriate ring size from the surface area of the leaflet tissue attached to the chordae arising from the anterior papillary muscle. Tricuspid valve bicuspidization is accomplished by plicating the annulus along the posterior leaflet.<sup>7</sup> We used 5-0 e-PTFE sutures when replacing the chordae tendineae. The e-PTFE neochordae were implanted by initially attaching the suture to the head of the papillary muscle and subsequently passing it through the free margin of the prolapsed TV leaflet, from the ventricular side to the atrial side. The length was adjusted by using the nonprolapsed leaflet as a guide. Finally, more than 10 knots were used to tie the suture. In patients with rheumatic TV disease, nerve hooks were used to analyze the TV morphology and to detect valvular lesions (Fig. 1).

Commissurotomy with division of fused chordae and resection of secondary chordae was frequently performed as the initial procedure. Primary chordae resection was



**Fig. 1** Intraoperative photograph shows neochordae implantation on the anterior leaflet of a patient with rheumatic tricuspid valve disease.

performed in some patients to enable leaflet mobilization. We used artificial neochordae in these patients to repair prolapsed segments that resulted from the primary chordae resection. We evaluated TV competence after annuloplasty by filling the RV with saline solution and observing leaflet coaptation. We used TEE for our final evaluation of the repair after the patients were completely weaned from CPB. When TEE showed suboptimal results, a second cross-clamp was placed to achieve satisfactory repair.

All patients received anticoagulation for 3 months to maintain an international normalized ratio between 2 and 2.5. Lifelong anticoagulation was prescribed for patients who had atrial fibrillation (AF) or mechanical prostheses.

### Statistical Analysis

Parametric data are presented as mean  $\pm$  SD; nonparametric data are presented as median and range. Categorical variables are presented as number and percentage.

## Results

Table I documents the preoperative characteristics of the 48 patients. The median age was 62 years (range,

**TABLE I.** Preoperative Characteristics of the 48 Patients

Variable	Value
Female	24 (50)
Median age (yr) (range)	62 (4–77)
Weight (kg)	76 $\pm$ 11
Body surface area (m <sup>2</sup> )	1.85 $\pm$ 0.827
Hypertension	31 (64.6)
Diabetes mellitus	12 (25)
Coronary artery disease	9 (18.8)
NYHA functional class	
II	11 (22.9)
III	30 (62.5)
IV	7 (14.6)
Pulmonary artery pressure (mmHg)	48.9 $\pm$ 9.3
EuroSCORE	3.9 $\pm$ 1.7
Preoperative atrial fibrillation	22 (45.8)
Left ventricular ejection fraction	0.59 $\pm$ 0.06
TR severity	
Moderate	17 (35.4)
Severe	31 (64.6)
Tricuspid annular diameter (mm)	39.6 $\pm$ 2.9

NYHA = New York Heart Association; TR = tricuspid regurgitation

Unless otherwise stated, data are presented as number and percentage or as mean  $\pm$  SD.

4–77 yr), and 24 (50%) of the patients were women. The mean preoperative left ventricular ejection fraction was  $0.59 \pm 0.06$ .

Thirty patients (63%) were in New York Heart Association (NYHA) functional class III, and 11 (23%) were in class II. Preoperatively, 22 patients had AF. Cardiovascular comorbidities included MV disease in 42 patients and secundum atrial septal defects in 5 (Fig. 2). Table II shows the intraoperative data.

### Tricuspid Valve Disease and Repair

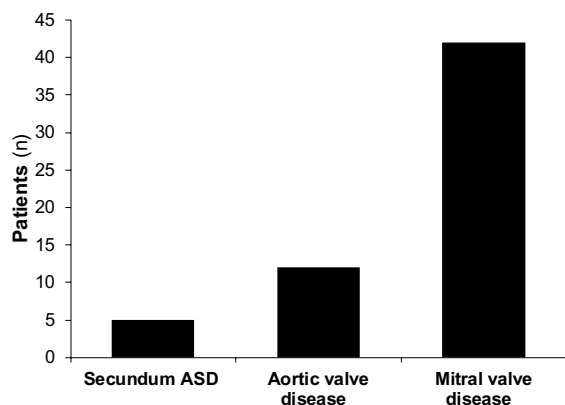
Table III lists the types of TV disease identified during surgery. Nineteen patients had anterior leaflet prolapse; 6 had involvement of both the posterior and septal leaflets. Commissural fusion was identified in 11 patients.

Patients with annular dilation and prolapse underwent bicuspidization (n=13) or ring annuloplasty (n=33) in addition to neochordae implantation and other techniques (commissurotomy or resection of chordae tendineae). Figure 3 shows the distribution of the prosthetic ring sizes.

In total, 103 chordae were replaced, as follows: 55 in the anterior leaflets of 30 patients, 33 in the septal leaflets of 12 patients, 3 in the posterior leaflets of 3 patients, and 12 in the septal and posterior leaflets of 3 patients.

### Concomitant Procedures

Concomitant procedures were performed in 46 patients. These included 14 MV repairs, 15 MV replacements, 9 MV replacements and aortic valve replacements, 3 aortic valve replacements with mitral repair, and closure of atrial septal defects in 5 patients. Left atrial radiofrequency ablation was performed in 12 patients who had preoperative AF. Left atrial appendage ligation was performed in all patients with preoperative AF.



**Fig. 2** Graph shows the distribution of the patients' preoperative cardiovascular comorbidities.

ASD = atrial septal defect

### Follow-Up Findings

Table IV shows the early and late complications after TV repair. Early (<30-d) death occurred in one patient who had low cardiac output syndrome. The mean intensive care unit stay for all patients was  $2.9 \pm 1.4$  days, and mean hospital stay,  $9 \pm 4$  days (Table II). New-onset AF in 6 patients was medically resolved in all cases. Six patients needed inotropic support for longer than 24 hours. One patient had a cerebrovascular accident.

Late follow-up data were obtained in 47 cases at an average of  $44.3 \pm 20.2$  months postoperatively. One patient died of noncardiac causes. One patient who needed reoperation to treat infective endocarditis underwent mechanical valve replacement 14 months after MV and TV repair.

**TABLE II.** Intraoperative Data of the 48 Patients

Variable	Value
Tricuspid valve regurgitation cause	
Functional (secondary)	33 (68.8)
Rheumatic (organic)	15 (31.3)
Techniques in addition to neochordae implantation	
Ring annuloplasty	26 (54.2)
Ring annuloplasty + commissurotomy	7 (14.6)
Bicuspidization	11 (22.9)
Bicuspidization + commissurotomy	2 (4.2)
Commissurotomy	2 (4.2)
Tricuspid ring size (mm)	$30.5 \pm 2$
Neochordae	
Anterior leaflet	30 (62.5)
Posterior leaflet	3 (6.3)
Septal leaflet	12 (25)
Septal and posterior leaflets	3 (6.3)
Concomitant surgical procedures	
MVR	15 (31.3)
MVR + AVR	9 (18.8)
MR	14 (29.2)
AVR + MR	3 (6.3)
Atrial septal defect repair	5 (10.4)
Radiofrequency ablation	12 (25)
Operative duration (min)	
Cardiopulmonary bypass	$89 \pm 21$
Aortic cross-clamp	$65 \pm 16$
ICU stay (d)	$2.9 \pm 1.4$
Hospital stay (d)	$9 \pm 4$

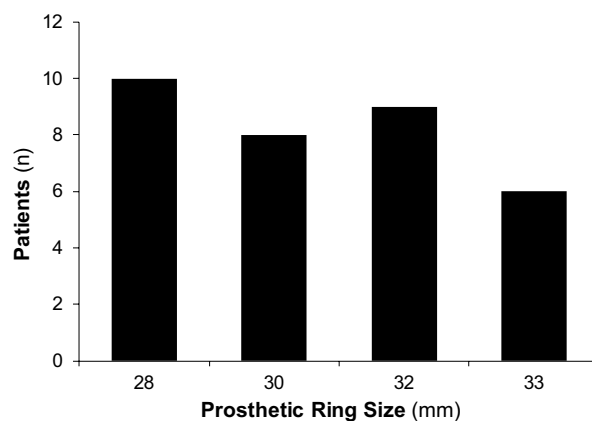
AVR = aortic valve replacement; ICU = intensive care unit; MR = mitral repair; MVR = mitral valve replacement

Data are presented as number and percentage or as mean  $\pm$  SD.

**TABLE III.** Types of Tricuspid Valve Disease in the 48 Patients

Variable	Value
Annular dilation	35 (72.9)
Leaflet prolapse	
Anterior	19 (39.6)
Posterior	3 (6.3)
Septal	12 (25)
Septal and posterior	6 (12.5)
Leaflet tethering	12 (25)
Chordal rupture	2 (4.2)
Anterior	1 (2.1)
Posterior	1 (2.1)
Leaflet retraction	4 (8.3)
Anterior	2 (4.2)
Posterior	1 (2.1)
Septal	1 (2.1)
Chordal retraction	
Anterior	5 (10.4)
Posterior	6 (12.5)
Septal	6 (12.5)
Anterior and posterior	4 (8.3)
Commissural fusion	11 (22.9)

Data are presented as number and percentage.



**Fig. 3** Graph shows the distribution of annuloplasty ring sizes in patients undergoing tricuspid valve repair.

Repair was satisfactory in all except 5 patients who had moderate TR when discharged from the hospital. The TV repair was successful in 38 patients, who presented with absent or minimal or with mild TR. Seven patients (including 3 who had moderate TR at hospital discharge) presented with moderate TR, which was asymptomatic with medical therapy. Four of these patients had undergone Kay annuloplasty in addition to artificial neochordae implantation. We identified left

**TABLE IV.** Early and Late Morbidity and Death in the 48 Patients

Variable	Value
Early (<30 d)	
Death	1 (2.1)
Complications	18 (37.5)
New-onset atrial fibrillation	6 (12.5)
Pleural effusion requiring drainage	3 (6.3)
Inotropic support >24 hr	6 (12.5)
Acute renal failure	2 (4.2)
Cerebrovascular accident	1 (2.1)
Late (≥30 d)	
Death	2 (4.2)
Noncardiac causes	2 (4.2)
Reoperation	1 (2.1)
Endocarditis	1 (2.1)
Thromboembolism	2 (4.2)

Data are presented as number and percentage.

ventricular dysfunction in 4 of the 7 patients who had moderate TR during follow-up. Severe TR developed in 2 patients who had undergone concomitant MV replacement and had left ventricular dysfunction (ejection fraction, ≤0.50). Table V and Figure 4 report the echocardiographic follow-up data of the patients.

## Discussion

Functional TR, which results mainly from dilation of the tricuspid annulus secondary to RV enlargement, is the most prevalent type of TV insufficiency.<sup>4</sup> Later in the course of the disease, tethering of the tricuspid leaflets due to displacement of the papillary muscles may also contribute to TR.<sup>10</sup> The principles of treatment for secondary TR include correcting increased RV afterload (by treating left-sided heart disease and optimizing left ventricular function) and correcting tricuspid annular dilation and dysfunction, usually by TV annuloplasty.<sup>4</sup> Traditionally, the primary goal of surgical treatment for secondary TR has been to correct tricuspid annular dilation by means of suture annuloplasty or ring annuloplasty. Most suture annuloplasty techniques are modified versions of Kay's bicuspidization technique or De Vega annuloplasty, which consist of plicating the posterior and anterior annulus.<sup>7,11</sup> In prosthetic ring annuloplasty, the annulus is permanently fixed in a systolic position, and the physiologic shape of the TV is restored.<sup>12</sup> However, none of these techniques has consistently eliminated functional TR.

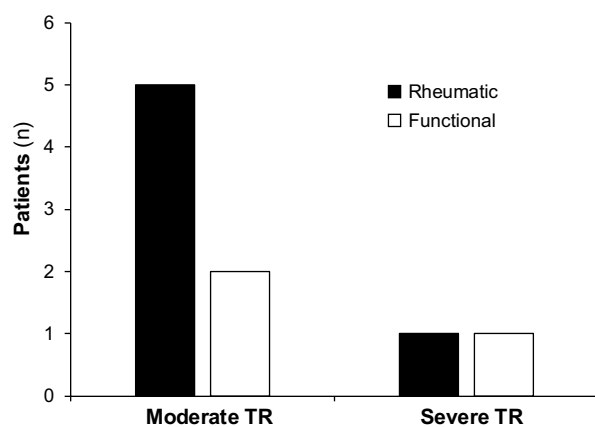
The recurrence rate of substantial tricuspid insufficiency after tricuspid annuloplasty ranges from 8% to 15% as early as one month after surgery.<sup>9,13</sup> Dreyfus

**TABLE V.** Results of Operation on Tricuspid Regurgitation Grade

TR Grade	Preoperative TTE (n=48)	Operative TEE (n=48)	TTE at Hospital Discharge (n=47)	Follow-Up TTE (n=47)
Absent or minimal	0	9 (18.8)	8 (17)	1 (2.1)
Mild	0	36 (75)	34 (72.3)	37 (78.7)
Moderate	17 (35.4)	3 (6.3)	5 (10.6)	7 (14.9)
Severe	31 (64.6)	0	0	2 (4.3)

TEE = transesophageal echocardiography; TR = tricuspid regurgitation; TTE = transthoracic echocardiography

Data are presented as number and percentage.



**Fig. 4** Graph shows grading of recurrent tricuspid regurgitation (TR) severity by means of transthoracic echocardiography in patients who had rheumatic and functional valvular disease during follow-up evaluation.

and colleagues<sup>14</sup> reported excellent outcomes, with only a 2% recurrence rate after tricuspid ring annuloplasty for functional TR. However, this series did not include patients with severe TR or severe leaflet tethering, in whom reported recurrence rates have ranged from 15% to 30%.<sup>9,15</sup> It has long been recognized that ring annuloplasty is unlikely to successfully treat severe leaflet tethering resulting in TR; several repair techniques have been suggested for these cases, including suture bicuspidization of the TV, and the clover technique.<sup>16,17</sup> Aoyagi and colleagues<sup>18</sup> reported a TR recurrence rate of 11.6%, a 10-year survival rate of 88.2%, and a freedom-from-reoperation rate of 97.6% after modified De Vega annuloplasty. However, when functional TR results from both severe annular dilation and leaflet tethering, annuloplasty alone is unlikely to be successful.<sup>8</sup> In these circumstances, several additional techniques have been proposed to achieve effective, durable repair. Augmentation of the anterior leaflet with autologous pericardium has been used in patients with substantial tethering, and different procedures have been combined with annuloplasty in the presence of prolapse or flail, including

chordae replacement, leaflet resection, chordal transposition, and papillary muscle reimplantation.<sup>19-23</sup>

During the past 10 years, e-PTFE sutures have been used to replace chordae tendineae, especially in patients with MV prolapse. Reports of artificial chordae tendineae implantation for the treatment of TR regurgitation are sparse. Marin and co-authors<sup>24</sup> reported the case of a 72-year-old woman in NYHA class III who underwent successful TV repair with implantation of artificial neochordae; her preoperative echocardiograms revealed severe TV regurgitation caused by prolapse of the anterior leaflet (A1–A2) and annular dilation. Artificial chordal implantation is also used in the repair of traumatic TR, which is associated with chordal disruption, rupture of the anterior papillary muscle, leaflet laceration, and leaflet retraction.<sup>19-21</sup> Tricuspid valve malformations such as papillary muscle elongation and congenital absence of the papillary muscle can also be treated by artificial chordae implantation. Ito and colleagues<sup>25</sup> reported the use of artificial chordae to repair isolated congenital TR in a 23-year-old woman. These reports have suggested that artificial chordal implantation is a viable technique for the surgical repair of TR.

To prevent TR recurrence, we use artificial neochordae implantation as an adjunctive procedure to ring or suture annuloplasty, neither of which has proved completely effective in achieving TR repair. Since 2009, we have used artificial chordae to treat TR resulting from annular dilation associated with prolapse or severe tethering of multiple leaflets. If leaflet tethering persists after annuloplasty, we resect the native chordae of the leaflet and replace them with longer artificial neochordae. Lapenna and associates<sup>26</sup> used the clover technique to manage multiple prolapse and flail of the tricuspid leaflets in the presence of traumatic or degenerative TR and severe leaflet tethering secondary to advanced RV remodeling. In that series, TR was absent or mild in 55 patients (88.7%), moderate in 6 (9.6%), and severe in one (1.6%).<sup>26</sup> In our institution, the size of the prosthetic ring is chosen on the basis of the surface area of the leaflet tissue attached to the chordae arising from the anterior papillary muscle. In our study, prolapse of the

anterior or posterior leaflet was observed in 9 patients whose functional TR resulted from the restriction of the tricuspid annular motion by the ring. Ten other patients with functional TR presented with prolapse of one or multiple TV leaflets after Kay annuloplasty. In these complex cases, we used artificial neochordae implantation as an adjunct to annuloplasty, to restore valvular competence and avoid post-repair leak and the need for valve replacement.

Surgical valve repair is now firmly established as the gold standard for valvular heart disease. Some researchers have analyzed the outcomes of surgical treatment for functional TV regurgitation, but reports on patients with organic TV disease predominate in the medical literature.<sup>15,27-29</sup> Surgical repair of rheumatic TV disease often fails because of severe anatomic distortion of the valve apparatus. The results of this procedure are less satisfactory than those of functional TV repair because, in patients with rheumatic TV disease, the durability of repair is compromised by the active and rapidly progressive nature of the disease process. Bernal and colleagues<sup>30</sup> reported that 38 patients (25.3%) with rheumatic valvular heart disease needed TV reoperations after mitral and TV repair. Tang and colleagues<sup>31</sup> obtained favorable outcomes of rheumatic TV repair with use of autologous pericardium; follow-up echocardiograms showed mild regurgitation in 8 patients (25.8%) and moderate regurgitation in one (3.2%). Among other modern techniques for repairing complex TV lesions is edge-to-edge valve plasty, which has been used as an effective adjunct procedure in patients with residual TR.<sup>32</sup> Because TV replacement is a high-risk procedure in patients with rheumatic heart disease<sup>33</sup> and is associated with high recurrence of TR, we chose to repair rheumatic TV by implanting artificial neochordae. This procedure was performed in 15 of our patients with rheumatic TV disease. Other techniques, including commissurotomy, leaflet mobilization, annuloplasty, and prosthetic ring implantation, were performed as needed. Primary chord resection was performed in those 15 patients in addition to secondary chord resection because of the thickened chordae. The consequent prolapse of the TV leaflets was corrected by implanting artificial neochordae. Follow-up echocardiograms showed no or mild TR in 9 of the 15 patients. Five patients had moderate TR and were treated medically. One patient had severe TR. Our results suggest that rheumatic pathology plays a role in determining the durability of TV repair.

Upon discharge from the hospital, only 5 of our surviving 47 patients had moderate TR; the remaining 42 had absent or minimal TR or mild TR. Follow-up TTE showed that TR was absent, minimal, or mild in 80.8% of patients. Seven patients (14.9%) had moderate TR, and 2 (4.3%) had severe TR. Our treatment approach might substantially increase the rate of successful repair in difficult cases, such as those described in our study.

However, careful intraoperative evaluation of the anatomic lesions underlying TR is necessary to decide if this technique can be applied with a reasonably high probability of success.

### Study Limitations

The major limitations of this study are its retrospective design, the small number of patients included, and the short follow-up periods in some cases.

### Conclusion

Our results indicate that neochordae implantation is a safe and durable technique in surgical repair of the TV, and that it leads to good outcomes in the management of TR. In carefully selected patients, organic rheumatic TV disease can be treated with neochordae implantation adjunctively with other techniques. Although the preliminary results of our approach are encouraging, additional data from studies with longer follow-up periods are necessary to confirm its effectiveness and to define its role as an alternative to TV replacement in selected patients.

### References

1. Waller BF, Howard J, Fess S. Pathology of tricuspid valve stenosis and pure tricuspid regurgitation--part II. *Clin Cardiol* 1995;18(3):167-74.
2. Cohen SR, Sell JE, McIntosh CL, Clark RE. Tricuspid regurgitation in patients with acquired, chronic, pure mitral regurgitation. II. Nonoperative management, tricuspid valve annuloplasty, and tricuspid valve replacement. *J Thorac Cardiovasc Surg* 1987;94(4):488-97.
3. Braunwald NS, Ross J, Morrow AG. Conservative management of tricuspid regurgitation in patients undergoing mitral valve replacement. *Circulation* 1967;35(4 Suppl):I63-9.
4. De Bonis M, Taramasso M, Lapenna E, Alfieri O. Management of tricuspid regurgitation. *F1000Prime Rep* 2014;6:58.
5. Matsuyama K, Matsumoto M, Sugita T, Nishizawa J, Tokuda Y, Matsuo T. Predictors of residual tricuspid regurgitation after mitral valve surgery. *Ann Thorac Surg* 2003;75(6):1826-8.
6. Raja SG, Dreyfus GD. Surgery for functional tricuspid regurgitation: current techniques, outcomes and emerging concepts. *Expert Rev Cardiovasc Ther* 2009;7(1):73-84.
7. Kay JH, Maselli-Campagna G, Tsuji KK. Surgical treatment of tricuspid insufficiency. *Ann Surg* 1965;162:53-8.
8. Fukuda S, Song JM, Gillinov AM, McCarthy PM, Daimon M, Kongsarepong V, et al. Tricuspid valve tethering predicts residual tricuspid regurgitation after tricuspid annuloplasty. *Circulation* 2005;111(8):975-9.
9. McCarthy PM, Bhudia SK, Rajeswaran J, Hoercher KJ, Lytle BW, Cosgrove DM, Blackstone EH. Tricuspid valve repair: durability and risk factors for failure. *J Thorac Cardiovasc Surg* 2004;127(3):674-85.
10. Kim HK, Kim YJ, Park JS, Kim KH, Kim KB, Ahn H, et al. Determinants of the severity of functional tricuspid regurgitation. *Am J Cardiol* 2006;98(2):236-42.
11. De Vega NG. Selective, adjustable and permanent annuloplasty. An original technic for the treatment of tricuspid insufficiency [in Spanish]. *Rev Esp Cardiol* 1972;25(6):555-6.

12. Carpentier A, Deloche A, Hanania G, Forman J, Sellier P, Piwnica A, et al. Surgical management of acquired tricuspid valve disease. *J Thorac Cardiovasc Surg* 1974;67(1):53-65.
13. Navia JL, Nowicki ER, Blackstone EH, Brozzi NA, Nento DE, Atik FA, et al. Surgical management of secondary tricuspid valve regurgitation: annulus, commissure, or leaflet procedure? *J Thorac Cardiovasc Surg* 2010;139(6):1473-82.e5.
14. Dreyfus GD, Corbi PJ, Chan KM, Bahrami T. Secondary tricuspid regurgitation or dilatation: which should be the criteria for surgical repair? *Ann Thorac Surg* 2005;79(1):127-32.
15. Tang GH, David TE, Singh SK, Maganti MD, Armstrong S, Borger MA. Tricuspid valve repair with an annuloplasty ring results in improved long-term outcomes. *Circulation* 2006;114(1 Suppl):I577-81.
16. De Bonis M, Lapenna E, La Canna G, Grimaldi A, Maisano F, Torracca L, et al. A novel technique for correction of severe tricuspid valve regurgitation due to complex lesions. *Eur J Cardiothorac Surg* 2004;25(5):760-5.
17. Ghanta RK, Chen R, Narayanasamy N, McGurk S, Lipsitz S, Chen FY, Cohn LH. Suture bicuspidization of the tricuspid valve versus ring annuloplasty for repair of functional tricuspid regurgitation: midterm results of 237 consecutive patients. *J Thorac Cardiovasc Surg* 2007;133(1):117-26.
18. Aoyagi S, Tanaka K, Hara H, Kumate M, Oryoji A, Yasunaga H, et al. Modified De Vega's annuloplasty for functional tricuspid regurgitation--early and late results. *Kurume Med J* 1992;39(1):23-32.
19. Maisano F, Lorusso R, Sandrelli L, Torracca L, Coletti G, La Canna G, Alfieri O. Valve repair for traumatic tricuspid regurgitation. *Eur J Cardiothorac Surg* 1996;10(10):867-73.
20. Hachiro Y, Sugimoto S, Takagi N, Osawa H, Morishita K, Abe T. Native valve salvage for post-traumatic tricuspid regurgitation. *J Heart Valve Dis* 2001;10(2):276-8.
21. van Son JA, Danielson GK, Schaff HV, Miller FA Jr. Traumatic tricuspid valve insufficiency. Experience in thirteen patients. *J Thorac Cardiovasc Surg* 1994;108(5):893-8.
22. Dreyfus GD, Raja SG, John Chan KM. Tricuspid leaflet augmentation to address severe tethering in functional tricuspid regurgitation. *Eur J Cardiothorac Surg* 2008;34(4):908-10.
23. Messika-Zeitoun, Thomson H, Bellamy M, Scott C, Tribouilloy C, Dearani J, et al. Medical and surgical outcome of tricuspid regurgitation caused by flail leaflets. *J Thorac Cardiovasc Surg* 2004;128(2):296-302.
24. Marin D, Ramadan K, Hamilton C, Schuetz A. Tricuspid valve repair with artificial chordae in a 72-year-old woman. *Thorac Cardiovasc Surg* 2011;59(8):495-7.
25. Ito T, Katogi T, Aeba R, Fujii H, Goto T, Kawada S. Surgical repair of isolated congenital tricuspid regurgitation with artificial chordae--a case of two year-follow up [in Japanese]. *Jpn J Thorac Cardiovasc Surg* 1998;46(12):1334-8.
26. Lapenna E, De Bonis M, Verzini A, La Canna G, Ferrara D, Calabrese MC, et al. The clover technique for the treatment of complex tricuspid valve insufficiency: midterm clinical and echocardiographic results in 66 patients. *Eur J Cardiothorac Surg* 2010;37(6):1297-303.
27. Grinda JM, Latremouille C, D'Atellis N, Berrebi A, Chauvaud S, Carpentier A, et al. Triple valve repair for young rheumatic patients. *Eur J Cardiothorac Surg* 2002;21(3):447-52.
28. Chaouch H, Kafsi N, Ben Ismail M. Indications and results of surgery of organic involvement of the tricuspid valve [in French]. *Arch Mal Coeur Vaiss* 1989;82(6):879-84.
29. Han QQ, Xu ZY, Zhang BR, Zou LJ, Hao JH, Huang SD. Primary triple valve surgery for advanced rheumatic heart disease in mainland China: a single-center experience with 871 clinical cases. *Eur J Cardiothorac Surg* 2007;31(5):845-50.
30. Bernal JM, Ponton A, Diaz B, Llorca J, Garcia I, Sarralde JA, et al. Combined mitral and tricuspid valve repair in rheumatic valve disease: fewer reoperations with prosthetic ring annuloplasty. *Circulation* 2010;121(17):1934-40.
31. Tang H, Xu Z, Zou L, Han L, Lu F, Lang X, Song Z. Valve repair with autologous pericardium for organic lesions in rheumatic tricuspid valve disease. *Ann Thorac Surg* 2009;87(3):726-30.
32. Lai YQ, Meng X, Bai T, Zhang C, Luo Y, Zhang ZG. Edge-to-edge tricuspid valve repair: an adjuvant technique for residual tricuspid regurgitation. *Ann Thorac Surg* 2006;81(6):2179-82.
33. Iscan ZH, Vural KM, Bahar I, Mavioglu L, Saritas A. What to expect after tricuspid valve replacement? Long-term results. *Eur J Cardiothorac Surg* 2007;32(2):296-300.