

# Preventing a Catastrophe:

## Increasing Awareness of Loeys-Dietz Syndrome

Bradley S. Kane, MD  
Kamran Shamsa, MD

*Loeys-Dietz syndrome is a genetic disorder that predisposes patients to aortic aneurysms. If left untreated, the natural history of the associated aortopathy often culminates in fatal aortic dissection. We describe the case of a 21-year-old man who was diagnosed with Loeys-Dietz syndrome after 2 family members died of aortic dissection. This case highlights the importance of increased physician awareness of this syndrome, which can play a crucial role in preventing premature sudden cardiac death caused by aortic catastrophe. (Tex Heart Inst J 2019;46(1):41-3)*

**L**oeys-Dietz syndrome is an autosomal dominant connective tissue disorder characterized by a triad of hypertelorism, cleft palate or bifid uvula (or both), and arterial disease that usually manifests itself as aortic aneurysms. Without intervention, the natural history of the disease is marked by the development of aggressive aneurysms, which often lead to fatal aortic dissection or rupture.<sup>1</sup> The estimated median age of survival of patients with this disorder is 26 years.<sup>2</sup>

We describe the case of a young patient who was diagnosed with Loeys-Dietz syndrome after 2 family members sustained fatal aortic dissections before age 60. A high degree of clinical suspicion of familial aortopathy is crucial in patients who have a family history of early-onset aortic dissection, because early diagnosis can prevent the often catastrophic sequelae of the disease.

### Case Report

**Key words:** Aneurysm, dissecting/genetics; aortic aneurysm, thoracic/genetics; genetic predisposition to disease; Loeys-Dietz syndrome/ diagnosis/genetics/pathology/therapy; practice guidelines as topic; receptors, transforming growth factor beta/genetics; risk factors

**From:** Department of Cardiology (Dr. Kane), Harbor-UCLA Medical Center, Torrance, California 90502; and Division of Cardiology (Dr. Shamsa), David Geffen School of Medicine at UCLA, Los Angeles, California 90095

**Address for reprints:**  
Bradley S. Kane, MD,  
Harbor-UCLA Medical  
Center, St. John's Cardio-  
vascular Research Center,  
Box 405, 1000 W. Carson,  
Torrance, CA 90502

**E-mail:** bkane1@  
dhs.lacounty.gov

© 2019 by the Texas Heart®  
Institute, Houston

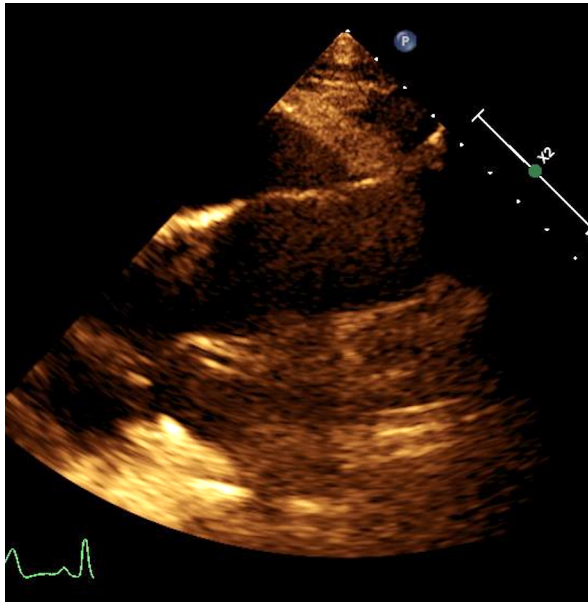
In 2015, a 21-year-old man presented at our cardiology clinic, shortly after his 59-year-old father died suddenly of an aortic dissection. Our patient had a medical history of pectus carinatum, acetabular fracture of the left posterior wall (at age 14 yr), posterolateral ligament tear in the left knee (at age 17 yr), and mild aortic root enlargement. His family history revealed that his paternal grandmother had died at 40 years of age. The cause of her death was presumed to be an aortic dissection.

At age 14, the patient visited a pediatrician for evaluation of pectus carinatum and hypermobility, and he was referred to a genetic counselor to confirm a suspected diagnosis of Marfan syndrome. The initial workup included echocardiographic and genetic testing for Marfan syndrome. Echocardiograms showed moderate aortic root enlargement (33–34 mm; Z score adjusted for body surface area, 1.9–2.2). Genetic test results revealed no mutations in the fibrillin-1 (*FBNI*) gene or any other known mutations. The patient received a diagnosis of unspecified connective tissue disorder and was instructed to have annual checkups with a pediatric cardiologist.

At age 18, the patient started seeing an adult cardiologist. His continued monitoring included annual echocardiography. The aortic root diameter eventually stabilized at 3.7 cm, the upper limit of normal (Fig. 1).

When the patient was 21 years old, his father was evaluated by a cardiologist after a primary care physician detected a heart murmur on auscultation. The initial echocardiogram revealed moderate aortic root dilation (4 cm) and moderate aortic regurgitation. Aggressive blood pressure control and close monitoring were recommended. Three months later, the father presented at another hospital with chest pain and left hemiplegia. He was diagnosed with type A aortic dissection involving all the major branching arteries, from the aortic root past the celiac trunk, as well as a massive right middle cerebral artery stroke. He died shortly thereafter.

Because 2 family members had died of acute aortic dissection, we referred our patient to a genetic counselor for extensive testing. Subsequent screening revealed a mutation in the mothers against decapentaplegic homolog 3 (*SMAD3*) gene (exon 9, nucleotide c8039>a, Arg268His). This mutation was in a highly conserved region of the gene



**Fig. 1** Transthoracic echocardiogram shows mild aortic root dilation (3.7 cm) and effacement of the sinotubular junction.

and had previously been implicated in several cases of aortic aneurysms associated with Loeys-Dietz syndrome type 3.<sup>2</sup> The patient was prescribed  $\beta$ -blockers and angiotensin receptor blockers (ARBs) for aggressive blood pressure control and was counseled about activity restrictions. He was also advised to undergo aortic root imaging twice a year.

## Discussion

Loeys-Dietz syndrome is among a group of aggressive heritable aortopathies that also include Marfan syndrome and familial thoracic aortic aneurysm.<sup>3</sup> The mutations in Loeys-Dietz syndrome seem to be linked to genetic variations that cause an upregulation of transforming growth factor- $\beta$  (TGF- $\beta$ ), which can result in increased aortic dilation.<sup>2</sup>

In our patient's case, the mutation involved the *SMAD3* gene, which encodes a transcriptional regulator in the TGF- $\beta$  signaling pathway. This missense mutation, which causes an amino acid substitution (arginine to histidine), occurs in a highly conserved region of the gene and has been associated with early-onset aortic dissection.<sup>4</sup> When the patient was 14 years old, clinical suspicion of Marfan syndrome prompted genetic testing targeting mutations in the *FBNI* gene, but none were identified. However, additional diagnostic tests, including echocardiography, revealed mild aortic root dilation (Z score, 1.9–2.2). The positive family history of early-onset aortic dissection increased clinical suspicion of a genetic aortopathy syndrome, prompting the treating physician to recommend annual echocardiography. When the patient first underwent genetic

testing, multigene panels that now screen for mutations in a variety of genes known to be associated with familial aortic aneurysms did not yet exist.<sup>4,5</sup>

After his father died of a massive type A aortic dissection, our patient underwent further genetic testing for heritable aortopathy by use of the aortopathy panel. This revealed the mutation in the *SMAD3* gene, leading to the diagnosis of Loeys-Dietz syndrome type 3.<sup>4</sup> According to the clinical guidelines established by the American College of Medical Genetics and Genomics in 2015,<sup>6</sup> the combination of any genetic mutation in one of the 4 currently known affiliated genes (TGF- $\beta$  receptors 1 [*TGF $\beta$ R1*] and 2 [*TGF $\beta$ R2*], *SMAD3*, and *TGF $\beta$ B2*) and a known aortic aneurysm or dissection or a positive family history of early-onset aortic dissection is sufficient to establish the diagnosis of Loeys-Dietz syndrome.

In 2010, the American College of Cardiology (ACC) and the American Heart Association (AHA), in conjunction with several surgical societies, published guidelines for the management of patients with thoracic aortic disease,<sup>7</sup> including recommendations for patients with genetic syndromes associated with aortic aneurysms. Therapy for patients who have confirmed Loeys-Dietz syndrome includes strict control of blood pressure with  $\beta$ -blockers, ARBs, or both. Use of these agents for blood pressure control is preferred, because they are thought to slow the progression of adverse aortic remodeling. Mouse models, as well as the translation of their results to human studies, have pointed to the significant potential benefit of the blockade of angiotensin receptors in the TGF- $\beta$  signaling pathway. The guidelines<sup>7</sup> also recommend that patients with Loeys-Dietz syndrome undergo at least yearly screening of the aortic root by transthoracic echocardiography or other imaging methods. In addition, the ACC and AHA recommend magnetic resonance angiography of the head, neck, chest, abdomen, and pelvis, because arterial aneurysms have also been known to occur outside the aortic tree.<sup>7</sup>

There is an important distinction between Marfan syndrome and Loeys-Dietz syndrome. In Loeys-Dietz syndrome, fatal aortic dissection and rupture can occur at diameters of 4 cm, whereas in Marfan syndrome rupture is not typically seen until the aortic root diameter approaches 5 cm.<sup>8</sup> Patients with Loeys-Dietz syndrome should undergo early surgical consultation, because they may benefit from prophylactic surgery.

In addition to aortic root diameter, other echocardiographic variables have proved helpful in evaluating the severity of aortic involvement in Loeys-Dietz syndrome. Researchers have examined segmental aortic elasticity, including distensibility, strain, and stiffness, which may be associated with higher rates of progression to rupture or dissection.<sup>8</sup> However, additional studies are necessary to clarify their role. Finally, collaboration with cardiothoracic surgeons is crucial because early intervention

is often necessary in these patients. In a retrospective study,<sup>9</sup> 79 patients (mean age, 25 yr) underwent surgery for the repair or replacement of the aortic root, arch, or both. The rate of surgical success was high, but the group had a significant rate of reintervention at 10 years (nearly 25%). The mean 10-year survival rate of the patients undergoing surgery was 88%.<sup>9</sup> Additional studies are needed to determine the optimal timing of surgical treatment for these patients.

## Conclusion

Loeys-Dietz syndrome is an autosomal dominant genetic disorder associated with aortic aneurysms that become life-threatening if not recognized and treated early. A family history of early-onset aortic dissection should generate strong clinical suspicion of familial aortopathy, and patients should be referred for genetic testing and monitored closely, especially because de novo mutations can arise. Aggressive blood pressure control with  $\beta$ -blockers and ARBs is indicated in patients with Loeys-Dietz syndrome, and they may also benefit from prophylactic aortic surgery. Further studies are warranted to determine the optimal timing of surgical intervention (for example, when the aortic diameter threshold approaches 4 cm).

## References

1. Van Hemelrijk C, Renard M, Loeys B. The Loeys-Dietz syndrome: an update for the clinician. *Curr Opin Cardiol* 2010; 25(6):546-51.
2. Loeys BL, Schwarze U, Holm T, Callewaert BL, Thomas GH, Pannu H, et al. Aneurysm syndromes caused by mutations in the TGF-beta receptor. *N Engl J Med* 2006;355(8):788-98.
3. Paterick TE, Humphries JA, Ammar KA, Jan MF, Loberg R, Bush M, et al. Aortopathies: etiologies, genetics, differential diagnosis, prognosis, and management. *Am J Med* 2013;126(8):670-8.
4. MacCarrick G, Black JH 3rd, Bowdin S, El-Hamamsy I, Frischmeyer-Guerrero PA, Guerrero AL, et al. Loeys-Dietz syndrome: a primer for diagnosis and management. *Genet Med* 2014;16(8):576-87.
5. Zentner D, West M, Ades LC; CSANZ Cardiovascular Genetic Diseases Council. Update on the diagnosis and management of inherited aortopathies, including Marfan syndrome. *Heart Lung Circ* 2017;26(6):536-44.
6. Richards S, Aziz N, Bale S, Bick D, Das S, Gastier-Foster J, et al. Standards and guidelines for the interpretation of sequence variants: a joint consensus recommendation of the American College of Medical Genetics and Genomics and the Association for Molecular Pathology. *Genet Med* 2015;17(5):405-24.
7. Hiratzka LF, Bakris GL, Beckman JA, Bersin RM, Carr VF, Casey DE Jr, et al. 2010 ACCF/AHA/AATS/ACR/ASA/SCA/SCAI/SIR/STS/SVM guidelines for the diagnosis and management of patients with thoracic aortic disease: a report of the American College of Cardiology Foundation/American Heart Association Task Force on Practice Guidelines, American Association for Thoracic Surgery, American College of Radiology, American Stroke Association, Society of Cardiovascular Anesthesiologists, Society for Cardiovascular Angiography and Interventions, Society of Interventional Radiology, Society of Thoracic Surgeons, and Society for Vascular Medicine. *Circulation* 2010;121(13):e266-369.
8. Akazawa Y, Motoki N, Tada A, Yamazaki S, Hachiya A, Matsuzaki S, et al. Decreased aortic elasticity in children with Marfan syndrome or Loeys-Dietz syndrome. *Circ J* 2016;80(11):2369-75.
9. Patel ND, Crawford T, Magruder JT, Alejo DE, Hibino N, Black J, et al. Cardiovascular operations for Loeys-Dietz syndrome: intermediate-term results. *J Thorac Cardiovasc Surg* 2017;153(2):406-12.