

Surgical Repair of a 13-cm Infrarenal Abdominal Aortic Aneurysm

with Aortocaval Fistula in a 63-Year-Old Tuba Player

Macit Bitargil, MD
Nilufer Bektas, MD
Sinan Omeroglu, MD
Ismail Koramaz, MD

Infrarenal abdominal aortic aneurysm with aortocaval fistula, a rare condition, can be fatal without prompt intervention. The clinical symptoms are complex and varied, so diagnosis is typically confirmed by use of contrast-enhanced multidetector computed tomography. We report our surgical repair of a 13-cm-diameter infrarenal abdominal aortic aneurysm and aortocaval fistula in a 63-year-old orchestral tuba player who had 2 classic symptoms of the condition. The unruptured aneurysm and fistula were complicated by acutely angled vessels, so we performed surgery rather than endovascular repair. The patient recovered fully and was discharged from the hospital. This infrarenal aneurysm with aortocaval fistula is perhaps the largest to have been treated successfully by means of open surgery. In addition to our patient's case, we discuss the history and treatment considerations of this rare combined condition. (Tex Heart Inst J 2019;46(1):36-40)

Key words: Aneurysm, ruptured/diagnostic imaging/etiology/mortality/surgery/therapy; aortic aneurysm, abdominal/complications/diagnosis/surgery; arteriovenous fistula/diagnosis/etiology/surgery; endovascular procedures/adverse effects; time factors; treatment outcome; Valsalva maneuver/physiology; vascular surgical procedures; vena cava, inferior/surgery

From: Departments of Cardiovascular Surgery (Drs. Bektas, Bitargil, and Koramaz) and General Surgery (Dr. Omeroglu), Sisli Hamidiye Etfal Research and Training Hospital, 34371 Sisli, Istanbul, Turkey

Address for reprints: Macit Bitargil, MD, Sisli Hamidiye Etfal Egitim ve Arastirma Hastanesi, Halaskargazi Cad. Etfal Sk., 34371 Sisli, Istanbul, Turkey

E-mail: mctbtr@hotmail.com

© 2019 by the Texas Heart® Institute, Houston

More than 15,000 people die each year of ruptured abdominal aortic aneurysm (AAA); in 2013, the Centers for Disease Control ranked it the 15th leading cause of death in the United States in adults 60 to 64 years of age.¹ In ultrasonographic studies of men 65 to 80 years old, the prevalence of AAA is 4% to 8%; in women, the prevalence is 4 to 6 times lower.² The estimated annual pre-hospitalization mortality rate is 59% to 83%, and that upon presentation for medical care, 30% to 80%.³

The risk of AAA rupture increases with aneurysmal diameter^{2,4}; typically, diameters ≥ 6 cm warrant intervention.⁵ In one study, the relative risk of rupture of an AAA ≥ 8 cm in diameter was 31.3 (95% CI, 11.1–88.4).⁵ Most AAAs rupture into the retroperitoneum or peritoneum.⁶ Rupture of an AAA into the inferior vena cava (IVC) is unusual, and the spontaneous development of an aortocaval fistula (ACF), with or without AAA rupture, is rarer still. More than 80% of reported ACFs have been associated with ruptured AAA.⁷ Endovascular intervention has had good early results; nevertheless, surgery remains the cornerstone of treatment.^{3,7}

We report the case of a 63-year-old man who presented with a giant infrarenal AAA complicated by an ACF. In addition, we discuss the combined condition's history and its treatment considerations.

Case Report

In December 2016, a 63-year-old man, a long-time orchestral tuba player, presented at our emergency department with a 12-hour history of abdominal pain. His blood pressure was 90/50 mmHg, and his heart rate was 110 beats/min. Physical examination revealed a pulsatile abdominal mass in the right abdominal wall. Emergency contrast-enhanced computed tomographic angiograms (CTA) confirmed the diagnosis of a giant infrarenal AAA with an ACF (Fig. 1). The 13-cm AAA extended distally to both common iliac arteries. We observed simultaneous filling of the abdominal aorta and IVC, with no signs of retroperitoneal rupture. Acute vascular angulation precluded endovascular intervention (Fig. 2), so the patient was taken for surgery.

After performing a midline laparotomy, we achieved control of the supraceliac abdominal aorta without cross-clamping, controlled the infrarenal aorta and iliac arteries, and exposed the AAA (Fig. 3). We infused systemic heparin intravenously, then cross-clamped the infrarenal aorta and iliac arteries. When we opened the aorta, a large

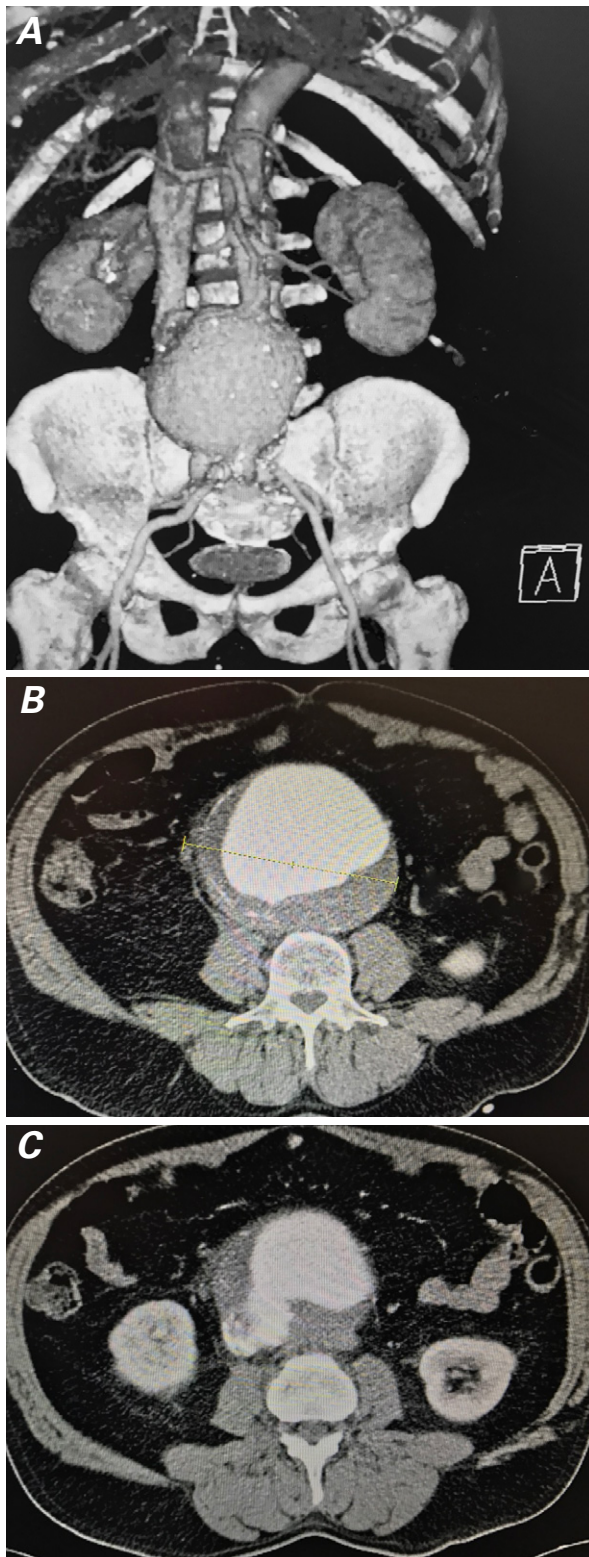


Fig. 1 Preoperative abdominal computed tomographic angiograms. **A)** The coronal view (3-dimensional reconstruction) shows a 13-cm abdominal aortic aneurysm with communication and synchronous filling of contrast medium between the aorta and inferior vena cava. Transverse views show **B)** the aneurysm and no evidence of retroperitoneal rupture, and **C)** the aortocaval fistula.

volume of venous blood flowed from the aneurysmal sac. We controlled it by inserting 2 occlusive balloons (volume capacities, 15–30 cc), using a 16F Foley catheter. Autotransfusion was not used. From within the aneurysmal sac, we oversewed a 40 × 15-mm aortocaval communication between the infrarenal aorta and IVC, then ligated both common iliac arteries and the small lumbar arteries. For aortofemoral bypass, we placed an 8-mm Dacron graft to each lower extremity, thus restoring blood flow. The patient was given 3 units of packed red blood cells during the operation.

The patient was extubated on the second postoperative day and stayed 4 days in the intensive care unit, where he was given one unit of packed red blood cells. Postoperative CTA revealed no vascular complications (Fig. 4). On postoperative day 5, he had fever, leukocytosis, and a purulent discharge from the abdominal incision. General surgeons performed an exploratory laparotomy, observed sigmoid colon perforation, and used the Hartmann procedure to repair it.

The patient had no pulmonary or renal insufficiency and only minimal leg edema when he was discharged from the hospital after a 15-day stay. At his 3- and 6-month follow-up examinations, he was doing well.

Discussion

Syme is credited as being the first to describe ACF (in 1831),⁸ and Viar and Lombardo reported the first detailed modern case (1952).⁹ In 1955, in response to Javid and colleagues' case series,¹⁰ Cooley noted his own case¹¹ of a poor surgical candidate who recovered after an operation to correct a ruptured AAA with ACF—apparently the first successful repair.

The signs and symptoms of AAA with ACF are varied, often nonspecific, and often associated with unrelated conditions. A pulsatile abdominal mass, abdominal and low-back pain, and an abdominal machinery-like bruit are most typical; other possible symptoms are severe dyspnea, lower-extremity or scrotal edema, ascites, hepatomegaly and liver congestion caused by venous hypertension, and hematuria, oliguria, and renal failure consequent to venous hypertension and decreased median arterial pressure.¹² Our patient had abdominal pain, a pulsatile abdominal mass, and leg edema. Results of contrast-enhanced multidetector CTA confirmed the diagnosis.¹²

Rapid intervention is crucial after diagnosis of ACF.¹⁰ A wrong or clinically missed diagnosis contributes to poor operative outcomes, especially in the typical elderly patient who may already be under hemodynamic stress.¹³ Open surgery and endovascular repair are the treatment options. Supraceliac control of the aorta via an elastic loop is essential for controlling excessive bleeding, especially in an aneurysm that has a short proximal

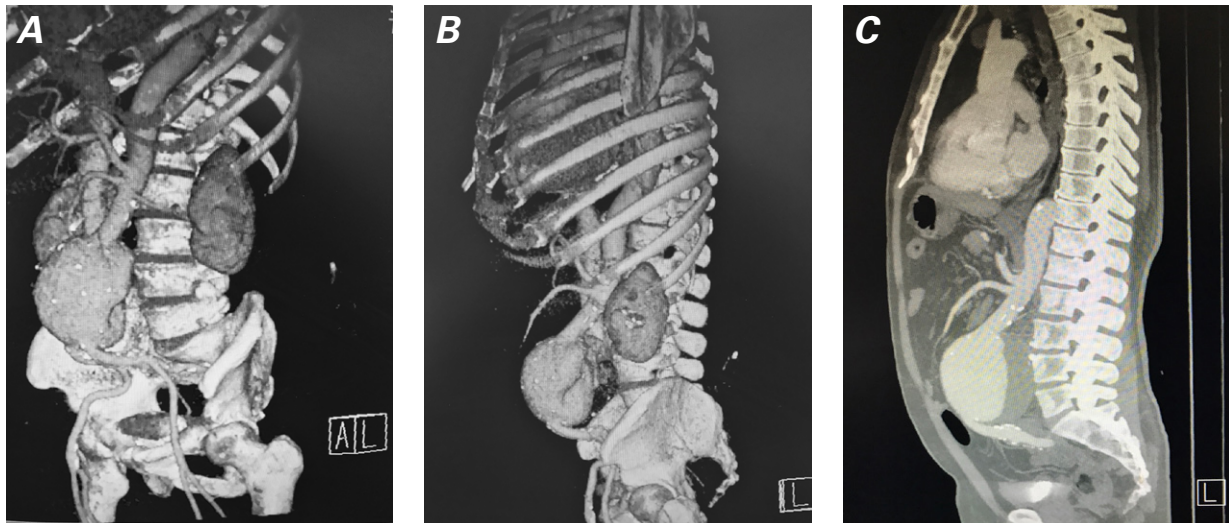


Fig. 2 Preoperative abdominal computed tomographic angiograms in **A)** anterolateral and **B)** sagittal views show acute angulation between the aorta and common iliac arteries. **C)** The sagittal view shows acute angulation between the aorta and common iliac arteries.

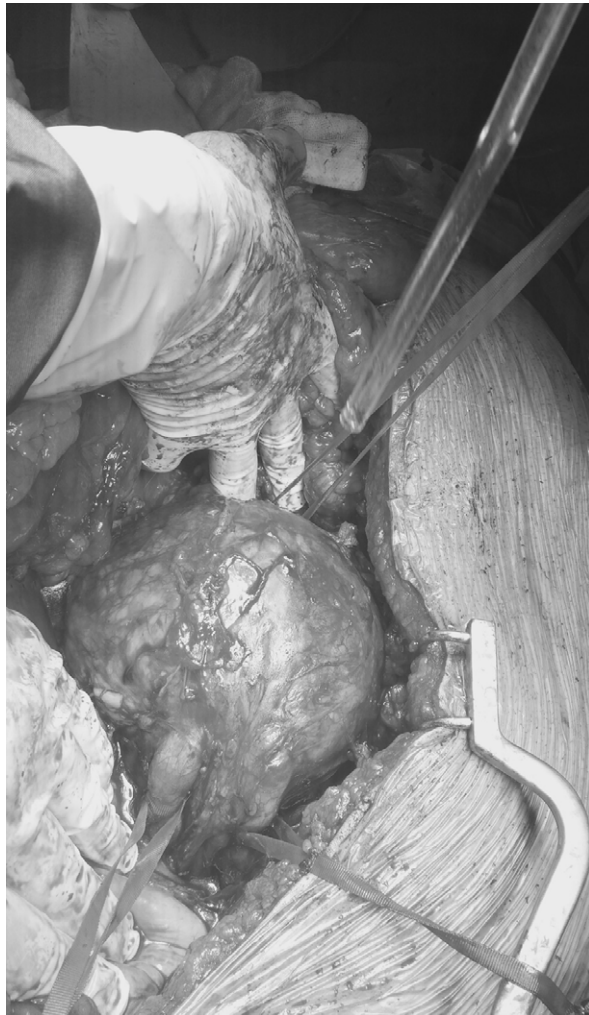

Fig. 3 Intraoperative photograph shows the infrarenal aortic aneurysm.

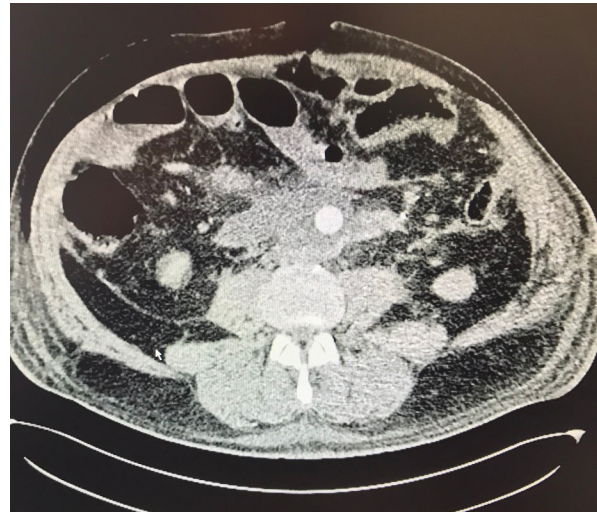

Fig. 4 Postoperative computed tomographic angiogram (transverse view) of the infrarenal aorta shows no vascular complications.

infrarenal neck.¹⁴ Although the aneurysmal neck in our patient was long, the position of the AAA necessitated our gaining control of the supraceliac aorta. To protect the kidneys from ischemia, cross-clamping the supraceliac aorta is not recommended unless there is uncontrolled hemorrhage. Profuse venous bleeding from the opened aorta can be controlled by compressing the IVC or by using occlusive balloons.¹⁵ Alternatively, hemostasis can be achieved by ligating the infrarenal IVC, iliac veins, or both.¹⁶

Endovascular treatment of AAA has been associated with shorter hospital stays and favorable early survival rates. Despite the technical success of endovascular re-

pair, complications such as endoleak can affect long-term outcomes.¹⁷ Type II endoleak, more prevalent than the other types, is often caused by unwanted retrograde filling of the sac; it can resolve spontaneously or can worsen after the initial endovascular treatment.¹⁸ In one analysis,¹⁹ endoleaks occurred in 13 of 26 patients after endovascular ACF repair and spontaneously resolved in 6 instances. The arteriovenous circuit that occurs in ACF may aggravate endoleak patency and in turn cause congestive heart failure, thrombosis, disseminated intravascular coagulation, ACF patency, and further expansion of the sac.¹⁹ For these reasons, some operators treat type II endoleak immediately after its diagnosis in association with ACF. We decided to perform surgery in our patient because of acute vascular angulations—almost 90° between the aorta, iliac arteries, and femoral arteries, and 45° to 60° in the aortic neck. In addition, the patient's situation was urgent, and we did not have a hybrid operating room.

A notable factor in our patient's case was his profession. He had played tuba in an orchestra 8 hours daily for 30 years. The expiratory efforts necessary to play wind and brass instruments often replicate the Valsalva maneuver.²⁰ We found no association in the medical literature between tuba-playing and development of a giant AAA with ACF, and we claim none. However, blowing notes on a tuba reproduces cardiovascular changes observed during Valsalva maneuvers; producing loud or sustained notes at high pitches equates with a classic (40-mmHg) Valsalva maneuver.²⁰ Diaphragmatic movement while playing low notes results in a low resistance to expiration, whereas high notes necessitate strenuous or strained expiration. In the latter, high intrathoracic pressure can reproduce Valsalva effects that would change blood pressure, heart rate, stroke volume, and peripheral vascular resistance.²⁰ Furthermore, in the mechanism of ACF, the decreased peripheral resistance and diastolic hypotension cause a sharp increase in cardiac output that can rapidly lead to left ventricular high-output decompensated cardiac failure, particularly in patients who have underlying heart disease.⁶ Without further investigation, it is unclear whether our patient should continue to play the tuba, or if any wind or brass instrumentalist should continue to play, in the presence of an existing or repaired AAA.

Reviewers¹⁹ documented only 40 PubMed-listed articles about AAA with ACF from 1999 through 2014, involving 67 patients, 41 surgeries, and 26 endovascular repairs. Our supplemental search (1999–2017) disclosed a few more reports of giant AAA (≥ 13 cm) with ACF; however, those patients died before, during, or days after surgery. We found no AAAs >13 cm associated with ACF.^{14,21} Accordingly, our patient survived perhaps the largest unruptured infrarenal AAA with ACF to have been treated surgically.

References

- Centers for Disease Control. Deaths, percent of total deaths, and death rates for the 15 leading causes of death in 5-year age groups, by race and sex: United States, 2013. Available from: www.cdc.gov/nchs/data/dvs/LCWK1_2013.pdf [cited 2016 Jan 29].
- Chaikof EL, Brewster DC, Dalman RL, Makaroun MS, Illig KA, Sicard GA, et al. The care of patients with an abdominal aortic aneurysm: the Society for Vascular Surgery practice guidelines. *J Vasc Surg* 2009;50(4 Suppl):S2-49.
- Livesay JJ, Talledo OG. Endovascular aneurysm repair is not the treatment of choice in most patients with ruptured abdominal aortic aneurysm. *Tex Heart Inst J* 2013;40(5):556-9.
- Moll FL, Powell JT, Fraedrich G, Verzini F, Haulon S, Waltham M, et al. Management of abdominal aortic aneurysms clinical practice guidelines of the European Society for Vascular Surgery. *Eur J Vasc Endovasc Surg* 2011;41 Suppl 1:S1-S58.
- Brown PM, Zelt DT, Sobolev B. The risk of rupture in untreated aneurysms: the impact of size, gender, and expansion rate. *J Vasc Surg* 2003;37(2):280-4.
- Kotsikoris I, Pappas TT, Papanas N, Maras D, Andrikopoulou M, Bessias N, et al. Aortocaval fistula formation due to ruptured abdominal aortic aneurysms: a 12-year series. *Vasc Endovascular Surg* 2012;46(1):26-9.
- Psathas ED, Lioudaki S, Doulaptis M, Charalampoudis P, Klonaris C, Verikokos C. Clinical manifestations of aortocaval fistulas in ruptured abdominal aortic aneurysm: report of two cases. *Case Rep Surg* 2012;2012:123081.
- Syme J. Case of spontaneous varicose aneurism. *Edinb Med Surg J* 1831;38(108):104-5. Available from: <https://www.ncbi.nlm.nih.gov/pmc/articles/PMC5760152/>.
- Viar WN, Lombardo TA. Abdominal aortic aneurysm with rupture into the inferior vena cava. *Circulation* 1952;5(2):287-9. Available from: <https://www.ahajournals.org/doi/pdf/10.1161/01.CIR.5.2.287>.
- Javid H, Dye WS, Grove WL, Julian OC. Resection of ruptured aneurysms of the abdominal aorta. *Ann Surg* 1955;142(4):613-21. Available from: <https://www.ncbi.nlm.nih.gov/pmc/articles/PMC1465188/pdf/annsurg01283-0077.pdf>.
- Cooley DA (in Discussion). Javid H, Dye WS, Grove WL, Julian OC. Resection of ruptured aneurysms of the abdominal aorta. *Ann Surg* 1955;142(4):613-21; discussion 621-3. Available from: <https://www.ncbi.nlm.nih.gov/pmc/articles/PMC1465212/> [p. 623].
- Tonolini M, Ippolito S, Rigioli F. Images in medicine: spontaneous aortocaval fistula complicating abdominal aortic aneurysm. *J Emerg Trauma Shock* 2014;7(2):129-30.
- Akwei S, Altaf N, Tennant W, MacSweeney S, Braithwaite B. Emergency endovascular repair of aortocaval fistula—a single center experience. *Vasc Endovascular Surg* 2011;45(5):442-6.
- Maras D, Lioupis C, Moulakakis KG, Sfyroeras G, Pavlidis P, Bountouris I, et al. Giant abdominal aortic aneurysms: clinical and technical considerations. *Acta Chir Belg* 2009;109(3):376-80.
- Gyoten T, Doi T, Yamashita A, Fukahara K, Kotoh K, Yoshimura N. Surgical repair of large aortocaval fistula with limited shunt: case report. *SAGE Open Med Case Rep* 2014;10:2:2050313X14550701. Available from: <https://www.ncbi.nlm.nih.gov/pmc/articles/PMC4857367/>.
- Tsolakis JA, Papadoulas S, Kakkos SK, Skroubis G, Siablis D, Androulakis JA. Aortocaval fistula in ruptured aneurysms [published erratum appears in *Eur J Vasc Endovasc Surg* 1999;17(6):554]. *Eur J Vasc Endovasc Surg* 1999;17(5):390-3.

17. Brown A, Saggu GK, Bown MJ, Sayers RD, Sidloff DA. Type II endoleaks: challenges and solutions. *Vasc Health Risk Manag* 2016;12:53-63.
18. Silverberg D, Baril DT, Ellozy SH, Carroccio A, Greyrose SE, Lookstein RA, Marin ML. An 8-year experience with type II endoleaks: natural history suggests selective intervention is a safe approach. *J Vasc Surg* 2006;44(3):453-9.
19. Orion KC, Beaulieu RJ, Black JH 3rd. Aortocaval fistula: is endovascular repair the preferred solution? *Ann Vasc Surg* 2016;31:221-8.
20. Elghozi JL, Girard A, Fritsch P, Laude D, Petitprez JL. Tuba players reproduce a Valsalva maneuver while playing high notes. *Clin Auton Res* 2008;18(2):96-104.
21. Penugonda LC, Saththasivam P, Green MS. A successful repair of a giant abdominal aortic aneurism. *Anesth Pain Med* 2016;6(3):e34847. Available from: <https://www.ncbi.nlm.nih.gov/pmc/articles/PMC5018132/>.