

# Carcinoid Heart Disease: Review of Current Knowledge

Pradhun Ram, MD  
 Jorge L. Penalver, MD  
 Kevin Bryan U. Lo, MD  
 Janani Rangaswami, MD  
 Gregg S. Pressman, MD

*Carcinoid heart disease is the collective term for all cardiac manifestations in patients who have carcinoid syndrome. Carcinoid heart disease has a multifactorial pathophysiology, and the right side of the heart is usually involved. Symptoms and signs vary depending upon the affected cardiac components; most typical is right-sided heart failure secondary to diseased tricuspid and pulmonary valves. Despite no single ideal diagnostic test, strong suspicion, coupled with serologic and imaging results, usually enables diagnosis. Advances in imaging, such as speckle-tracking echocardiography and cardiac magnetic resonance, have improved the diagnostic yield. Treatment is challenging, warrants a multidisciplinary approach, and can be medical or surgical depending on the cardiac manifestations. Investigators are exploring the therapeutic use of monoclonal antibodies and new somatostatin analogues. In this review, we cover current knowledge about the pathophysiology, diagnosis, and treatment of carcinoid heart disease. (Tex Heart Inst J 2019;46(1):21-7)*

**Key words:** Biomarkers/blood; carcinoid heart disease/blood/diagnostic imaging/physiopathology/therapy/urine; carcinoid tumor/complications/diagnosis/epidemiology/mortality/pathology/surgery; disease progression; heart valve diseases/complications; malignant carcinoid syndrome/pathology; neuroendocrine tumors/pathology; pulmonary valve insufficiency/etiology; serotonin/metabolism; tricuspid valve insufficiency/etiology

**From:** Department of Internal Medicine (Drs. Lo, Penalver, Ram, and Rangaswami) and Division of Cardiology, Heart and Vascular Institute (Dr. Pressman), Einstein Medical Center, Philadelphia, Pennsylvania 19141

**Address for reprints:**  
 Pradhun Ram, MD, Suite 363, Klein Bldg., Einstein Medical Center, 5501 Old York Rd., Philadelphia, PA 19141

**E-mail:**  
 rampradhun@gmail.com

© 2019 by the Texas Heart<sup>®</sup> Institute, Houston

**C**arcinoid tumors are neuroendocrine neoplasms that typically arise from the gastrointestinal tract and bronchopulmonary system. Approximately 2 in 100,000 people are affected annually.<sup>1-3</sup> Carcinoid tumors, which are typically indolent, secrete myriad vasoactive substances, serotonin chief among them.<sup>4</sup> Patients are often asymptomatic until these tumors metastasize to the liver, which cannot then inactivate the vasoactive substances. Rarely, ovarian and retroperitoneal metastasis occurs when the vasoactive substances bypass the liver and enter the systemic circulation through the caval system, a process that causes the classic symptoms of flushing and diarrhea.<sup>5-8</sup>

Carcinoid tumors involve the heart in up to 60% of patients.<sup>9,10</sup> Cardiac involvement is associated with a poor long-term prognosis: the estimated 3-year survival rate of 31% is half that of patients without cardiac involvement.<sup>11-13</sup>

In this review, we discuss current knowledge about cardiac carcinoid tumors.

## Pathophysiology

Carcinoid heart disease (HD) occurs when large amounts of vasoactive substances such as serotonin, tachykinins, and prostaglandins reach the right side of the heart, consequent to reduced hepatic metabolism from extensive metastatic liver involvement of the carcinoid tumor.<sup>13</sup> Generally, the left side of the heart is spared because the lungs metabolize the vasoactive substances; the rare exceptions are associated with patent foramen ovale and primary bronchopulmonary carcinoid disease.<sup>10,14,15</sup>

In cardiac involvement, the carcinoid tumor releases the vasoactive substances, as well as transforming growth factor- $\beta$ . After the initial endocardial injury, plaque is deposited at the endocardial surfaces of the right-sided heart valves, papillary muscles, and chordae tendineae. The plaque, composed of fibroblasts, smooth muscle cells, and extracellular matrix,<sup>6,12,16</sup> is usually found downstream, at the ventricular aspect of the tricuspid valve (TV) and the pulmonary arterial side of the pulmonic valve (PV).<sup>5</sup> Fibrosis may be induced by serotonin, evidenced by high levels of serotonin metabolites found in the urine of patients with carcinoid heart involvement, in addition to serotonin receptors in their cardiac valves.<sup>17-19</sup> Moreover, serotonergic drugs and fenfluramine (a weight-loss medication that targets serotonin receptors) have caused valvular changes similar to those associated with carcinoid HD.<sup>20,21</sup> Conversely, some patients seemingly do not benefit from lower serotonin levels and experience progressive carcinoid HD.<sup>22</sup> This observation suggests the important role that other vasoactive chemical mediators play in the disease progression.

## Manifestations

The presentation of cardiac carcinoid HD (also called Hedinger syndrome<sup>23</sup>) is usually insidious and subtle.<sup>24</sup> Most patients are initially asymptomatic, and clinical features appear along with right-sided heart involvement (Fig. 1).<sup>6,25</sup>

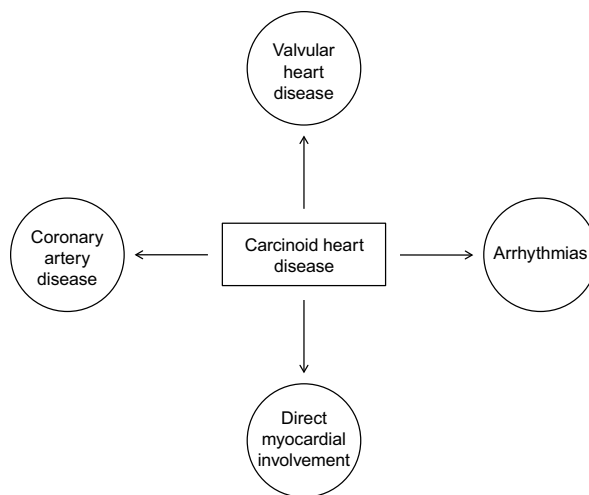
**Valvular Heart Disease.** In carcinoid HD, valvular involvement—specifically isolated TV regurgitation—is seen most often. In one series, all patients with carcinoid HD had TV regurgitation on echocardiograms; the valve leaflets were thickened, shortened, and retracted, with incomplete coaptation.<sup>10</sup> In most patients, the leaflets were also fixed in a half-open position, which led to TV stenosis.<sup>10</sup> Up to 80% of patients have had PV regurgitation or stenosis.<sup>10,13,26</sup> These structural and valvular lesions eventually lead to right-sided heart failure with symptoms such as lower-extremity edema and early satiety.<sup>12,26</sup> New York Heart Association functional class III/IV symptoms and right ventricular (RV) dysfunction were important predictors of outcome in these patients.<sup>12</sup>

**Coronary Artery Involvement.** Coronary artery vasospasm is also associated with carcinoid HD,<sup>27,28</sup> usually in patients who have nonocclusive coronary artery disease.<sup>27-29</sup> Depending on endothelial conditions, serotonin can stimulate vasodilatory or constrictive responses. Serotonin can cause vasoconstriction in diseased endothelium (such as in patients with atherosclerotic disease) because of the predominance of vasoconstriction-provoking 5-hydroxytryptamine<sub>2</sub> (5-HT<sub>2</sub>) receptors and the loss of 5-HT<sub>1</sub> receptors that mediate vasodilation. This response explains the finding of carcinoid-induced coronary vasospasm in patients who have nonocclusive coronary disease.<sup>28-33</sup>

In addition, serotonin sometimes reaches the coronary circulation by means of shunting through a patent foramen ovale; as a known platelet activator, it might also contribute to stent thrombosis.<sup>29,34</sup> Possible coronary vasospasm should be considered when patients present with acute coronary syndrome and a history of carcinoid disease. Therapeutic decisions include whether to use vasodilators such as calcium channel blockers, serotonin antagonists, or somatostatin analogues.<sup>27</sup>

**Arrhythmias.** Arrhythmias have rarely been reported in the presence of carcinoid HD. In a patient without ischemic HD, carcinoid-induced ventricular tachycardia was controlled with the use of metoprolol<sup>35</sup>; 2 other cases involved associated atrial arrhythmias.<sup>36,37</sup> In canine studies, serotonin was implicated in paroxysmal ventricular tachycardias and atrial arrhythmias.<sup>38,39</sup> The underlying mechanism is thought to be increased sympathetic discharge induced by a vasoactive substance, leading to cardiac excitation and tachyarrhythmias.<sup>35</sup>

**Direct Myocardial Involvement.** A fourth manifestation of carcinoid HD is tumor metastasis directly to the cardiac muscle. In one series<sup>40</sup> (incidence of metas-



**Fig. 1** Diagram shows clinical manifestations of carcinoid heart disease.

tasis, 3.8%), most of the tumors were on either ventricle (including the ventricular septum), and all were circumscribed, homogeneous, and noninfiltrative on echocardiograms.<sup>40</sup> Lesions smaller than 1 cm are usually not detectable on echocardiograms,<sup>41</sup> and positron-emission tomography/computed tomography (PET/CT) may prove more useful.<sup>42,43</sup> Of note, the presence of cardiac carcinoid metastasis did not correlate with the usual echocardiographic findings of carcinoid HD, such as right-sided valvular involvement; however, metastasis to the heart did correlate with higher tumor burden.<sup>43-45</sup> This finding suggests 2 different pathophysiologic mechanisms related to different manifestations of a single disease. Cardiac carcinoid metastasis can be asymptomatic, such as when it presents as a solitary atrial mass,<sup>46</sup> or it can cause ventricular outflow tract obstruction. These tumors are usually well-circumscribed and noninvasive, so excision may be beneficial.<sup>46-48</sup>

## Prognostic Factors

Some prognostic factors for carcinoid HD have been studied. Increases in carcinoid-related symptoms may indicate disease progression in affected patients; however, the disease in asymptomatic patients appears to remain stable.<sup>24,49</sup> Radiographic progression does not seem to correlate with disease progression.<sup>24</sup> On the other hand, biochemical markers—specifically increased urinary and serum levels of 5-hydroxyindoleacetic acid (5-HIAA), a product of serotonin metabolism—correlate well with progression.<sup>22,49</sup> This last finding has substantial implications for therapeutic approaches.

## Diagnosis

The diagnosis of carcinoid HD depends upon strong clinical suspicion, biomarker levels, cardiac imaging results, and possibly the use of cardiac nuclear medicine.<sup>50</sup>

*Electrocardiography.* Electrocardiograms provide little diagnostic support. Sinus tachycardia and nonspecific ST-T abnormalities may be seen. In advanced disease, low-voltage QRS complexes have been detected.<sup>10,51</sup>

*Biomarker Levels.* In the presence of carcinoid syndrome, increased urinary 5-HIAA levels and chromogranin A are useful in evaluating cardiac involvement and disease progression.<sup>52,53</sup> An even stronger biomarker, N-terminal pro-brain-type natriuretic peptide (NT-proBNP), has both diagnostic and prognostic significance.<sup>52</sup>

The cardiac hormone NT-proBNP is released by the atria and ventricles in response to stretching from volume or pressure overload. Levels of NT-proBNP can be elevated for various reasons; however, in one series of patients, NT-proBNP had a sensitivity of 92% and a specificity of 91% for carcinoid HD.<sup>52</sup> Therefore, it is a good screening test for heart involvement. Furthermore, higher NT-proBNP levels correlate strongly with worsening symptoms and poor survival prospects.<sup>52,54</sup>

When a carcinoid tumor metabolizes tryptophan, the resulting serotonin then breaks down into 5-HIAA, which is entirely excreted in the urine. Patients with cardiac carcinoid involvement have elevated levels of serum and urinary 5-HIAA.<sup>22</sup> This acid is also correlated with disease progression, but less strongly than is NT-proBNP.<sup>49</sup>

Chromogranin A, another marker released by neuroendocrine tumors, screens poorly for those tumors in general (sensitivity, 60%–90%; specificity, 10%–35%) and is better used during follow-up evaluation for recurrent malignancy.<sup>55,56</sup> It has a sensitivity approaching 100% but only 30% specificity for carcinoid HD.<sup>53,57</sup> Taken together, chromogranin A and NT-proBNP levels correlate well with carcinoid HD progression and overall mortality rates.<sup>53</sup>

New and potentially superior techniques for measuring biomarkers are emerging. A polymerase chain reaction-based 51-marker peripheral blood test had good sensitivity (85%–98%) and specificity (93%–97%) in diagnosing carcinoid tumors.<sup>58</sup> Results of further studies will indicate whether the diagnostic value of these tests justifies their financial cost.

*Imaging.* Currently available imaging methods can be used in the diagnosis of carcinoid HD.

Chest radiographs in patients with carcinoid HD usually show normal findings but may also reveal nonspecific right-sided heart enlargement, pulmonary nodules, or pleural effusions.<sup>10</sup>

Given the facility of 2-dimensional (2D) transthoracic echocardiography (TTE) to characterize RV, TV, and PV function,<sup>59</sup> it is the chief diagnostic tool for carcinoid HD, and the North American Neuroendocrine Tumor Society recommends its use.<sup>60</sup> The European Neuroendocrine Tumor Society (ENTS) recommends TTE screening for patients diagnosed with carcinoid

syndrome, annually for patients with no cardiac involvement and semiannually for those with it.<sup>61</sup> In addition, TTE can reveal intracardiac carcinoid metastases (present in approximately 4% of cases of carcinoid syndrome).<sup>41</sup> Color-flow Doppler evaluation and agitated saline solution are routinely used to rule out intra-atrial communication, a finding that suggests left-sided cardiac carcinoid involvement.<sup>62</sup>

Initial TV and PV involvement can be minimal, presenting with mild leaflet thickening. At advanced stages, thick, retracted, immobile TV leaflets cause mild-to-moderate tricuspid regurgitation, and the chordae tendineae and papillary muscle can become thick and short.<sup>10,40</sup> A thickened PV causes pulmonary regurgitation or, less frequently, pulmonary stenosis.<sup>10,40</sup>

Three-dimensional (3D) TTE usefully characterizes right-sided heart structure and function,<sup>63</sup> including the pathologic valvular conditions in carcinoid HD, although more studies are warranted.<sup>40</sup> Investigators of aortic valve carcinoid involvement (a rare condition) preferred 3D TTE over 2D TTE.<sup>64</sup>

Speckle-tracking TTE enables the use of ventricular strain to stratify risk in patients who have carcinoid HD.<sup>65</sup> Reduced myocardial function, as measured by using speckle-tracking strain, is associated with more advanced disease stages and with death.<sup>66</sup>

Whereas 2D TTE is superior to multidetector cardiac CT in measuring hemodynamic status, the latter helps to characterize cardiac metastases, RV structure and dysfunction, and PV and TV compromise.<sup>67,68</sup>

Cardiac magnetic resonance enables functional, volumetric, and structural characterizations of the right-sided heart valves—specifically, PV involvement—that 2D TTE cannot readily reveal.<sup>69,70</sup> Cardiac carcinoid metastases and structural infiltration appear clearly. The ENTS recommends using cardiac magnetic resonance to evaluate PV involvement, RV function, and metastasis in carcinoid HD.<sup>71</sup> This imaging method is an excellent alternative when suboptimal TTE images are obtained or when quantifying regurgitant jets on 2D TTE is difficult.<sup>40,60</sup>

Cardiac carcinoid metastases can be revealed by PET/CT and radionuclide tracer. The tracer, a somatostatin analogue, binds the somatostatin receptors on the carcinoid tumor that is affecting the heart (of note, the tracer is not useful in the presence of nonmetastatic carcinoid HD). <sup>18</sup>F-dihydroxyphenylalanine, gallium-68 octreotide, and indium-111 octreotide have been used as tracers,<sup>72-75</sup> but new ones such as iobenguane I-123 might have better sensitivity and specificity for neuroendocrine tumors in general and necessitate less radiation.<sup>76</sup>

## Disease Management

The management of carcinoid HD necessitates multidisciplinary control of progressive heart failure, treat-

ment of systemic malignancy and neuroendocrine derangements, and surgical correction of right-sided valvular involvement.<sup>6</sup> Of note for all practitioners, bacterial endocarditis prophylaxis is not indicated in patients who have carcinoid HD.<sup>77</sup>

### Medical Therapy

Tricuspid regurgitation and right-sided heart failure lead to progressive heart failure. Loop and thiazide diuretic agents should be carefully administered to control fluid status without risking volume depletion, which causes fatigue and low cardiac output.<sup>13</sup>

The somatostatin analogues octreotide and lanreotide inhibit tumoral serotonin secretion and lower the resultant 5-HIAA levels, thus relieving symptoms of carcinoid syndrome. However, these medications neither reverse the progression of the carcinoid cardiac involvement nor improve survival prospects.<sup>71,78,79</sup> Somatostatin analogues control carcinoid-syndrome crises that can lead to preoperative hemodynamic instability. To prevent the tumor from releasing vasoactive metabolites, patients should not be given drugs such as dopamine, opioids, or epinephrine before undergoing cardiac surgery. Antihistamines may be given preoperatively to prevent flushing and bronchospasm.

Telotristat etiprate, a peripheral 5-HT synthesis inhibitor, is approved in the United States for diarrhea control in carcinoid syndrome.<sup>80</sup> Studies are needed to determine whether this medication prevents carcinoid HD from progressing.

Another new somatostatin analogue, pasireotide, has helped symptomatic patients whose carcinoid syndrome is refractory to octreotide therapy. However, results of a phase-3 clinical trial showed no statistically significant difference between pasireotide and octreotide in symptom control upon 6-month follow-up evaluation.<sup>81</sup>

Interferon-alpha may be given to patients who have uncontrolled carcinoid syndrome resistant to somatostatin; however, its side effects may cause patients to discontinue therapy.<sup>82,83</sup> Monoclonal antibody therapy and other chemotherapeutic agents have been studied in a phase-I clinical trial.<sup>84</sup> Paclitaxel and trastuzumab in combination with interleukin-12 may be suitable therapy for human epidermal growth factor receptor 2/neu-expressing malignancies, including carcinoid tumors.<sup>85</sup>

### Surgical Treatment

Surgical correction of carcinoid valvular disease is the only definitive way to alleviate symptoms.<sup>86,87</sup> Indications for valve replacement are symptomatic valvular disease and RV dysfunction.<sup>86</sup> To correct tricuspid regurgitation, TV replacement is most appropriate. In PV disease, valve replacement with patch enlargement of the RV outflow tract is preferred over valve resection.<sup>86</sup> Balloon valvuloplasty of the PV has been performed in poor surgical candidates; however, recurrent valvular

disease and the risk of coexistent TV and PV regurgitation limit its use.<sup>88,89</sup> The replacement of both valves has been described.<sup>90</sup> Median survival times of 6 to 11 years after valve replacement have been reported.<sup>12</sup> Replacement of a diseased TV when the PV was not severely involved was associated with a low risk of subsequent PV dysfunction and the need for further surgical intervention.<sup>91</sup>

Biological or mechanical prostheses may be implanted. Bioprosthetic valves can degenerate early because of graft failure and carcinoid-guided fibrosis; however, this can be avoided through postoperative control of neuroendocrine effects.<sup>92</sup> Despite possible thrombosis in bioprosthetic valves, lifelong anticoagulation is rarely indicated (in general, 3–6 mo of anticoagulation is prescribed).<sup>93</sup> Mechanical valves, although durable, warrant anticoagulation after insertion, which increases the risk of bleeding and the need for reoperation.<sup>6</sup>

Investigators have performed 3D printing of 3D echocardiographic images to better characterize left-sided valvular disease and RV cardiac tumors<sup>94</sup>; we do not know if this has been done before right-sided valvular repair in carcinoid HD. In patients with left-sided carcinoid valvular involvement from presumed interatrial shunts, surgical shunt closure has enabled symptom control.<sup>95</sup>

### Conclusion

The diagnosis and management of carcinoid HD are complex. Patients with right-sided heart failure may have a poorer prognosis. Advances in diagnostic techniques have improved the detection of cardiac carcinoid involvement. Symptom control and longer-term survival are possible through appropriate medical therapy and surgical treatment. Results of ongoing clinical trials may reveal further improvements in diagnosis and treatment.

### References

1. Modlin IM, Sandor A. An analysis of 8305 cases of carcinoid tumors. *Cancer* 1997;79(4):813-29.
2. Taal BG, Visser O. Epidemiology of neuroendocrine tumours. *Neuroendocrinology* 2004;80 Suppl 1:3-7.
3. Crocetti E, Paci E. Malignant carcinoids in the USA, SEER 1992-1999. An epidemiological study with 6830 cases. *Eur J Cancer Prev* 2003;12(3):191-4.
4. Onaitis MW, Kirshbom PM, Hayward TZ, Quayle FJ, Feldman JM, Seigler HF, Tyler DS. Gastrointestinal carcinoids: characterization by site of origin and hormone production. *Ann Surg* 2000;232(4):549-56.
5. Modlin IM, Kidd M, Latich I, Zikusoka MN, Shapiro MD. Current status of gastrointestinal carcinoids. *Gastroenterology* 2005;128(6):1717-51.
6. Grozinsky-Glasberg S, Grossman AB, Gross DJ. Carcinoid heart disease: from pathophysiology to treatment--'something in the way it moves'. *Neuroendocrinology* 2015;101(4):263-73.
7. Sharma R, Biswas B, Wahal SP, Sharma N, Kaushal V. Primary ovarian carcinoid in mature cystic teratoma: a rare en-

- tity. *Clin Cancer Investig J* 2014;3(1):80-2. Available from: <http://www.ccij-online.org/text.asp?2014/3/1/80/125803>.
8. Robboy SJ, Norris HJ, Scully RE. Insular carcinoid primary in the ovary. A clinicopathologic analysis of 48 cases. *Cancer* 1975;36(2):404-18.
  9. Lundin L, Norheim I, Landelius J, Oberg K, Theodorsson-Norheim E. Carcinoid heart disease: relationship of circulating vasoactive substances to ultrasound-detectable cardiac abnormalities. *Circulation* 1988;77(2):264-9.
  10. Pellikka PA, Tajik AJ, Khandheria BK, Seward JB, Callahan JA, Pitot HC, Kvols LK. Carcinoid heart disease. Clinical and echocardiographic spectrum in 74 patients. *Circulation* 1993;87(4):1188-96.
  11. Westberg G, Wangberg B, Ahlman H, Bergh CH, Beckman-Suurkula M, Caidahl K. Prediction of prognosis by echocardiography in patients with midgut carcinoid syndrome. *Br J Surg* 2001;88(6):865-72.
  12. Moller JE, Pellikka PA, Bernheim AM, Schaff HV, Rubin J, Connolly HM. Prognosis of carcinoid heart disease: analysis of 200 cases over two decades. *Circulation* 2005;112(21):3320-7.
  13. Fox DJ, Khattar RS. Carcinoid heart disease: presentation, diagnosis, and management. *Heart* 2004;90(10):1224-8.
  14. Mansencal N, Mitry E, Forissier JF, Martin F, Redheuil A, Lepere C, et al. Assessment of patent foramen ovale in carcinoid heart disease. *Am Heart J* 2006;151(5):1129.e1-6.
  15. Connolly HM, Schaff HV, Mullany CJ, Rubin J, Abel MD, Pellikka PA. Surgical management of left-sided carcinoid heart disease. *Circulation* 2001;104(12 Suppl 1):I36-40.
  16. Oates JA, Pettinger WA, Doctor RB. Evidence for the release of bradykinin in carcinoid syndrome. *J Clin Invest* 1966;45(2):173-8.
  17. Gustafsson BI, Hauso O, Drozdov I, Kidd M, Modlin IM. Carcinoid heart disease. *Int J Cardiol* 2008;129(3):318-24.
  18. Zuetenhorst JM, Bonfrer JM, Korse CM, Bakker R, van Tinteren H, Taal BG. Carcinoid heart disease: the role of urinary 5-hydroxyindoleacetic acid excretion and plasma levels of atrial natriuretic peptide, transforming growth factor-beta and fibroblast growth factor. *Cancer* 2003;97(7):1609-15.
  19. Manivet P, Schneider B, Smith JC, Choi DS, Maroteaux L, Kellermann O, Launay JM. The serotonin binding site of human and murine 5-HT<sub>2B</sub> receptors: molecular modeling and site-directed mutagenesis. *J Biol Chem* 2002;277(19):17170-8.
  20. Fitzgerald LW, Burn TC, Brown BS, Patterson JP, Corjay MH, Valentine PA, et al. Possible role of valvular serotonin 5-HT<sub>2B</sub> receptors in the cardiopathy associated with fenfluramine. *Mol Pharmacol* 2000;57(1):75-81.
  21. Rothman RB, Baumann MH, Savage JE, Rausler L, McBride A, Hufeisen SJ, Roth BL. Evidence for possible involvement of 5-HT<sub>2B</sub> receptors in the cardiac valvulopathy associated with fenfluramine and other serotonergic medications. *Circulation* 2000;102(23):2836-41.
  22. Moller JE, Connolly HM, Rubin J, Seward JB, Modesto K, Pellikka PA. Factors associated with progression of carcinoid heart disease. *N Engl J Med* 2003;348(11):1005-15.
  23. Hedinger C, Gloor R. Metastasizing carcinoid of the small intestine, tricuspid valve disease and pulmonary stenosis, a new syndrome [in German]. *Schweiz Med Wochenschr* 1954;84(33):942-6.
  24. Bhattacharyya S, Davar J, Dreyfus G, Caplin ME. Carcinoid heart disease. *Circulation* 2007;116(24):2860-5.
  25. Dobson R, Burgess MI, Pritchard DM, Cuthbertson DJ. The clinical presentation and management of carcinoid heart disease. *Int J Cardiol* 2014;173(1):29-32.
  26. Yuan SM. Valvular disorders in carcinoid heart disease. *Braz J Cardiovasc Surg* 2016;31(5):400-5.
  27. Eapen DJ, Clements S Jr, Block P, Sperling L. Metastatic carcinoid disease inducing coronary vasospasm. *Tex Heart Inst J* 2012;39(1):76-8.
  28. Erdem R, Slabbynck H, Van den Branden F. Carcinoid crisis with fatal coronary spasm in a small localized peripheral bronchial carcinoid. *Acta Cardiol* 2010;65(4):471-5.
  29. Bourgault C, Bergeron S, Bogaty P, Poirier P. A most unusual acute coronary syndrome. *Can J Cardiol* 2006;22(5):429-32.
  30. Lamping KG, Dole WP. Acute hypertension selectively potentiates constrictor responses of large coronary arteries to serotonin by altering endothelial function in vivo. *Circ Res* 1987;61(6):904-13.
  31. Mitsuoka W, Egashira S, Tagawa H, Kuga T, Hayashi Y, Yamada A, et al. Augmentation of coronary responsiveness to serotonin at the site of x-ray-induced intimal thickening in miniature pigs. *Cardiovasc Res* 1995;30(2):246-54.
  32. Frishman WH, Grewall P. Serotonin and the heart. *Ann Med* 2000;32(3):195-209.
  33. McFadden EP, Clarke JG, Davies GJ, Kaski JC, Haider AW, Maseri A. Effect of intracoronary serotonin on coronary vessels in patients with stable angina and patients with variant angina. *N Engl J Med* 1991;324(10):648-54.
  34. Ardlie NG, Cameron HA, Garrett J. Platelet activation by circulating levels of hormones: a possible link in coronary heart disease. *Thromb Res* 1984;36(4):315-22.
  35. Rupp AB, Ahmadjee A, Morshedzadeh JH, Ranjan R. Carcinoid syndrome-induced ventricular tachycardia. *Case Rep Cardiol* 2016;2016:9142598.
  36. Kuczma JA, Grzywa M. Broncho-pulmonary carcinoid with the cardiac arrhythmia manifestation [in Polish]. *Pol Arch Med Wewn* 2006;116(4):971-3.
  37. Langer C, Piper C, Vogt J, Heintze J, Butz T, Lindner O, et al. Atrial fibrillation in carcinoid heart disease: the role of serotonin. A review of the literature. *Clin Res Cardiol* 2007;96(2):114-8.
  38. Tappin S, Brown P, Ferasin L. An intestinal neuroendocrine tumour associated with paroxysmal ventricular tachycardia and melaena in a 10-year-old boxer. *J Small Anim Pract* 2008;49(1):33-7.
  39. Kuruvilla A, Aiman R. Influence of 5-hydroxytryptamine on experimentally induced atrial arrhythmias in dogs. *Indian J Physiol Pharmacol* 1973;17(2):111-6.
  40. Bhattacharyya S, Toumpanakis C, Burke M, Taylor AM, Caplin ME, Davar J. Features of carcinoid heart disease identified by 2- and 3-dimensional echocardiography and cardiac MRI. *Circ Cardiovasc Imaging* 2010;3(1):103-11.
  41. Pandya UH, Pellikka PA, Enriquez-Sarano M, Edwards WD, Schaff HV, Connolly HM. Metastatic carcinoid tumor to the heart: echocardiographic-pathologic study of 11 patients. *J Am Coll Cardiol* 2002;40(7):1328-32.
  42. Jann H, Wertenbruch T, Pape U, Ozcelik C, Denecke T, Mehl S, et al. A matter of the heart: myocardial metastases in neuroendocrine tumors. *Horm Metab Res* 2010;42(13):967-76.
  43. Bonsel LR, Aalbersberg EA, Tesselaar M, Stokkel MP. Cardiac neuroendocrine tumour metastases: case reports and review of the literature. *Nucl Med Commun* 2016;37(5):461-5.
  44. Williams AR, Wang A, Kim H, Milano CA. Resection of carcinoid tumor metastatic to the right ventricle and tricuspid valve. *Ann Thorac Surg* 2015;100(6):2348-50.
  45. Noordzij W, van Beek AP, Tio RA, van der Horst-Schrivers AN, de Vries EG, van Ginkel B, et al. Myocardial metastases on 6-[18F] fluoro-L-DOPA PET/CT: a retrospective analysis of 116 serotonin producing neuroendocrine tumour patients. *PLoS One* 2014;9(11):e112278.
  46. Meurice J, Boule S, Deswarte G, Brigadeau F, Modine T. Solitary atrial myocardial metastasis revealing ileal neuroendocrine carcinoma. *Cardiovasc Pathol* 2012;21(4):355-7.

47. Chrysant GS, Horstmanshof DA, Guniganti UM. Metastatic carcinoid tumor obstructing left ventricular outflow. *Tex Heart Inst J* 2011;38(3):282-4.
48. Sareyyupoglu B, Connolly HM, Schaff HV. Surgical excision of right ventricular carcinoid tumor in a symptomatic patient without carcinoid valve disease. *J Thorac Cardiovasc Surg* 2010;140(2):e23-5.
49. Bhattacharyya S, Toumpanakis C, Chilkunda D, Caplin ME, Davar J. Risk factors for the development and progression of carcinoid heart disease. *Am J Cardiol* 2011;107(8):1221-6.
50. Davar J, Connolly HM, Caplin ME, Pavel M, Zacks J, Bhattacharyya S, et al. Diagnosing and managing carcinoid heart disease in patients with neuroendocrine tumors: an expert statement. *J Am Coll Cardiol* 2017;69(10):1288-304.
51. Palaniswamy C, Frishman WH, Aronow WS. Carcinoid heart disease. *Cardiol Rev* 2012;20(4):167-76.
52. Bhattacharyya S, Toumpanakis C, Caplin ME, Davar J. Usefulness of N-terminal pro-brain natriuretic peptide as a biomarker of the presence of carcinoid heart disease. *Am J Cardiol* 2008;102(7):938-42.
53. Korse CM, Taal BG, de Groot CA, Bakker RH, Bonfrer JM. Chromogranin-A and N-terminal pro-brain natriuretic peptide: an excellent pair of biomarkers for diagnostics in patients with neuroendocrine tumor. *J Clin Oncol* 2009;27(26):4293-9.
54. Zuetenhorst JM, Korse CM, Bonfrer JM, Bakker RH, Taal BG. Role of natriuretic peptides in the diagnosis and treatment of patients with carcinoid heart disease. *Br J Cancer* 2004;90(11):2073-9.
55. Modlin IM, Oberg K, Chung DC, Jensen RT, de Herder WW, Thakker RV, et al. Gastroenteropancreatic neuroendocrine tumours. *Lancet Oncol* 2008;9(1):61-72.
56. Kanakis G, Kaltsas G. Biochemical markers for gastroenteropancreatic neuroendocrine tumours (GEP-NETs). *Best Pract Res Clin Gastroenterol* 2012;26(6):791-802.
57. Kidd M, Bodei L, Modlin IM. Chromogranin A: any relevance in neuroendocrine tumors? *Curr Opin Endocrinol Diabetes Obes* 2016;23(1):28-37.
58. Modlin IM, Aslanian H, Bodei L, Drozdov I, Kidd M. A PCR blood test outperforms chromogranin A in carcinoid detection and is unaffected by proton pump inhibitors. *Endocr Connect* 2014;3(4):215-23.
59. Dobson R, Cuthbertson DJ, Burgess MI. The optimal use of cardiac imaging in the quantification of carcinoid heart disease. *Endocr Relat Cancer* 2013;20(5):R247-55.
60. Kunz PL, Reidy-Lagunes D, Anthony LB, Bertino EM, Brendtro K, Chan JA, et al. Consensus guidelines for the management and treatment of neuroendocrine tumors. *Pancreas* 2013;42(4):557-77.
61. Arnold R, Chen YJ, Costa F, Falconi M, Gross D, Grossman AB, et al. ENETS consensus guidelines for the standards of care in neuroendocrine tumors: follow-up and documentation. *Neuroendocrinology* 2009;90(2):227-33.
62. Plockinger U, Gustafsson B, Ivan D, Szpak W, Davar J. ENETS consensus guidelines for the standards of care in neuroendocrine tumors: echocardiography. *Neuroendocrinology* 2009;90(2):190-3.
63. Luxford J, Bassin L, D'Ambra M. Echocardiography of the tricuspid valve. *Ann Cardiothorac Surg* 2017;6(3):223-39. Available from: <http://www.annalscts.com/article/view/15055/15199>.
64. Bulur S, Hsiung MC, Nanda NC, Hardas S, Mohamed A, Elkaryoni A, et al. Incremental value of live/real time three-dimensional transthoracic echocardiography over the two-dimensional technique in assessing carcinoid heart disease involving the aortic valve. *Echocardiography* 2016;33(11):1741-4.
65. Haugaa KH, Bergestuen DS, Sahakyan LG, Skulstad H, Aakhus S, Thiis-Evensen E, Edvardsen T. Evaluation of right ventricular dysfunction by myocardial strain echocardiography in patients with intestinal carcinoid disease. *J Am Soc Echocardiogr* 2011;24(6):644-50.
66. Zahid W, Bergestuen D, Haugaa KH, Ueland T, Thiis-Evensen E, Aukrust P, et al. Myocardial function by two-dimensional speckle tracking echocardiography and activin A may predict mortality in patients with carcinoid intestinal disease. *Cardiology* 2015;132(2):81-90.
67. Manghat NE, Rachapalli V, Van Lingen R, Veitch AM, Roobottom CA, Morgan-Hughes GJ. Imaging the heart valves using ECG-gated 64-detector row cardiac CT. *Br J Radiol* 2008;81(964):275-90.
68. Wu PW, Chen SJ, Lin WC, Chang CB, Chuang WY, Hsu MY, et al. Imaging of cardiac and pericardial masses. *Cardiovasc Imaging Asia* 2017;1(1):23-37. Available from: <https://e-cvia.org/DOIx.php?id=10.22468/cvia.2016.00059>.
69. Franzen D, Boldt A, Raute-Kreinsen U, Koerfer R, Erdmann E. Magnetic resonance imaging of carcinoid heart disease. *Clin Cardiol* 2009;32(6):E92-3.
70. Bastarrika G, Cao MG, Cano D, Barba J, de Buruaga JD. Magnetic resonance imaging diagnosis of carcinoid heart disease. *J Comput Assist Tomogr* 2005;29(6):756-9.
71. Ramage JK, Davies AH, Ardill J, Bax N, Caplin M, Grossman A, et al. Guidelines for the management of gastroenteropancreatic neuroendocrine (including carcinoid) tumours. *Gut* 2005;54 Suppl 4:iv1-16.
72. Calissendorff J, Sundin A, Falhammar H. 68Ga-DOTA-TOC-PET/CT detects heart metastases from ileal neuroendocrine tumors. *Endocrine* 2014;47(1):169-76.
73. Fiebrich HB, Brouwers AH, Links TP, de Vries EG. Images in cardiovascular medicine: myocardial metastases of carcinoid visualized by 18 F-dihydroxy-phenyl-alanine positron emission tomography. *Circulation* 2008;118(15):1602-4.
74. Baumann T, Rottenburger C, Nicolas G, Wild D. Gastroenteropancreatic neuroendocrine tumours (GEP-NET) - imaging and staging. *Best Pract Res Clin Endocrinol Metab* 2016;30(1):45-57.
75. Farooqui M, Rathore S, Ball T. Utility of indium-111 octreotide to identify a cardiac metastasis of a carcinoid neoplasm. *Proc (Bayl Univ Med Cent)* 2016;29(1):76-8.
76. Chin BB, Kronauge JF, Femia FJ, Chen J, Maresca KP, Hillier S, et al. Phase-1 clinical trial results of high-specific-activity carrier-free 123I-iodobenguane. *J Nucl Med* 2014;55(5):765-71.
77. Nishimura RA, Carabello BA, Faxon DP, Freed MD, Lytle BW, O'Gara PT, et al. ACC/AHA 2008 Guideline update on valvular heart disease: focused update on infective endocarditis: a report of the American College of Cardiology/American Heart Association Task Force on Practice Guidelines endorsed by the Society of Cardiovascular Anesthesiologists, Society for Cardiovascular Angiography and Interventions, and Society of Thoracic Surgeons. *J Am Coll Cardiol* 2008;52(8):676-85.
78. Denney WD, Kemp WE Jr, Anthony LB, Oates JA, Byrd BF 3rd. Echocardiographic and biochemical evaluation of the development and progression of carcinoid heart disease. *J Am Coll Cardiol* 1998;32(4):1017-22.
79. Modlin IM, Latich I, Kidd M, Zikusoka M, Eick G. Therapeutic options for gastrointestinal carcinoids. *Clin Gastroenterol Hepatol* 2006;4(5):526-47.
80. Kulke MH, Horsch D, Caplin M, Anthony L, Bergsland E, Oberg K, et al. 37LBA Telotristat etiprate is effective in treating patients with carcinoid syndrome that is inadequately controlled by somatostatin analog therapy (the phase 3 TELESTAR clinical trial) [abstract]. *Eur J Cancer* 2015;51(Suppl 3):S728. Available from: [https://www.ejccancer.com/article/S0959-8049\(16\)31951-7/abstract](https://www.ejccancer.com/article/S0959-8049(16)31951-7/abstract).

81. Wolin EM, Jarzab B, Eriksson B, Walter T, Toumpanakis C, Morse MA, et al. Phase III study of pasireotide long-acting release in patients with metastatic neuroendocrine tumors and carcinoid symptoms refractory to available somatostatin analogues. *Drug Des Devel Ther* 2015;9:5075-86.
82. Ardill J, Johnston B, McCance D. Response to interferon alpha (IFA) in patients with small bowel neuroendocrine tumors (SB-NETs) [abstract]. Available from: <https://nanets.net/abstracts-archive/2015/361-c03-response-to-interferon-alpha-ifa-in-patients-with-small-bowel-neuroendocrine-tumors-sb-nets/file> [cited 2018 Nov 27].
83. Janson ET, Oberg K. Long-term management of the carcinoid syndrome. Treatment with octreotide alone and in combination with alpha-interferon. *Acta Oncol* 1993;32(2):225-9.
84. Mulvey CK, Bergsland EK. Systemic therapies for advanced gastrointestinal carcinoid tumors. *Hematol Oncol Clin North Am* 2016;30(1):63-82.
85. Bekaii-Saab TS, Roda JM, Guenterberg KD, Ramaswamy B, Young DC, Ferketich AK, et al. A phase I trial of paclitaxel and trastuzumab in combination with interleukin-12 in patients with HER2/neu-expressing malignancies. *Mol Cancer Ther* 2009;8(11):2983-91.
86. Connolly HM, Schaff HV, Abel MD, Rubin J, Askew JW, Li Z, et al. Early and late outcomes of surgical treatment in carcinoid heart disease. *J Am Coll Cardiol* 2015;66(20):2189-96.
87. Edwards NC, Yuan M, Nolan O, Pawade TA, Oelofse T, Singh H, et al. Effect of valvular surgery in carcinoid heart disease: an observational cohort study. *J Clin Endocrinol Metab* 2016;101(1):183-90.
88. Hargreaves AD, Pringle SD, Boon NA. Successful balloon dilatation of the pulmonary valve in carcinoid heart disease. *Int J Cardiol* 1994;45(2):150-1.
89. Grant SC, Scarffe JH, Levy RD, Brooks NH. Failure of balloon dilatation of the pulmonary valve in carcinoid pulmonary stenosis. *Br Heart J* 1992;67(6):450-3.
90. Voigt PG, Braun J, Teng OY, Koolbergen DR, Holman E, Bax JJ, et al. Double bioprosthetic valve replacement in right-sided carcinoid heart disease. *Ann Thorac Surg* 2005;79(6):2147-9.
91. Luis SA, Pellikka PA, Schaff HV, Connolly HM. Abstract 20034: Fate of the native pulmonary valve in patients with carcinoid heart disease after tricuspid valve replacement [abstract]. *Circulation* 2016;134(Suppl 1):A20034. Available from: [https://www.ahajournals.org/doi/abs/10.1161/circ.134.suppl\\_1.20034](https://www.ahajournals.org/doi/abs/10.1161/circ.134.suppl_1.20034).
92. Ridker PM, Chertow GM, Karlson EW, Neish AS, Schoen FJ. Bioprosthetic tricuspid valve stenosis associated with extensive plaque deposition in carcinoid heart disease. *Am Heart J* 1991;121(6 Pt 1):1835-8.
93. Pislaru SV, Hussain I, Pellikka PA, Maleszewski JJ, Hanna RD, Schaff HV, Connolly HM. Misconceptions, diagnostic challenges and treatment opportunities in bioprosthetic valve thrombosis: lessons from a case series. *Eur J Cardiothorac Surg* 2015;47(4):725-32.
94. Farooqi KM, Sengupta PP. Echocardiography and three-dimensional printing: sound ideas to touch a heart. *J Am Soc Echocardiogr* 2015;28(4):398-403.
95. Boglioli LR, Gardiner J, Gerstenblith G, Taff ML, Cameron DE. Carcinoid heart disease with severe hypoxia due to interatrial shunt through patent foramen ovale. *Tex Heart Inst J* 1997;24(2):125-8.