

# Dabigatran-Induced Spontaneous Hemopericardium and Cardiac Tamponade

Qurat-ul-ain Jelani, MD  
Ram Gordon, MD  
Adam Schussheim, MD

Four novel oral anticoagulant agents are currently available for the prevention and treatment of thromboembolic events in patients with nonvalvular atrial fibrillation. We present an unusual case of spontaneous hemopericardium and tamponade in an 87-year-old man with atrial fibrillation who was taking one such agent, dabigatran, as thromboprophylaxis.

Our case highlights both a rare bleeding complication of dabigatran use and the effectiveness of idarucizumab, its newly approved reversal agent. Especially in elderly patients, we recommend that clinicians evaluate risk factors, closely monitor patient status, and consider alternatives to the newer anticoagulants when the risk of bleeding is high. (*Tex Heart Inst J* 2017;44(5):370-2)

**Key words:** Anticoagulants/administration & dosage/adverse effects/therapeutic use; atrial fibrillation/drug therapy; cardiac tamponade/chemically induced; dabigatran/administration & dosage; pericardial effusion/chemically induced; risk factors; stroke/prevention & control; treatment outcome

**From:** Division of Cardiology, Department of Internal Medicine, Bridgeport Hospital, Yale New Haven Health System, Bridgeport, Connecticut 06610

**Address for reprints:** Qurat-ul-ain Jelani, MD, Division of Cardiology, Department of Internal Medicine, Bridgeport Hospital, Yale New Haven Health System, 267 Grant St., Bridgeport, CT 06610

**E-mail:** qurat-ul-ain.jelani@yale.edu

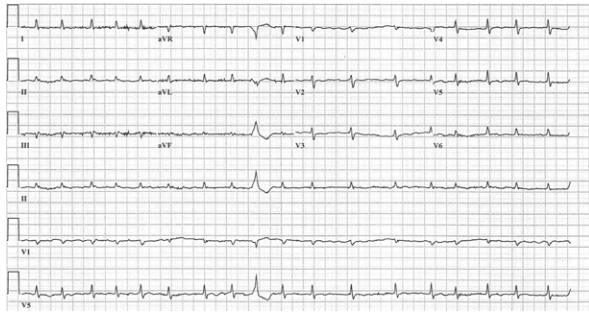
© 2017 by the Texas Heart<sup>®</sup> Institute, Houston

## Case Report

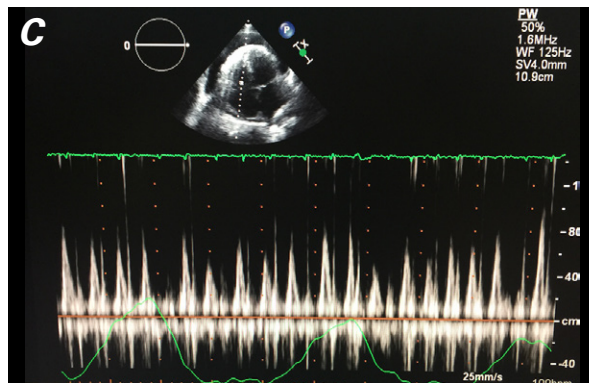
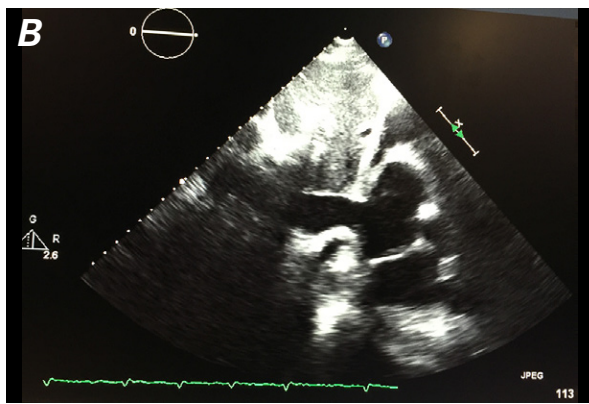
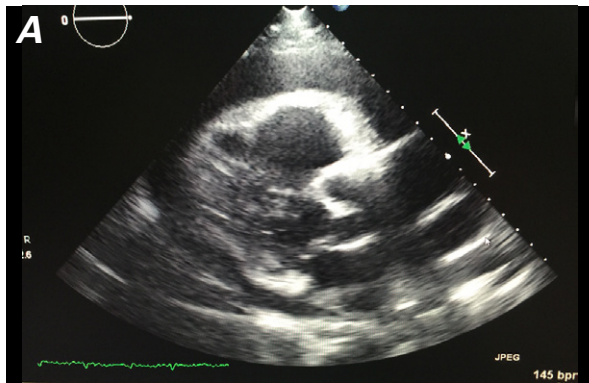
In April 2016, an 87-year-old man with well-controlled hypertension and dyslipidemia was admitted to the hospital with worsening dyspnea on exertion. Two months earlier, he had been prescribed dabigatran (150 mg, twice daily) and metoprolol as therapy for AF of unknown duration. A transthoracic echocardiogram (TTE) at that time had shown nothing notable. He subsequently developed progressive edema, renal insufficiency, hypotension, and tachycardia. His medications included dabigatran, furosemide, metolazone, and metoprolol.

His vital signs upon admission were as follows: blood pressure, 90/50 mmHg; heart rate, 112 beats/min; respiratory rate, 18 breaths/min; and oxygen saturation, 95% on room air. His body weight was 81.6 kg (body mass index, 25.83 kg/m<sup>2</sup>). He had jugular venous distention with a positive Kussmaul sign and bilateral, pitting lower-extremity edema. No other cardiac or respiratory findings were noteworthy.

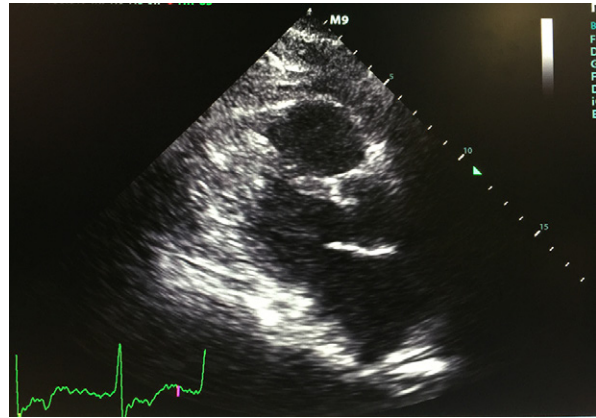
Laboratory test results included new anemia (hemoglobin, 9.7 g/dL) and acute kidney injury (increase in creatinine, from 1.0 to 1.9 mg/dL). The estimated creatinine clearance (CrCl) was 33 mL/min. Results of coagulation studies were normal. An electrocardiogram revealed AF with a ventricular rate of 110 beats/min and new low voltage in all leads (Fig. 1). A TTE showed a large pericardial effusion with tamponade physiology and diastolic compression of the right ventricle (Fig. 2A), a severely dilated inferior vena cava without inspiratory collapse (Fig. 2B), and respiratory variation at the tricuspid inflow with >25% increase during inspiration (Fig. 2C). Idarucizumab was administered, after which emergency pericardiocentesis yielded 750 cc of hemorrhagic pericardial fluid. Fluid samples evaluated by gram stain, culture, and cytology were negative. The patient reported immediate resolution of his symptoms. Serial TTEs revealed no reaccumulation of fluid (Fig. 3). The patient was discharged from the hospital in stable condition, without the need for anticoagulation.



**Fig. 1** Electrocardiogram shows atrial fibrillation and low voltage.



**Fig. 2** Transthoracic echocardiograms show **A**) a large pericardial effusion and diastolic compression of the right ventricle (parasternal long-axis view), and **B**) a severely dilated inferior vena cava without inspiratory collapse (subcostal view). **C**) Pulsed-wave Doppler shows respiratory variation at the tricuspid inflow with >25% increase during inspiration (apical 4-chamber view).



**Fig. 3** Transthoracic echocardiogram (parasternal long-axis view) shows resolution of the pericardial effusion.

## Discussion

Atrial fibrillation is the most prevalent cardiac arrhythmia in the U.S., affecting an estimated 5.2 million Americans in 2010.<sup>3</sup> More than 80% of these patients have an indication for oral anticoagulation<sup>4</sup> to reduce the risk of stroke. The novel oral anticoagulants include dabigatran, which inhibits thrombin; and rivaroxaban, apixaban, and edoxaban, which inhibit factor Xa. These agents are as effective as warfarin in preventing the primary endpoints of stroke and systemic embolism and lowering the risk of major bleeding.<sup>1,5,6</sup> Of importance, these new agents have reduced the rate of intracranial hemorrhage in comparison with vitamin K antagonists<sup>1,5,7,8</sup> but are consistently associated with a higher risk of gastrointestinal bleeding.<sup>7,9</sup>

Our report highlights a rare case of dabigatran-induced hemopericardium and tamponade in a patient who had no clinical evidence of pericarditis, trauma, or renal failure.<sup>10</sup> Spontaneous hemopericardium without tamponade has occurred in patients who took dabigatran,<sup>2</sup> rivaroxaban,<sup>11</sup> and apixaban.<sup>12</sup> Warfarin-associated spontaneous hemopericardium is very rare, and reported cases have been in the context of coagulopathy,<sup>13-16</sup> cardiac surgery,<sup>17</sup> or pericarditis.<sup>18,19</sup>

Several cases of dabigatran-induced hemopericardium have been reported.<sup>2,10,20,21</sup> Dy and Shiltz<sup>10</sup> reported 2 such cases, with cardiac tamponade in the presence of acute renal failure. Both patients had a CrCl of <30 mL/min. Because approximately 80% of the drug is cleared renally, the FDA recommends that dabigatran doses be decreased to 75 mg twice daily, to maintain a CrCl of 15 to 30 mL/min. Our patient had a CrCl >30 mL/min on presentation, so it is unlikely that impaired dabigatran metabolism contributed to his hemopericardium. In one randomized trial,<sup>9</sup> a dabigatran dose of 110 mg, twice daily, was associated with a lower risk of bleeding than that with warfarin use in patients <75 years of age, and it yielded a similar risk of bleeding in those >75

years old. Conversely, standard dabigatran dosing of 150 mg, twice daily, in patients >75 years old was associated with a trend toward a higher risk of bleeding. Our 87-year-old patient was taking the higher dose, because dabigatran is not available in the 110-mg formulation in the U.S. Caution should be exercised in initiating elderly patients on the higher dose of dabigatran, and the use of an alternative agent might be safer for them.

In October 2016, the FDA approved an antibody fragment, idarucizumab, for dabigatran reversal.<sup>22</sup> There are no FDA-approved antidotes or reversal agents for factor Xa inhibitors. We gave our patient idarucizumab before pericardiocentesis, and we noted no further clinical bleeding or fluid accumulation.

Spontaneous hemopericardium can occur even with appropriate use and dosing of novel oral anticoagulant agents, especially in elderly patients. We recommend that clinicians evaluate patient age, bleeding and fall risks, and renal function before prescribing the newer agents, and that they consider alternatives when the risk of bleeding is high.

## References

1. Connolly SJ, Ezekowitz MD, Yusuf S, Eikelboom J, Oldgren J, Parekh A, et al. Dabigatran versus warfarin in patients with atrial fibrillation [published erratum appears in *N Engl J Med* 2010;363(19):1877]. *N Engl J Med* 2009;361(12):1139-51.
2. Barton CA, McMillian WD, Raza SS, Keller RE. Hemopericardium in a patient treated with dabigatran etexilate. *Pharmacotherapy* 2012;32(5):e103-7.
3. Colilla S, Crow A, Petkun W, Singer DE, Simon T, Liu X. Estimates of current and future incidence and prevalence of atrial fibrillation in the U.S. adult population. *Am J Cardiol* 2013;112(8):1142-7.
4. Lip GY, Laroche C, Dan GA, Santini M, Kalarus Z, Rasmussen LH, et al. A prospective survey in European Society of Cardiology member countries of atrial fibrillation management: baseline results of EURObservational Research Programme Atrial Fibrillation (EORP-AF) Pilot General Registry [published erratum appears in *Europace* 2014;16(6):941]. *Europace* 2014;16(3):308-19.
5. Granger CB, Alexander JH, McMurray JJ, Lopes RD, Hylek EM, Hanna M, et al. Apixaban versus warfarin in patients with atrial fibrillation. *N Engl J Med* 2011;365(11):981-92.
6. Mega JL, Braunwald E, Mohanavelu S, Burton P, Poulter R, Misselwitz F, et al. Rivaroxaban versus placebo in patients with acute coronary syndromes (ATLAS ACS-TIMI 46): a randomised, double-blind, phase II trial. *Lancet* 2009;374(9683):29-38.
7. Patel MR, Mahaffey KW, Garg J, Pan G, Singer DE, Hacke W, et al. Rivaroxaban versus warfarin in nonvalvular atrial fibrillation. *N Engl J Med* 2011;365(10):883-91.
8. Giugliano RP, Ruff CT, Braunwald E, Murphy SA, Wiviott SD, Halperin JL, et al. Edoxaban versus warfarin in patients with atrial fibrillation. *N Engl J Med* 2013;369(22):2093-104.
9. Eikelboom JW, Wallentin L, Connolly SJ, Ezekowitz M, Healey JS, Oldgren J, et al. Risk of bleeding with 2 doses of dabigatran compared with warfarin in older and younger patients with atrial fibrillation: an analysis of the randomized evaluation of long-term anticoagulant therapy (RE-LY) trial. *Circulation* 2011;123(21):2363-72.
10. Dy EA, Shiltz DL. Hemopericardium and cardiac tamponade associated with dabigatran use. *Ann Pharmacother* 2012;46(7-8):e18.
11. Shivamurthy P, Brar N, Therrien ML. Isolated hemopericardium associated with rivaroxaban: first case report. *Pharmacotherapy* 2014;34(9):e169-72.
12. Sigawy C, Apter S, Vine J, Grossman E. Spontaneous hemopericardium in a patient receiving apixaban therapy: first case report. *Pharmacotherapy* 2015;35(7):e115-7.
13. Miller RL. Hemopericardium with use of oral anticoagulant therapy. *JAMA* 1969;209(9):1362-4.
14. Griffiths AP, Beddall A, Pegler S. Fatal haemopericardium and gastrointestinal haemorrhage due to possible interaction of cranberry juice with warfarin. *J R Soc Promot Health* 2008;128(6):324-6.
15. Braiteh F, Plana JC. Spontaneous haemopericardium with subacute cardiac tamponade in a patient with lung cancer receiving coumadin. *QJM* 2009;102(8):575.
16. Al-Jundi W, Rubin N. Cardiac tamponade secondary to hemopericardium in a patient on warfarin. *BMJ Case Rep* 2010;2010.
17. Hong YC, Chen YG, Hsiao CT, Kuan JT, Chiu TF, Chen JC. Cardiac tamponade secondary to hemopericardium in a patient on warfarin. *Emerg Med J* 2007;24(9):679-80.
18. Williams CL Jr, Beckwith JR, Wood JE Jr. Hemorrhagic pericardial fluid in acute benign nonspecific pericarditis: report of a case and review of the literature. *Ann Intern Med* 1960;52:914-23.
19. McCord MC, Taguchi JT. Nonspecific pericarditis; a fatal case. *AMA Arch Intern Med* 1951;87(5):727-31.
20. Stollberger C, Heger M, Finsterer J. Hemopericardium under dabigatran for stroke prevention in atrial fibrillation. *Blood Coagul Fibrinolysis* 2017;28(2):185-8.
21. Kizilirmak F, Gunes HM, Guler E, Demir GG, Karaca O, Canpolat HG. Hemopericardium and cardiac tamponade in a patient treated with dabigatran etexilate. *Korean Circ J* 2016;46(1):99-101.
22. Pollack CV Jr, Reilly PA, Eikelboom J, Glund S, Verhamme P, Bernstein RA, et al. Idarucizumab for dabigatran reversal. *N Engl J Med* 2015;373(6):511-20.