

# Torsades de Pointes after Ondansetron Infusion in 2 Patients

Danny Y. Lee, MD  
Tri Trinh, MD  
Sion K. Roy, MD

*Drugs that prolong the electrocardiographic QT interval increase the risk of ventricular arrhythmias, particularly torsades de pointes. Ondansetron, a 5-hydroxytryptamine type 3 receptor antagonist antiemetic, is one such drug. We present the cases of 2 patients who were given intravenous ondansetron and subsequently developed torsades de pointes. Both had normal QT intervals at baseline but were discovered to have risk factors that predisposed them to drug-induced QT prolongation and ventricular arrhythmias. We briefly review the mechanisms for torsades de pointes caused by QT-prolonging medications, describe characteristics that increase patients' susceptibility to drug-induced QT prolongation, and call attention to the risk of ventricular arrhythmias in patients who are given ondansetron. (Tex Heart Inst J 2017;44(5):366-9)*

**Key words:** Arrhythmias, cardiac/chemically induced; dose-response relationship, drug; drug-related side effects and adverse reactions; electrocardiography/drug effects; emergency treatment; ondansetron/administration & dosage/adverse effects/therapeutic use; product surveillance, postmarketing; risk factors; serotonin 5-HT<sub>3</sub> receptor antagonists/therapeutic use; torsades de pointes/chemically induced/physiopathology

**From:** Division of Cardiology, Los Angeles Biomedical Research Institute at Harbor-UCLA Medical Center, Torrance, California 90502

**Address for reprints:**  
Danny Y. Lee, MD, Department of Electrophysiology, Kaiser Permanente Los Angeles Medical Center, 4867 W. Sunset Blvd., 3rd fl., Los Angeles, CA 90027

**E-mail:** Danny\_Lee@alumni.brown.edu

© 2017 by the Texas Heart® Institute, Houston

**D**rugs that prolong the electrocardiographic (ECG) QT interval increase the risk of ventricular arrhythmias, particularly torsades de pointes. Ondansetron hydrochloride, initially marketed as ZOFRAN® by GlaxoSmithKline and sold in 2014 to Novartis Pharmaceuticals Canada Inc. (Dorval, Québec, Canada), belongs to a class of antiemetics that block 5-hydroxytryptamine type 3 (5-HT<sub>3</sub>) receptors. These antiemetics prolong the QT interval and are associated with arrhythmias and sudden cardiac death.<sup>1,2</sup> Ondansetron is indicated for postoperative nausea and vomiting and for emetogenic chemotherapy; however, it is also frequently prescribed off-label in hospitals to treat other nausea and vomiting. From 1995 through 2009, U.S. emergency physicians prescribed ondansetron during an estimated 2.5 million visits annually (14.9% of all emergency department visits), making it the 3rd most frequently prescribed QT-prolonging drug.<sup>3</sup> In 2011, the U.S. Food and Drug Administration (FDA) issued a warning about the risk of abnormal heart rhythms from high doses of ondansetron.<sup>4</sup>

Torsades de pointes developed in 2 patients at our institute after ondansetron infusions. Both had normal baseline QT intervals and no prior cardiac histories; however, both had risk factors for drug-induced QT prolongation that were identified later. We discuss their cases, briefly review the mechanisms for torsades de pointes caused by QT-prolonging agents, and call attention to the increased risk of ventricular arrhythmias in patients who are given ondansetron.

## Case Reports

### Patient 1

A 51-year-old woman presented at the emergency department with substantial nausea, vomiting, and associated abdominal pain of a week's duration. She also had mandibular pain that led to poor oral intake. A fall 4 months earlier had resulted in right parasymphseal and left-angle mandibular fractures for which she had undergone open-reduction internal fixation. Infected mandibular hardware led to surgical exploration, drainage, and hardware removal. At the current emergency presentation, surgical evaluation for management of mandibular malunion was pending.

The patient's medical history was otherwise not noteworthy. She was taking no medications at home. Her family history was noncontributory. She had a history of alcohol dependence and occasionally smoked tobacco, but reported no illicit-drug use.

Her vital signs were as follows: body temperature, 36.2 °C; blood pressure, 145/83 mmHg; respiratory rate, 20 breaths/min; heart rate, 73 beats/min; and oxygen saturation, 100% on room air.

The patient had jaw pain and discomfort from nausea. No jugular venous distention was noted. Her cardiovascular examination revealed a regular rate and rhythm, with no murmur or gallop on auscultation. Her lungs were clear on auscultation. Results of her abdominal examination were benign, and she had no lower-extremity edema.

Her laboratory results included the following values: sodium, 132 mmol/L; potassium, 3.9 mmol/L; creatinine, 0.94 mg/dL; calcium, 9.5 mg/dL; aspartate aminotransferase, 121 U/L; alanine aminotransferase, 55 U/L; white blood cell count, 5,500/mm<sup>3</sup>; hemoglobin, 12.2 g/dL; hematocrit, 37.8%; and platelet count, 65,000/mm<sup>3</sup>. Her urine toxicology results revealed cannabis and opiates (the latter of which she had received in the emergency department). A baseline ECG showed sinus rhythm with a normal corrected QT interval (QTc) (Fig. 1A).

During the next 24 hours, the patient was infused with 36 mg of ondansetron in total (at 15:22, 20:30, 21:30, 04:00, 12:47, and 13:27). Seven beats of non-sustained ventricular tachycardia (VT) were detected at 04:00, at which point the cumulative infusion was 24 mg. At 13:57, torsades de pointes developed (Fig. 1B), and she became unresponsive and pulseless. Advanced cardiovascular life support measures (including chest compressions and defibrillation) resuscitated the patient, and she soon recovered her mental status.

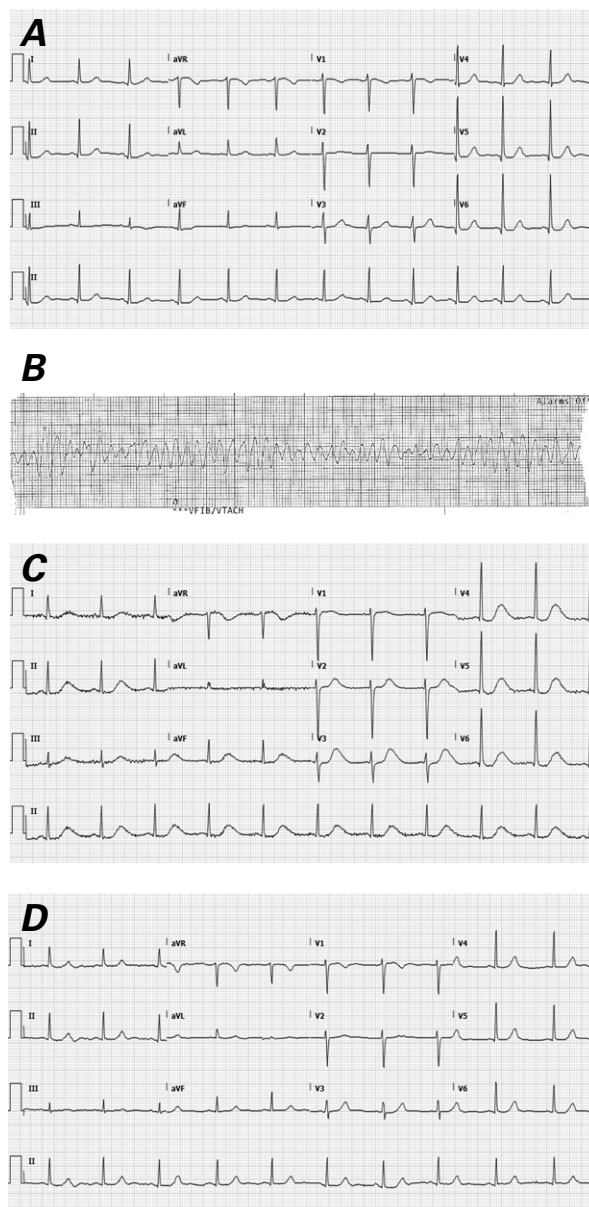
A repeat ECG showed that the patient's QTc had lengthened to 610 ms (Fig. 1C). A transthoracic echocardiogram (TTE) revealed severe left ventricular (LV) systolic dysfunction (estimated ejection fraction, 0.25–0.30). A coronary angiogram showed patent coronary arteries. Two months later, her ECG showed a normal QTc (Fig. 1D).

Given the patient's high-risk presentation of severe cardiomyopathy and near-death experience, a dual-chamber cardioverter-defibrillator was implanted for secondary prevention. The patient tolerated this well and was soon discharged from the hospital, with prescriptions for optimal heart failure therapy. Two months later, she reported doing well, and no tachycardia had been sensed by her device. A TTE showed that her LV ejection fraction had improved (0.40–0.45).

## Patient 2

A 51-year-old man presented at the emergency department with squeezing chest pain that had started earlier the same evening, shortness of breath, and diaphoresis. He also reported a 6-month history of ongoing nausea, vomiting, and diarrhea, associated with fevers and chills. These episodes occurred up to 4 times daily. He had lost approximately 35 lb during this period.

The patient's vital signs were as follows: body temperature, 37.2 °C; heart rate, 88 beats/min; blood pressure, 136/98 mmHg; respiratory rate, 16 breaths/min;



**Fig. 1** Patient 1. **A)** Baseline electrocardiogram (ECG) shows a normal corrected QT interval (QTc). **B)** Rhythm strip shows torsades de pointes after an undocumented precipitating event. **C)** Post-cardiac-arrest ECG shows a prolonged QTc (610 ms). **D)** Two months later, ECG shows a normal QTc.

and oxygen saturation, 99% on room air. Examination results were notable for mildly dry mucous membranes and an episode of retching.

The patient's laboratory values were as follows: sodium, 132 mmol/L; potassium, 3 mmol/L; chloride, 89 mmol/L; bicarbonate, 26 mmol/L; blood urea nitrogen, 6 mg/dL; creatinine, 0.85 mg/dL; glucose, 194 mg/dL; white blood cell count, 8,700/mm<sup>3</sup>; hemoglobin, 13.7 g/dL; hematocrit, 40.2%; and platelet count, 172,000/mm<sup>3</sup>. He was given potassium replacement therapy; 7 hours later, the level improved to 4 mmol/L.

Cardiac troponin I was initially 0.01 ng/mL, peaked at 0.09 ng/mL, then trended downward. An ECG showed sinus rhythm, no ischemic change, and a normal QTc of 458 ms (Fig. 2A).

The patient was given three 4-mg doses of intravenous ondansetron (at 00:23, 01:41, and 10:00). At 21:30, he had multiple nonsustained runs of monomorphic and polymorphic VT (Fig. 2B). His blood pressure remained stable. His QTc had increased to 543 ms (Fig. 2C). Laboratory results obtained several hours later indicated substantial metabolic abnormalities—notably, his potassium level had decreased to 2.2 mmol/L (at 01:30).

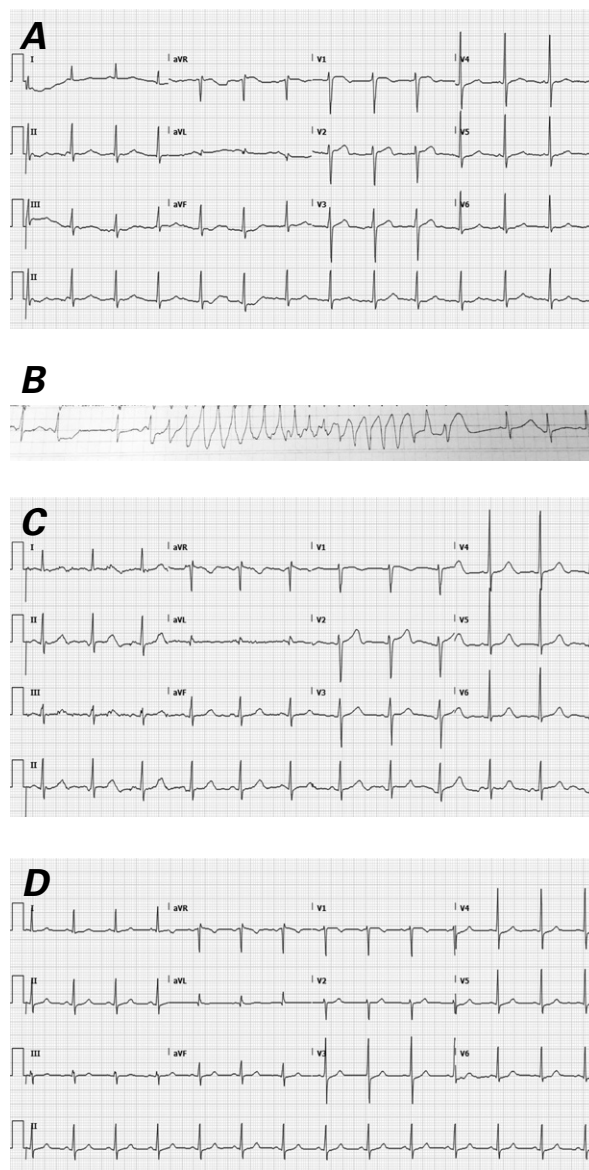
The patient's electrolytes were aggressively replenished, and further QT-prolonging agents were withheld. A TTE showed a normally functioning LV (estimated ejection fraction, 0.50–0.55) and no other abnormalities. Cardiac computed tomographic angiograms revealed no obstructive coronary artery disease and a coronary artery calcium score of 0. One week later, his ECG showed a normal QTc (Fig. 2D). No additional episodes of VT or torsades de pointes were noted. The patient was eventually discharged from the hospital and awaited outpatient evaluation of his chronic diarrhea.

## Discussion

Torsades de pointes, a form of polymorphic VT, was first described in 1966.<sup>5</sup> Usually seen in patients with congenital long QT syndrome or in association with drug therapy, it can cause syncope or sudden cardiac death. The pathophysiologic developmental mechanism for torsades de pointes appears to be related to early afterdepolarizations that generate spontaneously triggered upstrokes. Heterogeneity in action-potential prolongation and early afterdepolarizations within certain populations of cells in the conduction system yield myocardium that is vulnerable to reentrant excitation.<sup>6</sup>

Drugs that prolong the QT interval can cause arrhythmias because they block the inward rectifying potassium channel in the heart, which then produces the early afterdepolarizations implicated in torsades de pointes.<sup>6</sup> The association between noncardiac QT-prolonging drugs and sudden cardiac death is well documented.<sup>7</sup>

Ondansetron prolongs the QT interval in a dose-dependent manner: peak effects occur minutes after administration of the drug has begun.<sup>8–12</sup> GlaxoSmith-Kline, the original marketer of ZOFRAN, conducted a double-blinded placebo- and positive-controlled trial in 58 healthy individuals. Fifteen minutes after intravenous infusions of 8 and 32 mg of ondansetron had begun, the largest differences in QT prolongation versus placebo were as follows: 5.84 ms (90% CI, 3.92–7.76) for 8 mg and 17.94 ms (90% CI, 16.01–19.86) for 32 mg.<sup>8</sup> Ventricular arrhythmias after ondansetron infu-



**Fig. 2** Patient 2. **A)** Baseline electrocardiogram (ECG) shows a normal corrected QT interval (QTc). **B)** Rhythm strip shows torsades de pointes 11 hours after the last dose of ondansetron. **C)** Post-event ECG shows a prolonged QTc (543 ms). **D)** One week later, ECG shows a normal QTc.

sion have been reported.<sup>13,14</sup> In response to the data on the increased risk of QT prolongation, the FDA issued an initial warning about the risk of abnormal heart rhythms after high doses of ondansetron, and then a follow-up warning about the 32-mg single intravenous dose on the basis of the above study.<sup>4,8</sup> The most recent product monograph for ZOFRAN recommends that adults be given an initial intravenous infusion of 8 mg over 15 min, up to a maximum of 16 mg over that time.<sup>15</sup> Because of the dose-dependent risk of QT prolongation, the 16-mg maximum infusion must not be exceeded.<sup>15</sup>

Authors of several meta-analyses have investigated whether routine use of ondansetron is directly associated with ventricular arrhythmias. Tricco and colleagues,<sup>1</sup> who examined 62 studies including 14,705 patients, found no increased risk of cardiac arrhythmia associated with ondansetron therapy. Only 5 of the 62 studies revealed QT prolongation, and none had sudden cardiac death as an outcome. In contrast, Freedman and associates<sup>13</sup> identified 17 adult patients in whom an arrhythmia developed after they were given ondansetron. Four of these instances were torsades de pointes, and 7 others were described as VT, ventricular fibrillation, or “fatal arrhythmia.” Fifteen of the 17 cases had identifiable arrhythmogenic factors, such as electrolyte abnormalities or concomitant QT-prolonging agents; only 2 patients had existing cardiomyopathy. The largest cumulative dose of intravenous ondansetron was 8 mg.

Characteristics known to increase the risk for drug-induced torsades de pointes include female sex, hypokalemia, bradycardia, congestive heart failure, rapid infusion of a QT-prolonging drug, and baseline QT-interval prolongation.<sup>6</sup> Patients with LV systolic dysfunction who were given QT-prolonging antiarrhythmic drugs had an increased susceptibility to QT prolongation.<sup>16</sup> Even though serum levels generally peak 5 minutes after ondansetron is administered,<sup>13</sup> Hafermann and associates<sup>2</sup> showed that heart-failure patients had a mean 20.6-ms increase in the QTc up to 120 min after a mere 4-mg ondansetron infusion.

Ondansetron is effective as an antiemetic and has a relatively favorable safety profile; however, awareness of the distinct risks of its use is warranted. Clear risk factors in Patient 1 were female sex, cardiomyopathy, and a large cumulative dose of intravenous ondansetron within a short time. Patient 2 had metabolic abnormalities (notably, severe hypokalemia), and a total infusion of only 12 mg induced substantial QT prolongation. Of note, neither patient had a known history or clinical evidence of systolic dysfunction, and both of their baseline ECGs showed normal QT intervals.

These cases highlight the importance of caution when infusing successive doses of ondansetron. We advise careful history-taking to identify comorbidities that increase patients’ risk of developing QT prolongation and torsades de pointes from ondansetron. Metabolic abnormalities in patients with active nausea, vomiting, and diarrhea should be anticipated, and metabolic status should be carefully monitored in patients who are given successive doses of ondansetron or other 5-HT<sub>3</sub> antagonist antiemetic agents. A baseline ECG showing a normal QTc does not ensure safe infusion of QT-prolonging agents, particularly in patients with impaired LV systolic function. We therefore advise providers to use caution and to consider obtaining an interim ECG to ascertain that the QTc is stable.

## References

1. Tricco AC, Soobiah C, Blondal E, Veroniki AA, Khan PA, Vafaei A, et al. Comparative safety of serotonin (5-HT<sub>3</sub>) receptor antagonists in patients undergoing surgery: a systematic review and network meta-analysis. *BMC Med* 2015;13:142.
2. Hafermann MJ, Namdar R, Seibold GE, Page RL 2nd. Effect of intravenous ondansetron on QT interval prolongation in patients with cardiovascular disease and additional risk factors for torsades: a prospective, observational study. *Drug Healthc Patient Saf* 2011;3:53-8.
3. Tay KY, Ewald MB, Bourgeois FT. Use of QT-prolonging medications in US emergency departments, 1995-2009. *Pharmacoepidemiol Drug Saf* 2014;23(1):9-17.
4. U.S. Food and Drug Administration. FDA Drug Safety Communication: new information regarding QT prolongation with ondansetron (Zofran). Available from: <https://www.fda.gov/Drugs/DrugSafety/ucm310190.htm> [2011 Sep 15; updated 2012 Jun 29; cited 2017 Sep 19].
5. Dessertenne F. La tachycardie ventriculaire à deux foyers opposés variables [in French]. *Arch Mal Coeur Vaiss* 1966;59(2):263-72.
6. Roden DM. Drug-induced prolongation of the QT interval. *N Engl J Med* 2004;350(10):1013-22.
7. Straus SM, Sturkenboom MC, Bleumink GS, Dieleman JP, van der Lei J, de Graeff PA, et al. Non-cardiac QTc-prolonging drugs and the risk of sudden cardiac death. *Eur Heart J* 2005;26(19):2007-12.
8. GlaxoSmithKline. A randomized, double-blind, four-period crossover study to investigate the effect of intravenous ondansetron, a 5-HT<sub>3</sub> antagonist, on cardiac conduction as compared to placebo and moxifloxacin in healthy adult subjects. Available from: <http://www.gsk-clinicalstudyregister.com/study/115458#rs> [2011 Dec; cited 2015 Aug 24].
9. Benedict CR, Arbogast R, Martin L, Patton L, Morrill B, Hahne W. Single-blind study of the effects of intravenous dolasetron mesylate versus ondansetron on electrocardiographic parameters in normal volunteers. *J Cardiovasc Pharmacol* 1996;28(1):53-9.
10. Charbit B, Albaladejo P, Funck-Brentano C, Legrand M, Samain E, Marty J. Prolongation of QTc interval after post-operative nausea and vomiting treatment by droperidol or ondansetron. *Anesthesiology* 2005;102(6):1094-100.
11. Gupta SD, Pal R, Sarkar A, Mukherjee S, Mitra K, Roy S, et al. Evaluation of ondansetron-induced QT interval prolongation in the prophylaxis of postoperative emesis. *J Nat Sci Biol Med* 2011;2(1):119-24.
12. Ganjare A, Kulkarni AP. Comparative electrocardiographic effects of intravenous ondansetron and granisetron in patients undergoing surgery for carcinoma breast: a prospective single-blind randomised trial. *Indian J Anaesth* 2013;57(1):41-5.
13. Freedman SB, Uleryk E, Rumantir M, Finkelstein Y. Ondansetron and the risk of cardiac arrhythmias: a systematic review and postmarketing analysis. *Ann Emerg Med* 2014;64(1):19-25.e6.
14. Ballard HS, Bottino G, Bottino J. Ondansetron and chest pain. *Lancet* 1992;340(8827):1107.
15. Novartis Pharmaceuticals Canada, Inc. Product monograph: Zofran tablets, oral solution and injection. Available from: <https://www.novartis.ca/en/our-products/pharmaceuticals/ui-id-1=21> [updated 2016 Jan 14; cited 2017 Sep 19].
16. Tisdale JE, Overholser BR, Wroblewski HA, Sowinski KM, Amankwa K, Borzak S, et al. Enhanced sensitivity to drug-induced QT interval lengthening in patients with heart failure due to left ventricular systolic dysfunction. *J Clin Pharmacol* 2012;52(9):1296-305.