

Surgical Treatment of Constrictive Pericarditis

Burak Can Depboylu, MD
Parmeseven Mootoosamy,
MD
Nicola Vistarini, MD
Ariane Testuz, MD
Ismail El-Hamamsy, MD, PhD
Mustafa Cikirikcioglu, MD,
PhD

Constrictive pericarditis is the final stage of a chronic inflammatory process characterized by fibrous thickening and calcification of the pericardium that impairs diastolic filling, reduces cardiac output, and ultimately leads to heart failure.

Transthoracic echocardiography, computed tomography, and cardiac magnetic resonance imaging each can reveal severe diastolic dysfunction and increased pericardial thickness. Cardiac catheterization can help to confirm a diagnosis of diastolic dysfunction secondary to pericardial constriction, and to exclude restrictive cardiomyopathy.

Early pericardiectomy with complete decortication (if technically feasible) provides good symptomatic relief and is the treatment of choice for constrictive pericarditis, before severe constriction and myocardial atrophy occur.

We describe our surgical approach to constrictive pericarditis, summarize our results in 93 patients, and provide a brief overview of the literature. (Tex Heart Inst J 2017;44(2): 101-6)

Key words: Cardiac surgical procedures/methods; pericarditis/diagnosis/etiology; pericardiectomy/methods/mortality; pericarditis, constrictive/complications/diagnostic imaging/etiology/physiopathology/surgery; pericardium/pathology; survival rates/trends; treatment outcome

From: Departments of Cardiovascular Surgery (Drs. Depboylu and Mootoosamy) and Cardiology (Dr. Testuz), Geneva University Hospitals and Faculty of Medicine, CH-1211 Geneva, Switzerland; and Department of Cardiac Surgery (Drs. Cikirikcioglu, El-Hamamsy, and Vistarini), Montréal Heart Institute, Université de Montréal, Montréal, Québec H1T 1C8, Canada

Dr. Cikirikcioglu is now at the Department of Cardiovascular Surgery, Geneva University Hospitals and Faculty of Medicine, Geneva, Switzerland.

Address for reprints:
 Burak Can Depboylu, MD,
 Department of Cardiovascular Surgery, Mugla Sitki Kocman University, Orhaniye Mah. Haluk Ozsoy Cad., 48000 Mugla, Turkey

E-mail: burakdepboylu@yahoo.com

© 2017 by the Texas Heart® Institute, Houston

The normal pericardium consists of 2 layers: a fibrous outer layer and a serous inner layer. The pericardial space is enclosed within these 2 layers and normally contains 20 to 50 mL of serous fluid. The pericardium serves a variety of functions. In addition to its mechanical effects on the heart (limiting distention, promoting chamber-coupling interaction, maintaining cardiac geometry, enabling frictionless movement, and serving as a barrier to infection), the pericardium has immunologic, vasomotor, paracrine, and fibrinolytic activities.¹

Inflammation of the pericardium, or pericarditis, can be caused by many factors. Constrictive pericarditis (CP) is the result of chronic scarring and eventual inelasticity of the pericardial sac, leading to heart failure.^{2,3} At present, idiopathic or viral pericarditis is the predominant cause of CP in the Western world, followed by post-cardiotomy irritation and mediastinal irradiation.^{2,7} Tuberculosis is still a cause of pericarditis in developing countries and in immunosuppressed patients.^{2,7} Most of the conditions listed in Table I can cause constrictive pericardial syndromes.

Clinical symptoms of CP arise from fluid overload and diminished cardiac output. Physical findings can include distended jugular veins secondary to high venous pressure, Beck's triad (hypotension, pulsus paradoxus, and muffled heart sounds), the Kussmaul sign, a pericardial knock, edema, ascites, or cachexia.

The initial diagnostic methods include electrocardiography, chest radiography, and echocardiography. The well-known sign of CP on an electrocardiogram is the reduction of voltages in all traces, and chest radiographs might well show calcifications. Transthoracic echocardiography is the most useful initial investigative method for patients with suspected CP. Characteristic echocardiographic (and hemodynamic) findings observed in the presence of CP are due to 2 physiopathologic phenomena: ventricular interdependence because the heart is confined within a rigid pericardium, and loss of transmission through the pericardium of intrathoracic pressure variations with breathing. Under normal conditions, the drop in intrathoracic pressure with inspiration is transmitted from the pulmonary veins to the left atrium, thus leading to a favorable diastolic filling pressure gradient of the left ventricle (LV). In the presence of CP, this pressure drop is not transmitted to the left atrium, and the early filling of the LV is impaired (>25% respiratory variation of E wave). As a consequence of this and of ventricular interdependence, the volume of the right ventricle (RV) is increased (septal bounce, or protodiastolic shift of the interventricular septum). Other echocardiographic signs are a restrictive LV filling pattern (E/A >1.5; short deceleration time, <160 ms), normal or even supranormal mitral annular velocities (e' >7 cm/s, septal > lateral on tissue-Doppler imaging), and expiratory diastolic flow reversal of

TABLE I. Causes of Constrictive Pericarditis

| |
|--|
| Irradiation |
| Postcardiotomy |
| Infectious |
| Viral |
| Echovirus |
| Coxsackie virus |
| Adenovirus |
| Cytomegalovirus |
| Hepatitis B |
| Mononucleosis |
| HIV/AIDS |
| Bacterial |
| Pneumococcus |
| Staphylococcus |
| Streptococcus |
| Mycoplasma |
| Lyme disease |
| <i>Haemophilus influenzae</i> |
| <i>Neisseria meningitides</i> |
| Others |
| Mycobacterial |
| Mycobacterium tuberculosis |
| <i>M. avium-intracellulare</i> complex |
| Fungal |
| Histoplasmosis |
| Coccidioidomycosis |
| Protozoal |
| Neoplastic |
| Connective-tissue disorders |
| Systemic lupus erythematosus |
| Rheumatoid arthritis |
| Scleroderma |
| Dermatomyositis |
| Sjögren syndrome |
| Mixed |
| Uremic disease |
| Trauma |
| Sarcoidosis |
| Drugs |
| Procainamide |
| Hydralazine |
| Isoniazid |
| Cyclosporine |
| Implantable cardioverter-defibrillator patches |

AIDS = acquired immunodeficiency syndrome; HIV = human immunodeficiency virus

hepatic veins, with no respiratory variation of a dilated inferior vena cava (Fig. 1).⁷⁻⁹ The results of invasive hemodynamic evaluation during cardiac catheterization can confirm the diagnosis, and simultaneous coronary angiography can define the patient's coronary anatomy before possible surgical intervention. In patients with CP, the typical findings on cardiac catheterization include increased atrial pressure with prominent x and y descents, equalization of end-diastolic pressures in the chambers, a dip-and-plateau or square-root sign of ventricular diastolic pressure, and opposing changes in LV

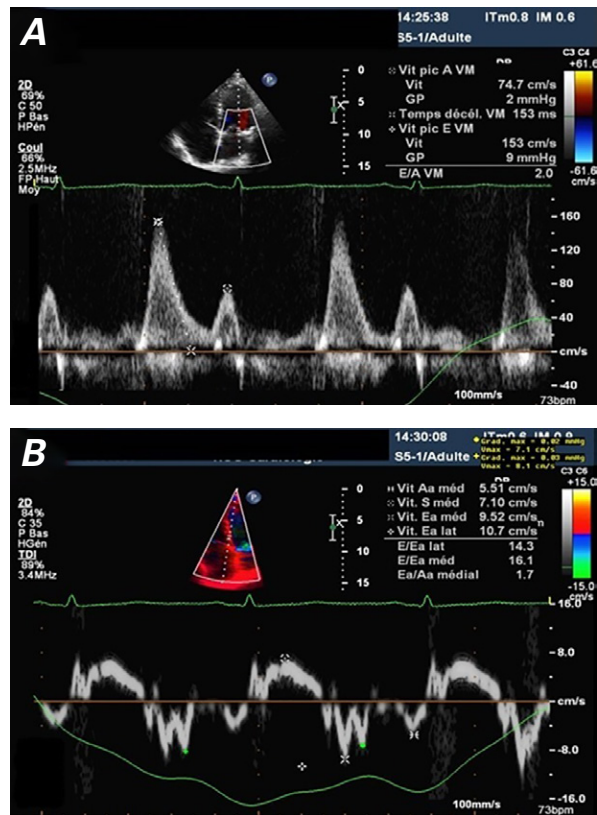


Fig. 1 Mitral Doppler echocardiograms show signs of constrictive pericarditis: **A**) restrictive filling ($E/A > 1.5$; short deceleration time) and **B**) normal annular velocity ($e' > 7$ cm/s, but in this case lateral $>$ septal).

and RV filling and systolic pressures with ventilation (Fig. 2).⁹ In patients under evaluation for pericardiectomy, particularly those with prior radiation exposure, computed tomographic (CT) or cardiac magnetic resonance (CMR) imaging provides additional information about the extent of pericardial thickening, calcification, and scarring.⁹

Constrictive pericarditis has a progressive but variable course. For most patients, pericardiectomy is the definitive treatment with an operative risk of 5% to 10% and a late mortality rate of 15% to 70%, depending on several factors.¹⁰ Healthy older patients with mild constriction can be managed conservatively with diuretics.¹⁰

Surgical Technique

The patient is fully monitored in order to evaluate the hemodynamic impact of the pericardiectomy intraoperatively. Pericardiectomy can be performed through either a median sternotomy or a left anterolateral thoracotomy. Median sternotomy provides good access to the right ventricle, right atrium, and great vessels, including the caval-right atrial junctions, thus enabling a good clearance of the diseased pericardium from phrenic nerve to phrenic nerve. The left anterior thoracotomy is preferred mainly for infected-purulent pericarditis, in

order to avoid sternal infections postoperatively. Femoral access sites are kept open.

The patient is prepared and draped in the standard manner for cardiac surgery, with the groins available if emergency cardiopulmonary bypass (CPB) should become necessary. We do not use CPB systematically, except in cases of postcardiotomy CP. In the latter situation, the femoral vessels are prepared or cannulated before chest opening (depending on the degree of the retrosternal postoperative adhesions, the proximity of the cardiac structures to the sternum, the degree of the cardiac failure, and the necessity of additional cardiac interventions) (Fig. 3).

The conventional approach is to decorticate the LV before the RV, to avoid pulmonary edema. However, this is not always easy to perform on a beating heart. Thus, we free the right side first. After freeing the mid-anterior part, we proceed with dissection laterally, to both right and left sides.

The dissection begins in the midline by using sharp and blunt dissection techniques. During that stage, our aim is to cautiously find a dissection plane between the

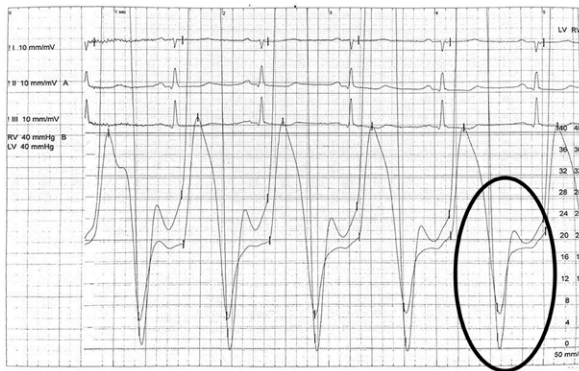

Fig. 2 Invasive pressure measurement shows simultaneous left and right ventricular tracings. A rapid fall in biventricular pressure in protodiastole is followed by a rapid increase of biventricular pressures during diastole, until they equalize. Then filling suddenly stops because of constriction, creating a dip-and-plateau morphology (oval).

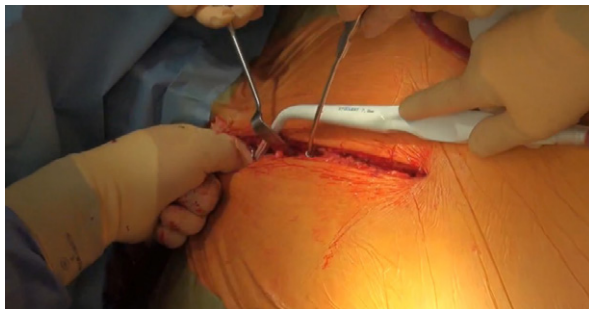


Fig. 3 Intraoperative photograph shows the median sternotomy. Supplemental motion image is available for [Figure 3](#).

epicardium and the fibrotic-constricted parietal pericardium by paying attention to the coronary arteries. The arteries should be visible for the purposes both of avoiding them and of ensuring that the depth of the dissection plane is adequate (Fig. 4).

When access to the correct dissection plane is attained, better diastolic relaxation of the heart is observed after removal of the fibrotic parietal pericardium (Fig. 5). There is instant hemodynamic relief.

The dissection is then continued between the pericardium, the left and the right ventricular walls, and the left and right atrial walls, in order to resect all stiff pericardial tissues. The lateral extensions of the dissection planes are approximately 1 cm anterior to the right and left phrenic nerves. Dissection lateral to the main pulmonary artery is usually unnecessary, and avoiding such dissection avoids potential injury to the phrenic nerves at this location. Occasionally, very thick localized

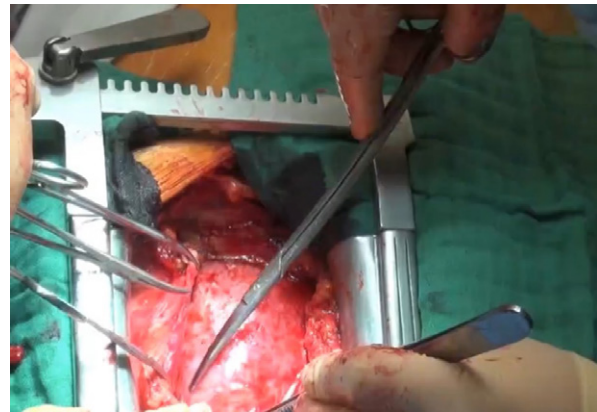


Fig. 4 Intraoperative photograph shows the anterior mediastinal dissection, blunt-sharp and swab-assisted dissection, and extension of the dissection plane laterally. Both pleural spaces are entered to view the phrenic nerves and to drain any pleural effusions.

Supplemental motion image is available for [Figure 4](#).

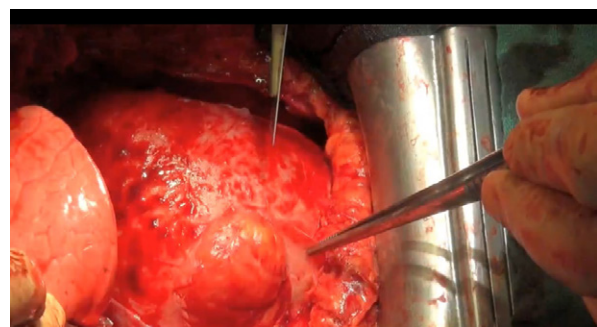


Fig. 5 Intraoperative photograph shows better diastolic relaxation of the heart after removal of the fibrotic parietal pericardium.

Supplemental motion image is available for [Figure 5](#).

adhesions are encountered and are especially difficult to remove. In these instances, the adhesions should be left untreated to prevent inadvertent injury to the underlying cardiac chambers. All local, small instances of bleeding are dealt with immediately (Fig. 6). The waffle procedure, in which multiple transverse and longitudinal incisions are made in the epicardial layer, is another alternative in patients with extensive epicardial involvement.¹¹

After complete pericardiectomy, hemostasis is achieved, thoracic drains are inserted, and the heart is wrapped with adhesion-barrier film. Checking the echocardiographic and hemodynamic values (improved RV and LV filling pressures, increased mitral inflow, and decreased tricuspid velocities with inspiration) concludes the operation (Fig. 7).

Clinical Experience. Over a 20-year period at the Montréal Heart Institute, 99 patients with CP have undergone pericardiectomy.¹² Of these patients, 93 underwent

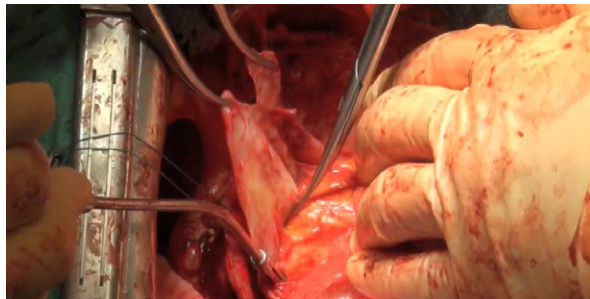


Fig. 6 Intraoperative photograph shows the lateral and inferior extension of the dissection planes and control of local, small bleeding.

Supplemental motion image is available for [Figure 6](#).

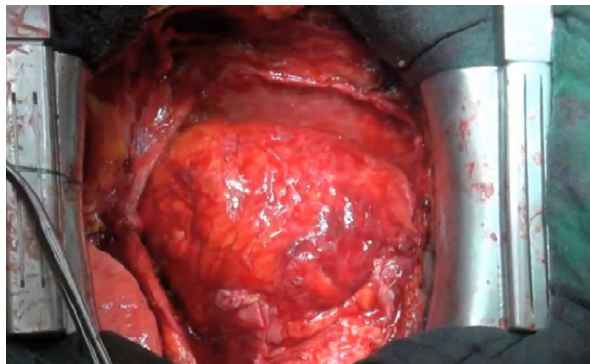


Fig. 7 Final operative photograph shows the heart at the end of the pericardiectomy, with the pericardium removed. The mediastinal and both thoracic drains are inserted, and the heart is wrapped, in good hemodynamic condition, with adhesion-barrier film.

Supplemental motion image is available for [Figure 7](#).

sternotomy, as described here. The cause of the pericarditis was idiopathic in 61%, postcardiotomy syndrome in 14%, infection in 14%, post-irradiation in 2%, and miscellaneous in the remaining 9%. The duration of symptoms was less than 6 months in 46% of cases. Seventy percent of patients had a preoperative functional status of New York Heart Association (NYHA) class III or IV. Seventy-one percent of patients had normal LV function (ejection fraction, ≥ 0.50). Pericardial calcifications were present preoperatively in 62% of cases. Surgery was performed on a beating heart in 61% of patients, whereas CPB was necessary in the remaining cases (39%), mostly because of concomitant cardiac operations (33%). The hospital mortality rate was 8.6% ($n=8$). The causes of death were multiorgan failure ($n=4$), cardiac failure ($n=2$), and respiratory insufficiency ($n=2$). The long-term clinical outcome was satisfactory, with 79% of patients in NYHA class I or II. The overall survival rate was 87% at 5 years and 78% at 10 years.

Discussion

Pericardiectomy for CP was first successfully performed in 1913 by the German surgeon Ludwig Rehn^{13,14} and has subsequently been regarded as a curative rather than a palliative procedure. However, it is not recommended during very early constriction or in severe advanced disease (NYHA class IV), when the risks of surgery—with a mortality rate of 30% to 40%—outweigh the benefits.

Multimodal imaging—including echocardiography, CT, and CMR—might provide valuable aid for determining definite diagnosis and cause. The clinician should distinguish CP from restrictive cardiomyopathy. The latter has led to a significant false-positive diagnosis rate and inappropriate cardiac surgery.¹⁵ In fact, as for CP, restrictive cardiomyopathy is suspected in cases of heart failure with a preserved ejection fraction and with a restrictive LV filling pattern on echocardiographic examination. In restrictive cardiomyopathy, however, there is no septal bounce and no exaggerated respiratory variation of transvalvular or hepatic vein on Doppler imaging—rather, there are diminished mitral annular velocities on tissue-Doppler imaging.⁸ Echocardiography thus provides valuable tools to distinguish the 2 diagnostic entities, but because signs are not constant, and the clinical, echocardiographic, and invasive hemodynamic pictures are not always concordant, it is sometimes challenging to reach the correct diagnosis. Combining the diagnostic methods is thus often helpful, so that when additional comprehensive pericardial and cardiovascular anatomic studies, as well as tissue characterizations, become necessary, CT or CMR can provide further information. Because CMR can evaluate ongoing pericardial inflammation, and CT can

evaluate pericardial calcification and associated or extracardiac diseases, both CMR and CT are particularly helpful in planning surgical intervention.⁹

Different surgical approaches and techniques, especially median sternotomy versus lateral thoracotomy, partial versus total pericardiectomy, and the need for CPB continue to be debated.^{4,6,10,16} Generally, the median sternotomy approach enables a more radical clearance of pericardium overlying the right atrium and venae cavae.^{17,18} The left anterolateral thoracotomy approach should be preferred in cases of purulent pericarditis and effusive-constricted pericarditis because of concomitant pyothorax and the risk of sternal infection.

Cardiopulmonary bypass is a useful adjunct in patients with inadvertent cardiac injury or catastrophic bleeding, and in patients with previous partial pericardiectomy or cardiac surgery, with massive calcifications, or with concomitant cardiac surgical procedures.^{19,20} In a series performed at Cleveland Clinic,²¹ 30 patients (18.4%) underwent an on-pump pericardiectomy. In our series, surgery was performed on the beating heart in 61% of the patients, and CPB was necessary in the remaining cases (39%). This higher percentage was mainly because of the high rate of concomitant cardiac operations (in 33% of patients).

Surgical removal of the pericardium is associated with a non-negligible operative mortality rate of 5% to 10% in various large series. The operative mortality rate strongly correlates with the preoperative NYHA class.¹⁰ The operative mortality rate also varies widely in accordance with cause. Bertog and colleagues²¹ assumed that the higher mortality rate associated with pericardiectomy for post-irradiation (21.4%) and postcardiotomy CP (8.3%) is related to the fact that constriction is not the sole factor producing heart failure in these subgroups. Myocardial atrophy after prolonged constriction, residual constriction, or a concomitant myocardial process can lead to prolonged cardiac failure despite successful pericardiectomy. It bears repeating that our hospital mortality rate was 8.6% (n=8). The causes of death were multiorgan failure (4), cardiac failure (2), and respiratory insufficiency (2).

Despite reduced perioperative mortality rates, the late survival rate of our current patients after pericardiectomy is inferior to that of an age- and sex-matched group of historical control subjects.²² An important predictor of prognosis is the cause of the pericardial disease. Indeed, idiopathic CP had the best prognosis, with a 7-year Kaplan-Meier survival rate of 88%, followed by postsurgical CP with 66%, and post-irradiation CP with 27%.¹⁰ In a logistic regression analysis, the long-term outcome was predicted by advanced age, increased NYHA class, and post-irradiation exposure.²³ In another study, age, renal failure, pulmonary hypertension, LV dysfunction, and hyponatremia were independent adverse predictors.²¹ In the 2 series of Cleveland Clinic²¹ and Mayo Clinic²²

patients, 70% to 80% of patients were free of adverse cardiovascular events at 5 years after pericardiectomy, and 40% to 50% at 10 years. According to a report from Tehran University of Medical Science,²³ 44 of 45 patients were in NYHA class I or II after a mean follow-up period of 40 months. On the basis of echocardiographic indices, LV diastolic function returns to normal early after pericardiectomy in approximately 40% of patients, and late after pericardiectomy in almost 60%.²⁴ Persistence of abnormal filling is correlated with postoperative symptoms.

Pericardial calcification had no impact on survival rates. Delayed or inadequate responses to pericardiectomy have been attributed to longstanding disease with myocardial atrophy or fibrosis, incomplete resection, and the development of recurrent cardiac compression by mediastinal inflammation and fibrosis. In the Montréal Heart Institute series,¹² long-term clinical outcomes were satisfactory, with 79% of patients in NYHA class I or II. Overall actuarial survival rates at 5 and 10 years were 87% and 78%, respectively.

In conclusion, pericardiectomy is indicated once the diagnosis of CP is made, because of the hazard associated with the chronicity of the disease. Early intervention in patients with favorable functional status is recommended to improve early and late survival and functional outcomes.

Acknowledgments

We thank Mr. Stephane Hertig (Department of Surgery, University Hospitals of Geneva, Geneva, Switzerland) for his technical assistance during the preparation of surgical videos, and Dr. Stephane Noble (Department of Cardiology, University Hospitals of Geneva) for his collaboration in obtaining hemodynamic figures.

References

1. Shabetai R. The pericardium. Norwell (MA): Kluwer Academic Publishers; 2003. p. 1-50.
2. Maisch B, Seferovic PM, Ristic AD, Erbel R, Rienmuller R, Adler Y, et al. Guidelines on the diagnosis and management of pericardial diseases executive summary; the task force on the diagnosis and management of pericardial diseases of the European Society of Cardiology. *Eur Heart J* 2004;25(7):587-610.
3. Clare GC, Troughton RW. Management of constrictive pericarditis in the 21st century. *Curr Treat Options Cardiovasc Med* 2007;9(6):436-42.
4. Tokuta Y, Miyata H, Motomura N, Araki Y, Oshima H, Usui A, et al. Outcome of pericardiectomy for constrictive pericarditis in Japan: a nationwide outcome study. *Ann Thorac Surg* 2013;96(2):571-6.
5. Lin Y, Zhou M, Xiao J, Wang B, Wang Z. Treating constrictive pericarditis in a Chinese single-center study: a five-year experience. *Ann Thorac Surg* 2012;94(4):1235-40.
6. Chowdhury UK, Subramaniam GK, Kumar AS, Airan B, Singh R, Talwar S, et al. Pericardiectomy for constrictive pericarditis: a clinical, echocardiographic, and hemodynamic

- evaluation of two surgical techniques. *Ann Thorac Surg* 2006;81(2):522-9.
7. Seidler S, Lebowitz D, Muller H. Chronic constrictive pericarditis [in French]. *Rev Med Suisse* 2015;11(476):1166, 1168-71.
 8. Nagueh SF, Appleton CP, Gillebert TC, Marino PN, Oh JK, Smiseth OA, et al. Recommendations for the evaluation of left ventricular diastolic function by echocardiography. *Eur J Echocardiogr* 2009;10(2):165-93.
 9. Syed FF, Schaff HV, Oh JK. Constrictive pericarditis—a curable diastolic heart failure [published erratum appears in *Nat Rev Cardiol* 2015;12(12):682]. *Nat Rev Cardiol* 2014;11(9):530-44.
 10. Szabo G, Schmack B, Bulut C, Soos P, Weymann A, Stadfeld S, Karck M. Constrictive pericarditis: risks, aetiologies and outcomes after total pericardiectomy: 24 years of experience. *Eur J Cardiothoracic Surg* 2013;44(6):1023-8.
 11. Matsuura K, Mogi K, Takahara Y. Off-pump waffle procedure using an ultrasonic scalpel for constrictive pericarditis. *Eur J Cardiothorac Surg* 2015;47(5):e220-2.
 12. Vistarini N, Chen C, Mazine A, Bouchard D, Hebert Y, Carrier M, et al. Pericardiectomy for constrictive pericarditis: 20 years of experience at the Montreal Heart Institute. *Ann Thorac Surg* 2015;100(1):107-13.
 13. Shumacker HB Jr. The evolution of cardiac surgery. Bloomington (IN): Indiana University Press; 1992. p. 18.
 14. Diethrich EB, Tolls R. Bone around the heart: presentation of a case of chronic constrictive pericarditis and review of recent surgical literature. *Cardiovasc Dis* 1977;4(1):37-48.
 15. Seifert FC, Miller DC, Oesterle SN, Oyer PE, Stinson EB, Shumway NE. Surgical treatment of constrictive pericarditis: analysis of outcome and diagnostic error. *Circulation* 1985;72(3 Pt 2):II264-73.
 16. George TJ, Arnaoutakis GJ, Beaty CA, Kilic A, Baumgartner WA, Conte JV. Contemporary etiologies, risk factors, and outcomes after pericardiectomy. *Ann Thorac Surg* 2012;94(2):445-51.
 17. Talreja DR, Edwards WD, Danielson GK, Schaff HV, Tajik AJ, Tazelaar HD, et al. Constrictive pericarditis in 26 patients with histologically normal pericardial thickness. *Circulation* 2003;108(15):1852-7.
 18. Gopaldas RR, Dao TK, Caron NR, Markley JG. Predictors of in-hospital complications after pericardiectomy: a nationwide outcomes study. *J Thorac Cardiovasc Surg* 2013;145(5):1227-33.
 19. Villavicencio MA, Dearani JA, Sundt TM 3rd. Pericardiectomy for constrictive or recurrent inflammatory pericarditis. *Oper Tech Thorac Cardiovasc Surg* 2008;13(1):2-13.
 20. Chowdhury UK, Seth S, Reddy SM. Pericardiectomy for chronic constrictive pericarditis via left anterolateral thoracotomy. *Oper Tech Thorac Cardiovasc Surg* 2008;13(1):14-25.
 21. Bertog SC, Thambidorai SK, Parakh K, Schoenhagen P, Ozduran V, Houghtaling PL, et al. Constrictive pericarditis: etiology and cause-specific survival after pericardiectomy. *J Am Coll Cardiol* 2004;43(8):1445-52.
 22. Ling LH, Oh JK, Schaff HV, Danielson GK, Mahoney DW, Seward JB, Tajik AJ. Constrictive pericarditis in the modern era: evolving clinical spectrum and impact on outcome after pericardiectomy. *Circulation* 1999;100(13):1380-6.
 23. Goland S, Caspi A, Malnick SD. Idiopathic chronic pericardial effusion. *N Engl J Med* 2000;342(19):1449-50.
 24. Ghavidel AA, Gholampour M, Kyavar M, Mirmeshdagh Y, Tabatabaie MB. Constrictive pericarditis treated by surgery. *Tex Heart Inst J* 2012;39(2):199-205.