

# An Unusual Presentation of QT Prolongation

Mohammad Khalid  
Mojadidi, MD  
Ninel Hovnanians, MD  
Michael R. Kaufmann, MD  
James A. Hill, MD, FACC

**A** 55-year-old woman with a history of chronic bronchitis, *Clostridium difficile* colitis, and alcohol and tobacco abuse was admitted with altered mentation, hyponatremia, and necrotizing right-upper-lobe pneumonia. She was started on cefepime and vancomycin; metronidazole was added for colitis. A resting electrocardiogram (ECG) showed sinus tachycardia with a QS pattern in the precordial leads, normal intervals, and small T-wave inversions in leads V<sub>5</sub> and V<sub>6</sub>. Four days later, significant changes in her baseline telemetry rhythm prompted a repeat 12-lead ECG; the patient's pulse rate was 75 beats/min with a QT interval of 720 ms and QTc of 746 ms (Fig. 1). Her troponin T level was <0.03 ng/mL, and she had no new symptoms. Her medications at that time were aspirin, metoprolol, lisinopril, cefepime, atorvastatin, pantoprazole, metronidazole, oral vancomycin, and subcutaneous heparin. Her potassium level was 2.9 mEq/L, and her magnesium level was 1.6 mEq/L. An echocardiogram showed severe left ventricular dysfunction with wall motion that suggested stress-induced cardiomyopathy.

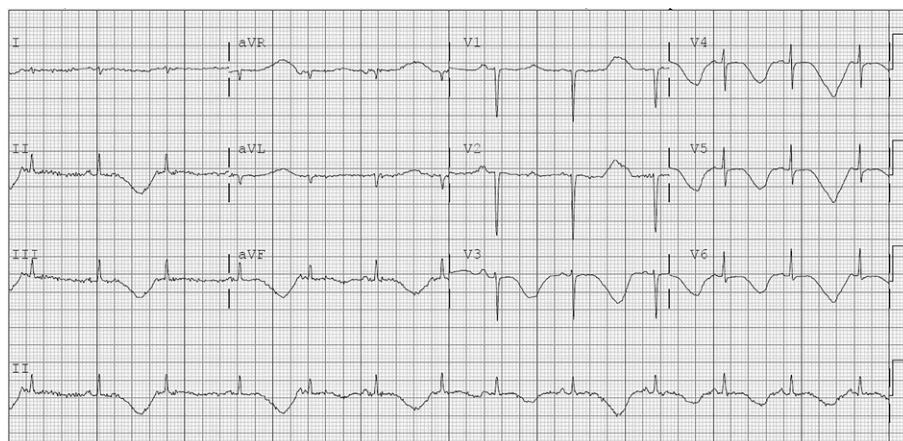


Fig. 1

**Section Editors:**  
Yochai Birnbaum, MD  
Mohammad Saeed, MD  
James M. Wilson, MD

**From:** Department of  
Cardiology, University of  
Florida College of Medicine;  
Gainesville, Florida 32611

**Address for reprints:**  
Ninel Hovnanians, MD,  
Jacobi Medical Center,  
Albert Einstein College  
of Medicine,  
1400 Pelham Pkwy. S.,  
Bronx, NY 10461

**E-mail:** nhovnanian@yahoo.  
com

© 2016 by the Texas Heart®  
Institute, Houston

**What is the likely cause of these new ECG findings?**

See next page for the answer, as well as a link to the Focus on ECGs blog, where you can participate in a moderated discussion.

# FOCUS ON ECGs: ANSWER #4

## Answer

Macroscopic T-wave alternans refers to beat-to-beat variability in the vector and/or amplitude of T waves on a surface ECG (Fig. 2, arrows); it indicates temporal heterogeneity or dispersion in ventricular repolarization, which is an important mechanism underlying reentrant arrhythmias. This finding is usually associated with acquired long QT syndrome and is a sign of electrical instability.<sup>1</sup>

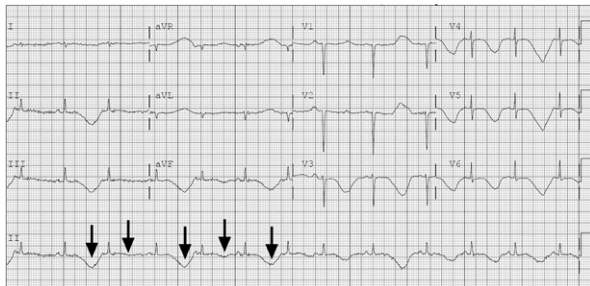


Fig. 2

In our patient, the cause of QT prolongation with T-wave alternans was most likely multifactorial from hypokalemia, stress-induced cardiomyopathy, hypomagnesemia, and the initiation of a new QT-prolonging medication (metronidazole). The association of macroscopic T-wave alternans with stress-induced cardiomyopathy, which has been described previously, might have contributed to the observed repolarization abnormalities in this case.

Our patient's QT prolongation and T-wave alternans persisted after immediately correcting the hypokalemia and then improved after stopping the QT-prolonging medications (metronidazole and pantoprazole).<sup>2,3</sup> A repeat echocardiogram showed improved left ventricular function, and the patient was discharged from the hospital without an implantable cardioverter-defibrillator. To our knowledge, this is the 2nd reported case of QT prolongation with macroscopic T-wave alternans in the presence of stress-induced cardiomyopathy.<sup>4</sup>

T-wave alternans associated with significant QT prolongation on a surface ECG is a sign of severe electrical instability and impending malignant ventricular arrhythmia. QT-prolonging medications and electrolyte abnormalities should always be considered as causes of this rare ECG finding. The treatment is to stop the offending medications, correct the electrolyte abnormalities, and provide close monitoring and supportive care.

## References

1. Nieminen T, Verrier RL. Usefulness of T-wave alternans in sudden death risk stratification and guiding medical therapy. *Ann Noninvasive Electrocardiol* 2010;15(3):276-88.
2. Cohen O, Saar N, Swartzon M, Kliuk-Ben-Bassat O, Justo D. First report of metronidazole-induced QT interval prolongation. *Int J Antimicrob Agents* 2008;31(2):180-1.
3. Bibawy JN, Parikh V, Wahba J, Barsoum EA, Lafferty J, Kowalski M, Bekheit S. Pantoprazole (proton pump inhibitor) contributing to Torsades de Pointes storm. *Circ Arrhythm Electrophysiol* 2013;6(2):e17-9.
4. Warraich HJ, Buxton AE, Kociol RD. Macroscopic T-wave alternans in a patient with takotsubo cardiomyopathy and QT prolongation. *Heart Rhythm* 2014;11(10):1848-9.

*To participate in a moderated discussion of this case, go to [THIJournal.blogspot.com](http://THIJournal.blogspot.com). Two weeks from the original posting date, the discussion will close, but the comments will remain online for reference.*