

# Alternative Surgical Approach to Repairing a Giant Sinus of Valsalva Aneurysm

Vincenzo Giamb Bruno, MD  
Cristina Cucchi etti, BA  
Calogera Pisano, MD  
Jonathan Hyde, MD

We report our method of surgically repairing an unruptured giant aneurysm of the right coronary sinus of Valsalva, a lesion that caused moderate aortic regurgitation but no symptoms in a 61-year-old woman. We excised the aneurysm, reconstructed the right sinus of Valsalva with use of a patch, performed mechanical aortic valve replacement directly through the excised aneurysm's cavity, and constructed a single bypass graft to the right coronary artery. The patient was discharged from the hospital after 5 days. Twelve months postoperatively, her clinical and echocardiographic results were normal, and she was doing well. To our knowledge, our surgical approach to this repair has not been described previously. (*Tex Heart Inst J* 2016;43(1):43-5)

**S**inus of Valsalva aneurysm (SVA), a rare cardiac anomaly, can be acquired or congenital.<sup>1</sup> Ruptured SVAs have been more amenable to diagnosis in the past; moreover, modern imaging techniques have enabled easier detection of unruptured SVAs. We describe our apparently unique surgical approach to the repair of a giant, unruptured right SVA that caused aortic regurgitation in an asymptomatic patient.

## Case Report

In January 2014, a 61-year-old woman was referred to our institution after a cardiac murmur was detected at a routine medical check-up. The patient was asymptomatic and otherwise well. Transthoracic echocardiograms showed a trileaflet aortic valve and a giant aneurysm of the right sinus of Valsalva. Color-flow Doppler mode indicated moderate aortic regurgitation. The patient's left ventricular function was normal, and no other abnormalities were detected.

A thoracic computed tomogram (CT) showed a 5.9 × 5.6-cm aneurysm of the right sinus of Valsalva (Fig. 1). A CT coronary angiogram revealed no significant disease of the coronary tree. The patient was taken for surgical repair of the SVA.

## Surgical Technique

After median sternotomy was performed, we evaluated the aneurysm; the right coronary artery (RCA) ran across its surface (Fig. 2). We established routine cardiopulmonary bypass and opened the aneurysm directly. The thin-walled SVA extended into the aortic annulus, creating annular dilation and distortion that caused aortic regurgitation. We decided to replace the aortic valve, because the patch and new aorta would involve the aortic annulus and valve, and the annulus appeared to be distorted. After the aneurysm was dissected, the native aortic valve was easily excised; we replaced it with a mechanical valve prosthesis directly through the aortic defect. We fashioned an extracellular matrix patch and sutured it into place, incorporating the sewing ring of the prosthetic valve and the edges of the aortic defect. We then grafted the saphenous vein to the RCA proximally.

The patient was discharged from the hospital after 5 uneventful days. Histopathologic and microbiological examination of the wall of the SVA yielded no specific pathologic conditions or infective processes.

**Key words:** Aortic aneurysm/diagnosis/surgery; heart valve prosthesis implantation; sinus of Valsalva/pathology/surgery; surgical techniques; treatment outcome

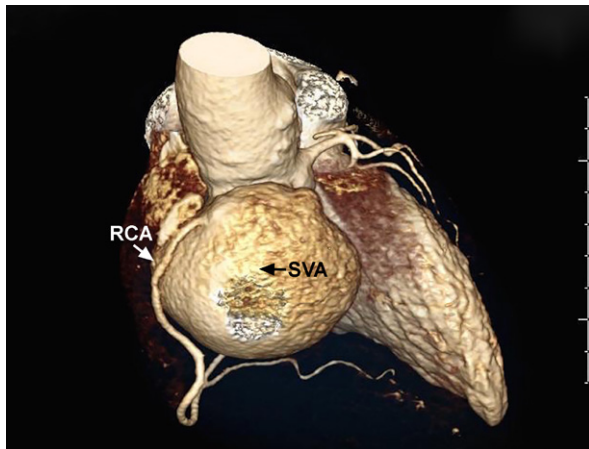
**From:** Department of Cardio-thoracic Surgery, Royal Sussex County Hospital, Brighton BN2 5BE, United Kingdom

Ms Cucchi etti is a 5th-year medical student.

**Address for reprints:** Vincenzo Giamb Bruno, MD, 76A Marine Parade, Brighton BN2 1AE, UK

**E-mail:** giambBrunov@gmail.com

© 2016 by the Texas Heart<sup>®</sup> Institute, Houston



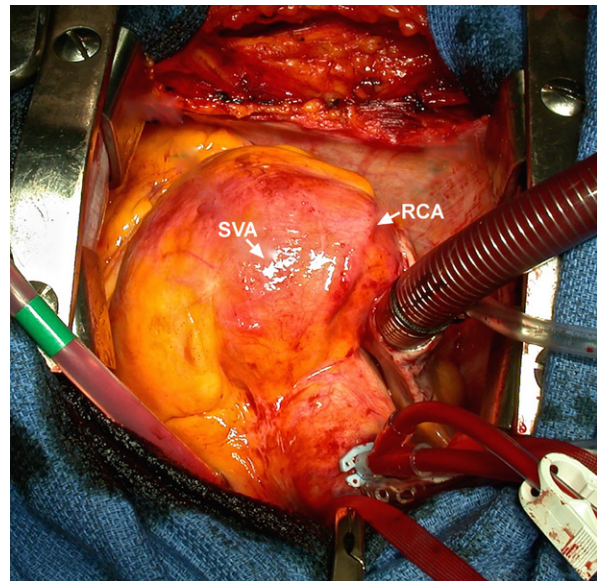
**Fig. 1** Computed tomogram (3-dimensional reconstruction) shows a giant right sinus of Valsalva aneurysm (SVA) and the right coronary artery (RCA) arising from it.

Twelve months postoperatively, the patient remained asymptomatic and was doing well. An echocardiogram showed good biventricular function and a normally functioning aortic prosthesis.

## Discussion

Sinus of Valsalva aneurysms have an incidence of approximately 0.1% in the general population.<sup>2</sup> Although most SVAs are congenital, acquired aneurysms can be caused by conditions affecting the aortic wall, such as infections, degenerative diseases, thoracic trauma, Marfan syndrome, and Behçet disease.<sup>3,4</sup> The natural history of SVAs is difficult to determine because of their rarity. Unruptured SVAs are typically asymptomatic, and there are no guidelines regarding the timing of surgical intervention. Early surgery is usually recommended when SVAs cause symptoms, rupture, compression of adjacent structures, or substantial dilation or aortic regurgitation.<sup>5</sup> Despite the paucity of scientific data, we concluded that a clinically silent SVA as large as our patient's should be repaired, because its enlargement exceeded 50% of normal sinus size.

Typically, SVAs are treated with direct suturing or patch repair, depending on defect size and the quality of the tissues. The presence of aortic regurgitation generally requires aortic valve replacement; if involvement is extensive and the aortic root is distorted, full aortic root replacement might be necessary.<sup>5</sup> If the aortic cusps are intact, valve-sparing root replacement might be a viable option. We chose to replace our patient's aortic valve because of the extensive involvement and weakened right annulus. We reconstructed the aortic wall and annulus with use of a patch; because reshaping the right sinus and the related annular portion was feasible, we did not consider it necessary to replace the aortic root. We decided to minimize unnecessary sur-



**Fig. 2** Intraoperative photograph shows the right sinus of Valsalva aneurysm (SVA) and the right coronary artery (RCA) running across its surface.

gical incisions, avoiding a classic transverse aortotomy in favor of direct access through the aneurysmal cavity. As described, this enabled easy implantation of the mechanical prosthesis. Our opinion is that avoiding aortotomy is undeniably advantageous but should be advocated only if access through the defect is good. In addition, in this case we preferred to avoid reimplanting the RCA ostium, because of concerns about the tissue quality of the SVA and coronary button. We think that our technique might be useful in other patients who have this unusual cardiac abnormality.

## References

1. Feldman DN, Roman MJ. Aneurysms of the sinuses of Valsalva. *Cardiology* 2006;106(2):73-81.
2. Takach TJ, Reul GJ, Duncan JM, Cooley DA, Livesay JJ, Ott DA, Frazier OH. Sinus of Valsalva aneurysm or fistula: management and outcome. *Ann Thorac Surg* 1999;68(5):1573-7.
3. Batiste C, Bansal RC, Razzouk AJ. Echocardiographic features of an unruptured mycotic aneurysm of the right aortic sinus of Valsalva. *J Am Soc Echocardiogr* 2004;17(5):474-7.
4. Greiss I, Ugolini P, Joyal M, Bouchard D, Mercier LA. Ruptured aneurysm of the left sinus of Valsalva discovered 41 years after a decelerational injury. *J Am Soc Echocardiogr* 2004;17(8):906-9.
5. Vural KM, Sener E, Tasdemir O, Bayazit K. Approach to sinus of Valsalva aneurysms: a review of 53 cases. *Eur J Cardiothorac Surg* 2001;20(1):71-6.

## Editorial Commentary

Giamb Bruno and colleagues<sup>1</sup> have described an unusual approach to an uncommon case of a large right sinus of

Valsalva aneurysm (SVA). The authors replaced the aortic valve through the opening of the resected aneurysm, repairing the right sinus and bypassing the right coronary artery. They used this approach to avoid making a standard aortotomy, reasoning that “avoiding aortotomy is undeniably advantageous but should be advocated only if access through the defect is good.” I applaud the authors’ ingenuity in their approach but strongly disagree that a standard aortotomy is an undeniable disadvantage to be avoided. A standard transverse aortotomy would have enabled easy access for evaluation of the aortic valve and SVA. It might well have enabled a more standard approach to evaluating the aortic valve for possible repair, rather than replacement.

The authors have clearly shown that treating an isolated SVA and replacing the aortic valve can be performed by means of their alternative technique. However, we must ask ourselves if the fact that it *can* be done in this

way means that it *should* be done in this way. When I was privileged to train under Dr. Denton Cooley, he often told us to “keep it simple.” I would suggest that our readers consider this advice when faced with unusual situations.

*Michael J. Reardon, MD,  
Houston Methodist DeBakey Heart &  
Vascular Center,  
Houston*

## References

---

1. Giambruno V, Cucchiatti C, Pisano C, Hyde J. Alternative surgical approach to repairing a giant sinus of Valsalva aneurysm. *Tex Heart Inst J* 2016;43(1):43-4.

<http://dx.doi.org/10.14503/THIJ-15-5425>