

# Middle Aortic Syndrome: Imaging and Endovascular Treatment

**Menfil A. Orellana-Barrios, MD**  
**Alvaro Rosales, MD**  
**Ayman Karkoutly, MD**  
**Gary E. Meyerrose, MD**

**A** 69-year-old woman with hypertension, hyperlipidemia, and ischemic heart disease presented with exertion-associated back pain between her shoulder blades and with bilateral leg claudication. Physical examination revealed weak lower-extremity pulses. The patient had no personal or family history of autoimmune disease. Images obtained with use of 64-channel computed tomographic (CT) angiography showed marked stenosis of the descending aorta above the renal arteries (Fig. 1). The invasive aortic pressure above the stenosis was 168/77 mmHg (mean trans-stenosis gradient, >100 mmHg) (Fig. 2). The diagnosis was middle aortic syndrome.

We implanted a 28-mm × 28-mm × 10-cm Gore® Tag® Thoracic Endoprosthesis (W.L. Gore & Associates, Inc.; Flagstaff, Ariz) and performed balloon angioplasty with use of 2 Armada™ balloons (Abbott Laboratories; Abbott Park, Ill) (Fig. 3). After a few hours, the patient sustained hypotension and bradycardia that resolved after the administration of intravenous fluids and atropine. Contrast CT of the abdomen, performed to ensure stent and aortic integrity, revealed no bleeding, dissection, thrombosis, or other abnormalities (Fig. 4). The patient was discharged from the hospital with instructions to take aspirin (81 mg/d) and clopidogrel (75 mg/d), in addition to continuing her established regimen of simvastatin. At her 6-month evaluation, she had no claudication symptoms.

**Section Editor:**

Raymond F. Stainback, MD,  
Department of Adult  
Cardiology, Texas Heart  
Institute, 6624 Fannin St.,  
Suite 2480, Houston, TX  
77030

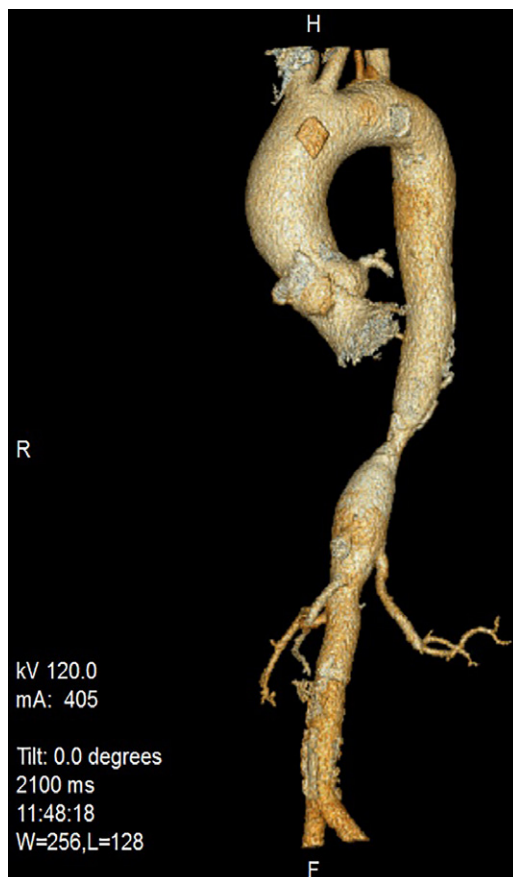**From:** Departments of Internal Medicine (Dr. Orellana-Barrios) and Cardiology (Drs. Meyerrose and Rosales), Texas Tech University Health Sciences Center; and University Medical Center (Dr. Karkoutly); Lubbock, Texas 79430

**Address for reprints:**

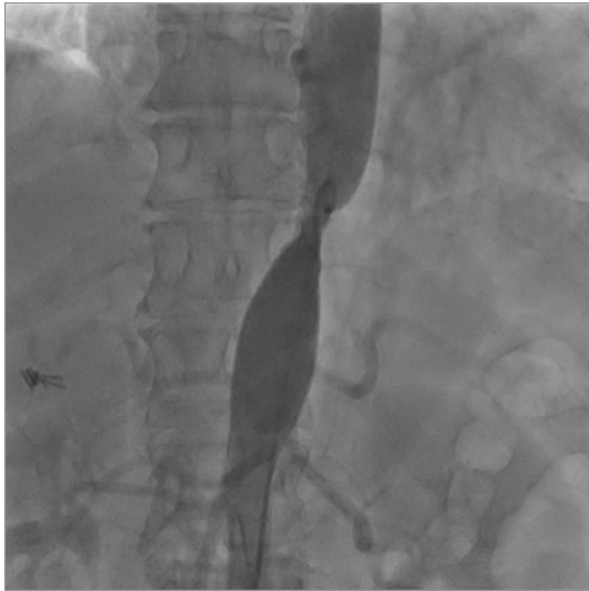Menfil A. Orellana-Barrios,  
MD, MS 9410, Texas Tech  
University Health Sciences  
Center, 3601 4th St.,  
Lubbock, TX 79430

**E-mail:** [ma.orellana-barrios@ttuhsc.edu](mailto:ma.orellana-barrios@ttuhsc.edu)

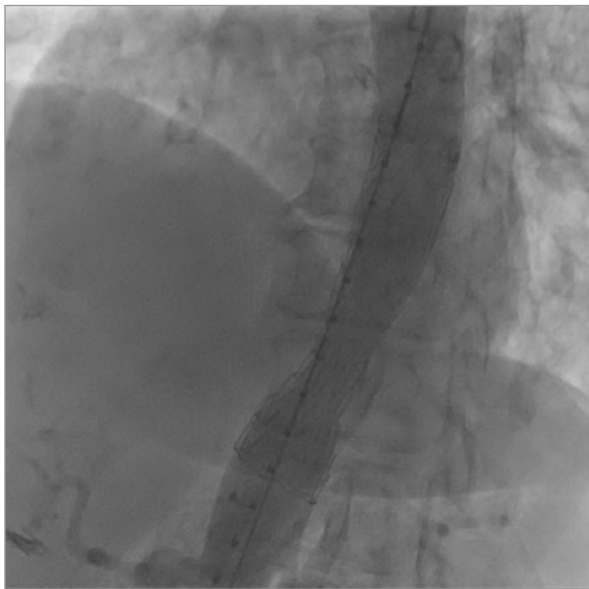
© 2015 by the Texas Heart®  
Institute, Houston



**Fig. 1** Computed tomographic reconstruction shows a single discrete narrowing of the descending aorta above the celiac trunk and renal arteries.



**Fig. 2** Abdominal aortogram reveals an aortic pressure gradient >100 mmHg before and after the stenosis.

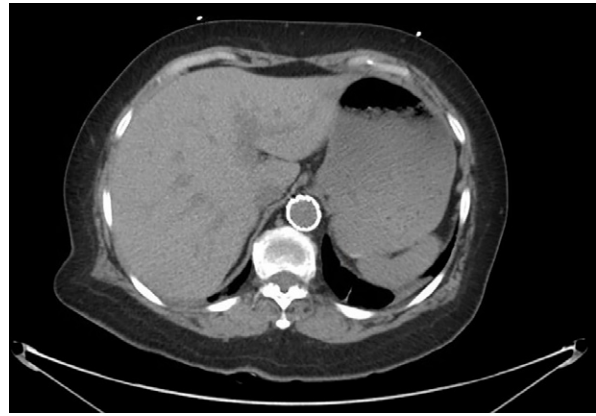

**Fig. 3** Abdominal aortogram shows the deployed stent and improved aortic flow after balloon dilation.

### Comment

Middle aortic syndrome consists of a pathologic narrowing and stenosis of the descending thoracic aorta, abdominal aorta, or both. Acquired causes include those associated with neurofibromatosis, fibromuscular dysplasia, retroperitoneal fibrosis, and inflammatory conditions such as Takayasu disease and temporal arteritis.<sup>1</sup>

Clinical presentation depends on the location of the lesion. Patients can present with severe hypertension, headache, mesenteric ischemia, and (as in our patient)



**Fig. 4** Computed tomogram shows the intra-aortic stent.

bilateral lower-limb claudication. Although surgical correction is often performed, the endovascular approach is feasible for discrete aortic stenoses that do not involve the mesenteric or renal arteries.<sup>2</sup>

This case illustrates the clinical presentation of a discrete, isolated descending aortic stenosis and the feasibility of stent placement after CT imaging. In addition, contrast CT imaging was useful to us in evaluating possible complications after stent placement, such as mural thrombosis,<sup>3</sup> bleeding, stent migration,<sup>4</sup> and chronic aneurysmal formation and intimal hyperplasia in a patient with vasculitis.<sup>1</sup>

### References

1. Delis KT, Gloviczki P. Middle aortic syndrome: from presentation to contemporary open surgical and endovascular treatment. *Perspect Vasc Surg Endovasc Ther* 2005;17(3):187-203.
2. Heijmen RH, Schepens MA. Mural thrombosis in thoracic aortic stent-graft. *Eur J Cardiothorac Surg* 2002;22(4):628.
3. Stanley JC. Commentary on "Middle aortic syndrome: from presentation to contemporary open surgical and endovascular treatment". *Perspect Vasc Surg Endovasc Ther* 2005;17(3):204-6.
4. Magee AG, Brzezinska-Rajszyk G, Qureshi SA, Rosenthal E, Zubrzycka M, Ksiazek J, Tynan M. Stent implantation for aortic coarctation and recoarctation. *Heart* 1999;82(5):600-6.