

# Prosthetic Valve Endocarditis with Valvular Obstruction

after Transcatheter Aortic Valve Replacement

Christine Pabilona, MD  
Bernard Gitler, MD  
Jeffrey A. Lederman, MD  
Donald Miller, MD  
Theodore N. Keltz, MD

Patients with severe aortic stenosis who are at high risk for open-heart surgery might be candidates for transcatheter aortic valve replacement (TAVR). To our knowledge, this is the first report of *Streptococcus viridans* endocarditis that caused prosthetic valve obstruction after TAVR.

A 77-year-old man who had undergone TAVR 17 months earlier was admitted because of evidence of prosthetic valve endocarditis. A transthoracic echocardiogram revealed a substantial increase in the transvalvular peak gradient and mean gradient in comparison with an echocardiogram of 7 months earlier. A transesophageal echocardiogram showed a 1.5-cm vegetation obstructing the valve. Blood cultures yielded penicillin-sensitive *S. viridans*. The patient was hemodynamically stable and was initially treated with vancomycin because of his previous penicillin allergy. Subsequent therapy with levofloxacin, oral penicillin (after a negative penicillin skin test), and intravenous penicillin eliminated the symptoms of the infection.

Transcatheter aortic valve replacement is a relatively new procedure, and sequelae are still being discovered. We recommend that physicians consider obstructive endocarditis as one of these. (*Tex Heart Inst J* 2015;42(2):172-4)

**Key words:** Anti-bacterial agents/therapeutic use; aortic valve/surgery; aortic valve stenosis/complications/therapy; endocarditis, bacterial/diagnosis/therapy; heart valve prosthesis implantation/adverse effects/methods; postoperative complications; prosthesis-related infections/drug therapy; treatment outcome

**From:** Department of Medicine, Montefiore New Rochelle Hospital, New Rochelle, New York 10801

**Address for reprints:** Christine Pabilona, MD, Department of Medicine, Montefiore New Rochelle Hospital, 16 Guion Pl., New Rochelle, NY 10801

**E-mail:** [chrispabilona@yahoo.com](mailto:chrispabilona@yahoo.com)

© 2015 by the Texas Heart<sup>®</sup> Institute, Houston

**P**atients with severe aortic stenosis who are at high risk for open-heart surgery might be candidates for transcatheter aortic valve replacement (TAVR). Infective endocarditis after TAVR is an emerging problem, and no clear guidelines govern its diagnosis or management. We report a case of *Streptococcus viridans* endocarditis that caused prosthetic valve obstruction after TAVR in an elderly patient, and we briefly review the relevant medical literature.

## Case Report

In September 2013, a 77-year-old man with coronary artery disease was admitted because of suspected endocarditis. He had undergone percutaneous coronary intervention and had severe aortic stenosis. He had been turned down for conventional valve replacement because of obstructive sleep apnea and severe emphysema (forced expiratory volume in 1 s [FEV<sub>1</sub>]/forced vital capacity [FVC], 28%; and FEV<sub>1</sub>, 19% predicted). He had developed rashes upon taking penicillin. He had undergone TAVR in April 2012 (17 mo before this admission), involving the implantation of an Edwards SAPIEN™ 23-mm valve (Edwards Lifesciences LLC; Irvine, Calif).

In February 2013, 10 months after TAVR, a transthoracic echocardiogram (TTE) showed normal left ventricular (LV) size and systolic function (LV ejection fraction, 0.60–0.65) and the presence of a bioprosthetic aortic valve. The peak aortic valve gradient was 35 to 40 mmHg (mean gradient, 15–20 mmHg). No repeat pulmonary function tests were performed; however, his New York Heart Association functional class had improved from III to II. In May 2013, he had reported intermittent fever with night sweats, loss of appetite, and progressive shortness of breath.

On admission, he had a temperature of 37.5 °C, a blood pressure of 112/67 mmHg, a heart rate of 89 beats/min, and a respiratory rate of 22 breaths/min. He had bilaterally decreased breath sounds with occasional rhonchi. Cardiac examination revealed a grade 1/6 systolic ejection murmur at the left sternal border and base. No signs of endocarditis were noted. Examination results of other organ systems were normal. Laboratory tests revealed leukocytes of 13,000/mm<sup>3</sup> with a predominance of neutro-

phils. The patient's B-type natriuretic peptide level was 295 pg/mL. A chest radiograph showed no acute disease process. An electrocardiogram revealed sinus rhythm with a PR interval of 148 ms, a QRS duration of 90 ms, a QRS axis of +45°, and a QTc of 406 ms. Voltage criteria suggested no LV hypertrophy. Telemetry revealed frequent premature ventricular contractions.

A TTE showed normal LV wall motion with normal systolic function and an estimated LV ejection fraction of 0.55 to 0.60. In comparison with the findings 7 months earlier, the patient's transvalvular peak gradient had now increased from 35–40 mmHg to 84 mmHg; and his mean pressure gradient, from 15–20 mmHg to 55 mmHg. A transesophageal echocardiogram revealed a 1.5-cm vegetation obstructing the bioprosthetic aortic valve (Fig. 1).

Despite possible heart failure from the obstructive vegetation and the risk of embolization, the patient was not a surgical candidate. Two sets of blood cultures 18 hours apart yielded penicillin-sensitive *S. viridans* as the infective organism. The patient was hemodynamically stable, with no signs of congestive heart failure, thromboembolism, or other sequelae. A repeat TTE on the 10th day of hospitalization showed no changes. A peripherally inserted central catheter was placed, and he was discharged from the hospital for home vancomycin therapy.

A repeat TTE after 6 weeks revealed a peak aortic gradient of 55 to 60 mmHg and a mean gradient of 35 mmHg.

At the patient's 3-month follow-up examination in December 2013, he was doing well and had no fever, chills, or signs of infection. Because of the severity of his condition, he was placed on chronic suppression with

levofloxacin. Penicillin skin testing was negative, so the levofloxacin was replaced with oral penicillin.

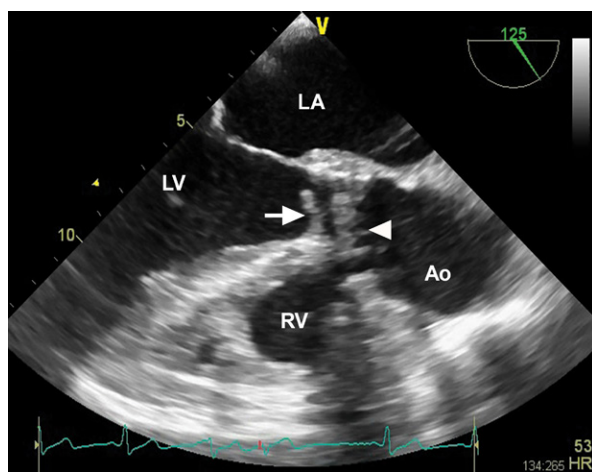
The patient had a transient ischemic attack 5 months after initial admission. Two repeat blood cultures, a week apart, showed penicillin-sensitive *S. viridans*. Oral penicillin was changed to intravenous penicillin, administered through a peripherally inserted central catheter. A TTE revealed a peak aortic gradient of 40 mmHg, a mean gradient of 25 mmHg, and an estimated aortic valve area of 1.3 cm<sup>2</sup>, similar to the patient's baseline readings.

At the patient's 6-month follow-up examination in March 2014, he was doing well and had no fever or chills after finishing a 6-week course of intravenous penicillin. Repeat spirometry showed severe obstruction (FEV<sub>1</sub>/FVC, 33%; and FEV<sub>1</sub>, 17% predicted) with low vital capacity. At last examination (February 2015), the patient reported no fever or chills, continued to take oral penicillin, and had negative blood cultures.

## Discussion

Transcatheter aortic valve replacement can be an option for patients with severe aortic stenosis who are turned down for conventional aortic valve replacement because of the surgical risk.<sup>1</sup> The more frequent performance of TAVR procedures has led to the recognition and identification of procedure-related sequelae. A review has highlighted the most relevant early sequelae of TAVR, which include vascular issues, stroke, renal failure, paravalvular leak with aortic regurgitation, and atrioventricular block.<sup>2</sup> Few data are available about late sequelae of TAVR.

Prosthetic valve endocarditis (PVE) is worrisome because of its poor prognosis. Optimal medical management is sometimes not enough, and surgical aortic valve replacement might be necessary in high-risk patients who earlier were not considered to be surgical candidates. Prosthetic valve endocarditis appears to have a low prevalence after TAVR: our review of the medical literature yielded 17 cases of TAVR endocarditis<sup>3-19</sup> and a single-center cohort that summarized 5 other post-TAVR cases of PVE.<sup>20</sup> All 22 patients had varying presentations, pathogens, and treatment; however, none reportedly had endocarditis that caused obstruction or significant gradient changes across the aortic valve on echocardiograms. Of 10 patients<sup>3-12</sup> who underwent explantation of the infected prosthetic valve with aortic valve replacement, one died postoperatively.<sup>12</sup> Of 12 patients<sup>13-20</sup> who were given medical therapy, 5 died.<sup>17-20</sup> *Enterococcus faecalis* was the infective organism in 7 of the patients,<sup>10-12,16,17,20</sup> *S. viridans* in 3,<sup>3,5,20</sup> coagulase-negative staphylococci in 2,<sup>14,19</sup> and *Corynebacterium*,<sup>4</sup> *E. durans*,<sup>8</sup> *Pseudomonas*,<sup>9</sup> *Moraxella*,<sup>15</sup> *Candida*,<sup>18</sup> methicillin-resistant *Staphylococcus aureus*,<sup>20</sup> and *Escherichia coli* in one patient each.<sup>20</sup> No organism was identified in 2



**Fig. 1** Transesophageal echocardiogram (midesophageal view at 125°) shows the vegetation (arrow) and the bioprosthetic valve (arrowhead).

Ao = aorta; LA = left atrium; LV = left ventricle; RV = right ventricle

patients,<sup>6,7</sup> although *Histoplasma* was cultured from the explanted valve in one.<sup>6</sup> One patient<sup>13</sup> had multibacterial flora in the culture. Edwards SAPIEN prostheses were used in 16 of the patients<sup>3,5-13,17,18,20</sup> and CoreValve® prostheses (Medtronic, Inc.; Minneapolis, Minn) in 6.<sup>4,14-16,19,20</sup> The interval between TAVR and hospitalization for PVE ranged from less than 2 weeks<sup>13,18</sup> to 23 months.<sup>20</sup> Echocardiographic findings included vegetation, paravalvular leak, abscess, fistula formation, dehiscence, and valvular dysfunction.

In patients with native-valve endocarditis, valvular regurgitation has been the hemodynamic sequela most frequently described; however, valvular obstruction, even from *S. viridans* endocarditis, has been reported.<sup>21</sup> The increase in transaortic peak and mean gradients in our patient was due to the prosthetic valve obstruction. The size and location of the vegetation was critical; however, the patient was considered to be at too high a risk for surgery, which limited his therapeutic options to long-term intravenous antibiotics. He had good short-term results.

Endocarditis, a grave sequela of any prosthetic valve placement, is associated with high morbidity and mortality rates.<sup>22</sup> To our knowledge, this is the first reported case of post-TAVR *S. viridans* endocarditis associated with prosthetic valve obstruction. We recommend that physicians consider this sequela in order to achieve prompt diagnosis and optimal management.

## References

1. Smith CR, Leon MB, Mack MJ, Miller DC, Moses JW, Svensson LG, et al. Transcatheter versus surgical aortic-valve replacement in high-risk patients. *N Engl J Med* 2011;364(23):2187-98.
2. Neragi-Miandoab S, Michler RE. A review of most relevant complications of transcatheter aortic valve implantation. *ISRN Cardiol* 2013;2013:956252.
3. Seok Koh Y, Hyoung Moon M, Hyun Jo K, Wook Kim H. Infective endocarditis in transcatheter aortic valve implantation. *Eur J Cardiothorac Surg* 2014;45(3):582.
4. Comoglio C, Boffini M, El Qarra S, Sansone F, D'Amico M, Marra S, Rinaldi M. Aortic valve replacement and mitral valve repair as treatment of complications after percutaneous core valve implantation. *J Thorac Cardiovasc Surg* 2009;138(4):1025-7.
5. Wong DR, Boone RH, Thompson CR, Allard MF, Altwegg L, Carere RG, et al. Mitral valve injury late after transcatheter aortic valve implantation. *J Thorac Cardiovasc Surg* 2009;137(6):1547-9.
6. Head SJ, Dewey TM, Mack MJ. Fungal endocarditis after transfemoral aortic valve implantation. *Catheter Cardiovasc Interv* 2011;78(7):1017-9.
7. Castiglioni A, Pozzoli A, Maisano F, Alfieri O. Endocarditis after transfemoral aortic valve implantation in a patient with Osler-Weber-Rendu syndrome. *Interact Cardiovasc Thorac Surg* 2012;15(3):553-4.
8. Zytowski M, Erb M, Albes JM, Hartrumpf M. Infective endocarditis 4 months after transapical aortic valve implantation with Edwards SAPIEN™ XT. *Eur J Cardiothorac Surg* 2013;44(4):769.
9. Saeed G, Matin M, Gradaus R, Peivandi AA. Prosthetic aortic valve endocarditis after transcatheter aortic valve implantation [abstract]. *Thorac Cardiovasc Surg* 2013;61(S01):63. Available from: <https://www.thieme-connect.de/DOI/DOI?10.1055/s-0032-1332703>.
10. Hirnle G, Holzhey D, Borger M, Mohr FW. Infective mitral valve endocarditis after transapical aortic valve implantation. *Interact Cardiovasc Thorac Surg* 2013;16(3):394-5.
11. Santarpino G, Fischlein T, Pfeiffer S. Prosthetic valve endocarditis 6 months after transcatheter aortic valve implantation [in Italian]. *G Ital Cardiol (Rome)* 2013;14(2):138-40.
12. Hidiroglu M, Kucuker A, Erdogan KE, Bayram H, Bilgic A, Durmaz T, Sener E. Infective endocarditis after transcatheter aortic valve implantation [abstract]. *Interact Cardiovasc Thorac Surg* 2013;17(Suppl 2):115-6.
13. Venner C, Moreira P, Frikha Z, Angioi M, Folliguet T, Aliot E, et al. Transcatheter aortic valve implantation and mitral valve injury: not too low but not too high [abstract]. *Eur Heart J* 2013;34(Suppl 1):1710.
14. Chrissoheris MP, Ferti A, Spargias K. Early prosthetic valve endocarditis complicating repeated attempts at CoreValve implantation. *J Invasive Cardiol* 2011;23(12):E291-2.
15. Rafiq I, Parthasarathy H, Tremlett C, Freeman LJ, Mullin M. Infective endocarditis caused by *Moraxella nonliquefaciens* in a percutaneous aortic valve replacement. *Cardiovasc Revasc Med* 2011;12(3):184-6.
16. Loh PH, Bundgaard H, Sondergaard L. Infective endocarditis following transcatheter aortic valve replacement: diagnostic and management challenges. *Catheter Cardiovasc Interv* 2013;81(4):623-7.
17. Carnero-Alcazar M, Maroto Castellanos LC, Carnicer JC, Rodriguez Hernandez JE. Transapical aortic valve prosthetic endocarditis. *Interact Cardiovasc Thorac Surg* 2010;11(3):252-3.
18. Santos M, Thiene G, Sievers HH, Basso C. Candida endocarditis complicating transapical aortic valve implantation. *Eur Heart J* 2011;32(18):2265.
19. Gotzmann M, Mugge A. Fatal prosthetic valve endocarditis of the CoreValve ReValving System. *Clin Res Cardiol* 2011;100(8):715-7.
20. Puls M, Eiffert H, Hunlich M, Schondube F, Hasenfuß G, Seipelt R, Schillinger W. Prosthetic valve endocarditis after transcatheter aortic valve implantation: the incidence in a single-centre cohort and reflections on clinical, echocardiographic and prognostic features. *EuroIntervention* 2013;8(12):1407-18.
21. Charney R, Keltz TN, Attai L, Merav A, Schwinger ME. Acute valvular obstruction from streptococcal endocarditis. *Am Heart J* 1993;125(2 Pt 1):544-7.
22. Eisen A, Shapira Y, Sagie A, Kornowski R. Infective endocarditis in the transcatheter aortic valve replacement era: comprehensive review of a rare complication. *Clin Cardiol* 2012;35(11):E1-5.