

Incidental Diagnosis of a Double Aortic Arch

during an Acute Myocardial Infarction

Andre Akhondi, MD
Stefan G. Ruehm, MD, PhD
Ramin Tabibiazar, MD
Eric H. Yang, MD

A 65-year-old previously asymptomatic woman with a history of tobacco use presented after experiencing an hour of chest pain and syncope. A 12-lead electrocardiogram revealed an inferior ST-elevation myocardial infarction. Coronary angiography revealed an acute thrombotic occlusion of the right coronary artery (Fig. 1); however, there was difficulty in maneuvering diagnostic catheters to the coronary ostia. Subsequent aortography revealed a double aortic arch (Fig. 2). After

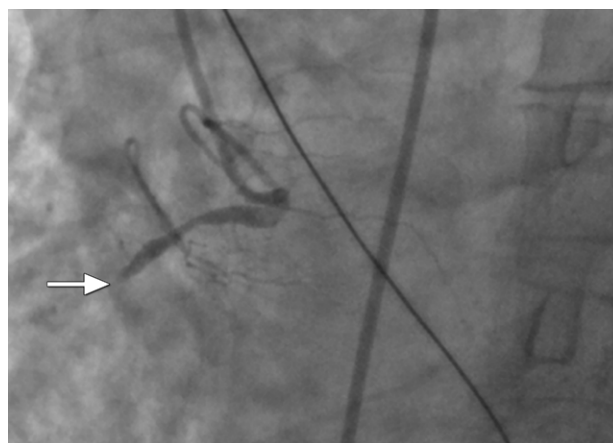


Fig. 1 Coronary angiogram, left anterior oblique view, shows an acute thrombotic occlusion (arrow) of the right coronary artery.

Section Editor:

Raymond F. Stainback, MD,
Department of Adult
Cardiology, Texas Heart
Institute, 6624 Fannin St.,
Suite 2480, Houston, TX
77030

From: Division of Cardiology,
Department of Medicine
(Drs. Akhondi, Tabibiazar,
and Yang) and Cardiovascular
Imaging Section,
Department of Radiology
(Dr. Ruehm), University of
California at Los Angeles,
Los Angeles, California
90095

Address for reprints:

Eric H. Yang, MD, UCLA
Cardiovascular Center, Uni-
versity of California at Los
Angeles, 100 Medical Plaza,
Suite 630, Los Angeles, CA
90095

E-mail:

Datsunian@gmail.com

© 2014 by the Texas Heart®
Institute, Houston

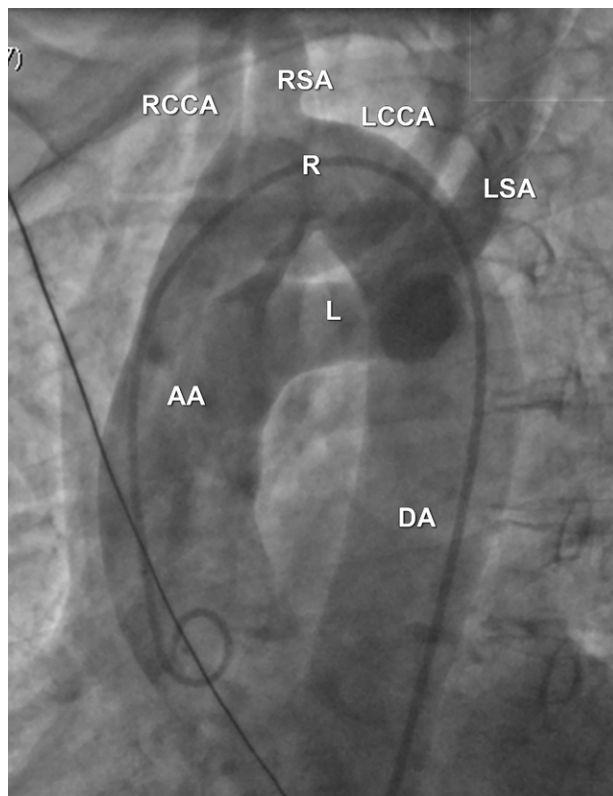


Fig. 2 Aortogram, left anterior oblique view, shows evidence of a double aortic arch system.

AA = ascending aorta; DA =
descending aorta; L = left aor-
tic arch; LCCA = left common
carotid artery; LSA = left sub-
clavian artery; R = right aortic
arch; RCCA = right common
carotid artery; RSA = right
subclavian artery

revascularization, 64-slice computed tomography (CT) of the aorta (Fig. 3) showed a dominant right aortic arch (Fig. 4A) to the right of the trachea, with separate ostia of the right subclavian and common carotid arteries. A more inferiorly located left aortic arch (Fig. 4B) connected the ascending and descending aorta at the left of the trachea, with separate ostia of the left subclavian and common carotid arteries. No vascular ring was seen. The aorta was also right sided (Fig. 4C).

Comment

A double aortic arch is a variant of vascular ring, occurring in 0.05% to 0.3% of the general population.¹ It can encircle the trachea and esophagus via connected segments of aortic arch, causing symptoms of dyspnea, stridor, or dysphagia in infancy or early childhood^{2,3}; rarely, these symptoms develop in adulthood.⁴⁻⁶ Double aortic arch is the result of persistence of both the left and right embryonic 4th arches and dorsal aortas.⁷ Aortic arch "sidedness" is the side of the trachea that the arch passes as it crosses a mainstem bronchus.⁸ Cardiovascular CT can provide definitive evaluation of the course and orientation of these aortic arch variants and of associated cardiac anomalies. This case illustrates the supplementary role of CT with invasive aortography in diagnosing a rare aortic anatomic variant.

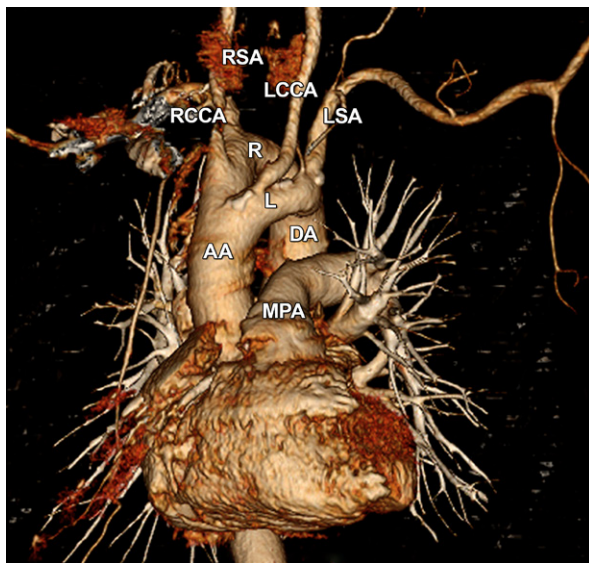


Fig. 3 This 64-slice cardiac computed tomogram is a 3-dimensional volume rendering (left anterior oblique view) that correlates with the aortographic view in Fig. 2.

AA = ascending aorta; DA = descending aorta; L = left aortic arch; LCCA = left common carotid artery; LSA = left subclavian artery; MPA = main pulmonary artery; R = right aortic arch; RCCA = right common carotid artery; RSA = right subclavian artery

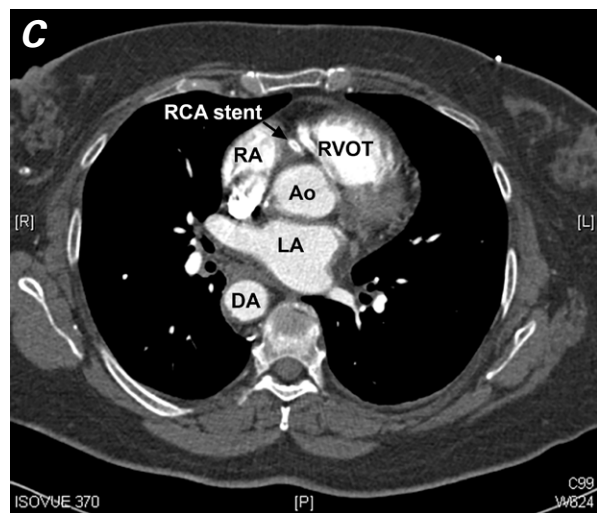
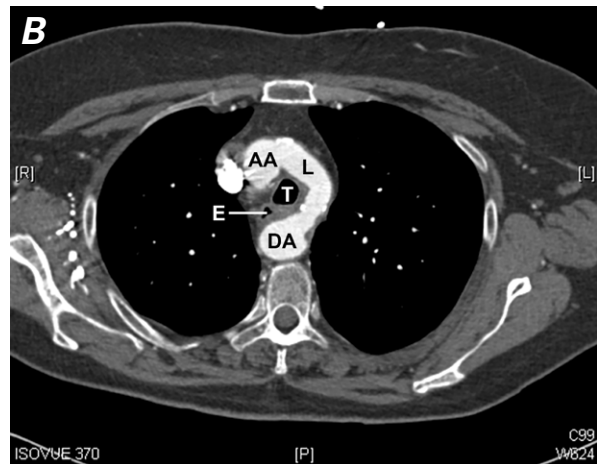
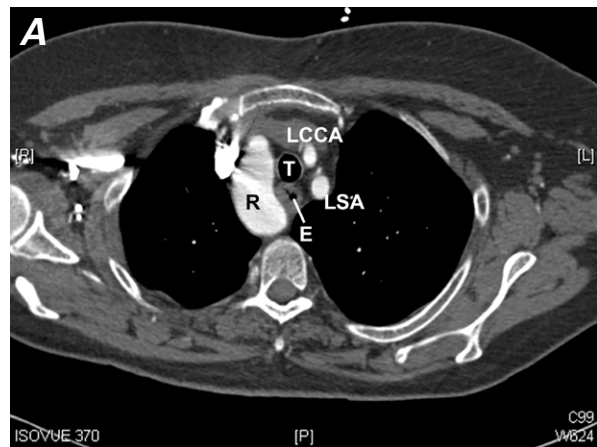


Fig. 4 64-Slice cardiac computed tomograms (all axial views) at the levels of the **A**) right and **B**) left aortic arches and the **C**) aortic valve. In **C**, note the stent (arrow) in the right coronary artery at the level of the aortic valve. The descending aorta is right sided.

AA = ascending aorta; Ao = aortic valve; DA = descending aorta; E = esophagus; L = left aortic arch; LA = left atrium; LCCA = left common carotid artery; LSA = left subclavian artery; R = right aortic arch; RA = right atrium; RCA = right coronary artery; RVOT = right ventricular outflow tract; T = trachea

References

1. Kanne JP, Godwin JD. Right aortic arch and its variants. *J Cardiovasc Comput Tomogr* 2010;4(5):293-300.
2. Cox DA, Quinn RD, Moran AM. Two cases of a double aortic arch with left arch atresia subtype 2 and Kommerell's diverticulum. *Cardiol Young* 2011;21(2):220-1.
3. Adachi I, Krishnamurthy R, Morales DL. A double aortic arch mimicking a right aortic arch with an aberrant subclavian artery. *J Vasc Surg* 2011;54(4):1151-3.
4. Narayan RL, Kanwar A, Jacobi A, Sanz J. Imaging a boa constrictor--the incomplete double aortic arch syndrome. *Heart Lung Circ* 2012;21(11):745-6.
5. Secco GG, Marino PN, Carriero A, De Luca G. Silent double aortic arch coincidentally found during cardiac catheterization in elderly man. *Congenit Heart Dis* 2011;6(1):74-6.
6. Jonker Ide V, Nunes AJ, Elhenawy AM, Das D, MacArthur R. Double aortic arch presenting in an adult with dysphagia. *J Card Surg* 2013;28(6):670-2.
7. Chung JH, Gunn ML, Godwin JD, Takasugi J, Kanne JP. Congenital thoracic cardiovascular anomalies presenting in adulthood: a pictorial review. *J Cardiovasc Comput Tomogr* 2009;3(1 Suppl):S35-46.
8. Weinberg PM. Aortic arch anomalies. *J Cardiovasc Magn Reson* 2006;8(4):633-43.