

# Use of a Sandwich Technique

## to Repair a Left Ventricular Rupture after Mitral Valve Replacement

Myles E. Lee, MD  
Mallika Tamboli  
Anthony W. Lee, MD

*One difficulty with external repair of left ventricular rupture after mitral valve replacement is collateral bleeding in friable myocardium adjacent to the rupture. The bleeding is caused by tension on the closing sutures, whether or not pledgets have been used.*

*We report the case of a 69-year-old woman who underwent an uneventful mitral valve replacement. After cardiopulmonary bypass was terminated, brisk bleeding started from high in the posterior left ventricular wall, typical of a type III defect. We undertook external repair, placing a plug of Teflon felt into the cavity of the rupture and sandwiching it into place with pledgeted mattress and figure-of-8 sutures. The space occupied by the plug decreased the distance needed to obliterate the defect and thereby reduced the tension on the sutures necessary to achieve hemostasis. This simple technique enabled closure of the defect and avoided collateral tears that would have compromised an otherwise successful repair. Two years postoperatively, the patient had normal mitral valve function and no left ventricular aneurysm. In addition to reporting the patient's case, we review the types of left ventricular rupture that can occur during mitral valve replacement and discuss the various repair options. (Tex Heart Inst J 2014;41(2):195-7)*

**Key words:** Cardiac surgical procedures/adverse effects; heart rupture/etiology; heart valve prosthesis implantation/adverse effects; heart ventricles/injuries/surgery; mitral valve insufficiency/surgery; surgical techniques; treatment outcome

**From:** Department of Cardiothoracic Surgery (Drs. A. Lee and M. Lee), St. Francis Medical Center, Lynwood, California 90262; and pre-medical student (Ms Tamboli), Washington University, St. Louis, Missouri 63130

**Address for correspondence:**  
Myles E. Lee, MD,  
938 Bel Air Rd.,  
Los Angeles, CA 90077

**E-mail:**  
meleemd@gmail.com

© 2014 by the Texas Heart®  
Institute, Houston

First reported by Roberts and Morrow in 1967,<sup>1</sup> rupture of the left ventricle (LV) is a frequently lethal complication of mitral valve replacement (MVR). Type I rupture occurs at the level of the atrioventricular groove, type II at the level of the posterior papillary muscle,<sup>2</sup> and type III in the posterior LV free wall between the atrioventricular groove and the insertion of the posterior papillary muscle.<sup>3</sup> We report our use of a “sandwich” technique to repair a type III rupture in an elderly woman after MVR. In addition, we discuss the types of LV rupture and various repair options.

### Case Report

In January 2010, a 69-year-old woman with rheumatic mitral stenosis, mitral insufficiency, and chronic atrial fibrillation underwent MVR with a 27-mm bileaflet mechanical prosthesis (St. Jude Medical, Inc.; St. Paul, Minn). We used a chordal-sparing technique, resecting the calcified central portion of the anterior leaflet and attaching its remnants to the mitral annulus at the 10- and 2-o'clock positions. We partially excised the thickened posterior leaflet at its leading edge, performed superficial débridement of calcium deposits on the posterior leaflet and the annulus, and divided the posterior leaflet in its mid portion to enable secure seating of the prosthesis.<sup>4</sup> We sutured the valve in place with interrupted 2-0 TiCron™ mattress sutures (Covidien Syneture; Mansfield, Mass) on Teflon pledgets, passed from the ventricular side through a small imbrication of posterior-leaflet tissue and then through the annulus. Using echocardiographic monitoring in the 4-chamber view, we de-aired the heart through the aortic root vent with ballottement of the heart and manual inversion of the left atrial appendage. At no time was the heart elevated from the pericardium to achieve de-airing. Immediately after the termination of cardiopulmonary bypass (CPB), brisk bleeding occurred from the posterior aspect of the heart.

Upon the resumption of CPB, we initially thought that the bleeding had originated from the coronary sinus or the atrioventricular groove. After the heart was arrested with cardioplegic solution administered antegrade, we identified the source of the bleeding from a defect high on the posterior LV free wall. We decided not to remove the mechanical valve and to approach the repair externally. Two attempts at

repair with 3-0 and 4-0 Prolene pledgeted mattress sutures were unsuccessful because of collateral tears in friable tissue adjacent to the defect. Finally, we cut pieces of 2-mm-thick polytetrafluoroethylene felt (Bard Peripheral Vascular, Inc.; Tempe, Ariz) to produce a plug that approximated the size of the defect. We placed the plug into the defect and sandwiched it in place with pledgeted 0 ETHIBOND® mattress sutures (Ethicon, Inc., a Johnson & Johnson company; Somerville, NJ) on an aneurysm needle. We then passed figure-of-8 sutures of 2-0 Prolene through the pledgets of the ETHIBOND sutures and through the plug, to prevent its migration into the ventricular cavity (Fig. 1). We applied a fibrin-based sealant to the repair site and terminated CPB, with complete hemostasis.

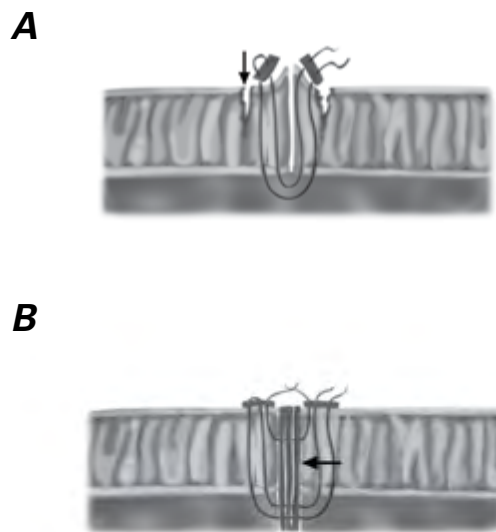
Postoperatively, the patient needed pharmacologic circulatory support. Intra-aortic balloon pumping helped to reduce afterload and LV systolic wall tension. After a difficult course that included dialysis-dependent renal failure, the patient was discharged from the hospital on the 30th postoperative day. At her 6-month postoperative visit, she no longer needed dialysis and was ambulatory. Two years after surgery, a transthoracic echocardiogram revealed normal function of the mechanical valve and no posterior LV aneurysm.

## Discussion

In a series of 5,449 patients who underwent MVR from 1995 through 2003, Zhang and colleagues<sup>5</sup> reported a 0.24% prevalence of LV rupture in association with a 61.5% mortality rate. In a more recent series of 2,560 patients, Deniz and associates<sup>6</sup> reported a 0.8% prevalence of rupture with an 86% overall operative mortality rate. Of those ruptures, 26% were type I, 13% were type II, and 61% were type III. No ruptures occurred in patients whose posterior leaflet was preserved. Ruptures predominantly occurred in patients who were given a larger mechanical prosthesis (29–31 mm).<sup>6</sup>

Type I ruptures result from excessive débridement of a calcified annulus, endocarditis with an annular abscess, resection of the posterior leaflet, subannular placement of valve sutures, or elevation of the heart with an implanted prosthesis in place. Type II ruptures are consequent to excessive traction on, or resection of, the posterior papillary muscle. Type III ruptures occur after the placement of a high-profile stented tissue valve with struts that are not tethered by a suture (especially in patients with a small LV) with subsequent strut perforation of the ventricle, or from the aggressive use of rigid, hand-held suction devices.

When CPB was used during repair of LV rupture,<sup>7</sup> reported survival rates were 67% after external repair and 27% after internal repair; without CPB, the survival rates decreased to 50% and 7%, respectively.



**Fig. 1** Graphic shows **A**) collateral myocardial tears (arrow) with use of pledgeted mattress sutures, and **B**) insertion of a felt plug (arrow) in the “sandwich” technique. (Monica Edwards, artist)

Type I repairs necessitate removal of the prosthesis and internal repair that can incorporate a patch of residual posterior leaflet; a flap of atrial appendage, Teflon, or pericardium; atrialization of the rupture; or autotransplantation. A pocket patch of pericardium sutured in place from the ventricle to the atriotomy has also been described. Having been left open at the top, the space between the ventricular wall and the patch is filled with BioGlue® Surgical Adhesive-impregnated Teflon (CryoLife Inc.; Kennesaw, Ga). The prosthesis is then reimplanted, with the top of the pocket patch incorporated into the atriotomy closure. External repair can be used in type II and type III repairs.<sup>8,9</sup>

Our external repair involved the use of deep pledgeted horizontal mattress sutures that passed through—and held in place—pieces of Teflon placed within the defect. Additional figure-of-8 sutures were passed more superficially through the plug, to prevent its migration into the LV cavity. The Teflon served as a space-filling buttress that reduced the distance needed to approximate the edges of the rupture; this in turn reduced the tension on the pledgeted sutures needed to achieve hemostasis. This simple technique helped to avoid further collateral tearing of the adjacent myocardium. We think that reduction of the tension on the securing sutures was the key element in our successful repair of the rupture.

The cause of the rupture in our patient is not clear. We used a low-profile 27-mm mechanical valve, smaller than the range of sizes typically associated with type I ruptures.<sup>6</sup> It is unusual for the implantation of a small mechanical prosthesis (as opposed to a stented prosthesis) to result in a type III ventricular rupture. Our resec-

tion of the posterior leaflet was minimal and from its leading edge, not near the annulus. Our débridement of calcium from the posterior leaflet and annulus was superficial, to avoid atrioventricular disruption and to seat the valve securely without the risk of a paravalvular leak. Another possible mechanism was a papillary muscle tear caused by tension on the short, thickened chordae as the posterior annular sutures were tied. Because the rupture was closer to the base of the ventricle than to the apex, this cause was unlikely. Also possible was a rupture caused by deep subannular suture placement, as mentioned by Deniz and associates,<sup>6</sup> that caught the ventricular endocardium and tore through ventricular muscle as it was tied, presenting as a type III rupture high in the LV posterior wall just below the coronary sinus. If indeed this was the causative mechanism, it might have been avoided by placing pledged annular sutures from the atrial side to secure the valve in position. Although we cannot identify with certainty the cause of the rupture in our patient, it is important to realize that ventricular rupture can occur during any MVR from causes not recognized or precisely defined at the time of surgery.

## References

1. Roberts WC, Morrow AG. Causes of early postoperative death following cardiac valve replacement. Clinico-pathologic correlations in 64 patients studied at necropsy. *J Thorac Cardiovasc Surg* 1967;54(3):422-37.
2. Treasure RL, Rainer WG, Strevey TE, Sadler TR. Intraoperative left ventricular rupture associated with mitral valve replacement. *Chest* 1974;66(5):511-4.
3. Miller DW Jr, Johnson DD, Ivey TD. Does preservation of the posterior chordae tendineae enhance survival during mitral valve replacement? *Ann Thorac Surg* 1979;28(1):22-7.
4. Miki S, Kusuhara K, Ueda Y, Komeda M, Ohkita Y, Tahata T. Mitral valve replacement with preservation of chordae tendineae and papillary muscles. *Ann Thorac Surg* 1988;45(1):28-34.
5. Zhang HJ, Ma WG, Xu JP, Hu SS, Zhu XD. Left ventricular rupture after mitral valve replacement: a report of 13 cases. *Asian Cardiovasc Thorac Ann* 2006;14(1):26-9.
6. Deniz H, Sokullu O, Sanioglu S, Sargin M, Ozay B, Ayoglu U, et al. Risk factors for posterior ventricular rupture after mitral valve replacement: results of 2560 patients. *Eur J Cardiothoracic Surg* 2008;34(4):780-4.
7. Karlson KJ, Ashraf MM, Berger RL. Rupture of left ventricle following mitral valve replacement. *Ann Thorac Surg* 1988;46(5):590-7.
8. Sersar SI, Jamjoom AA. Left ventricular rupture post mitral valve replacement. *Clin Med Cardiol* 2009;3:101-13.
9. Izzat MB, Smith GH. Rupture of left ventricle after mitral valve repair: case report and new technique of repair. *Br Heart J* 1993;69(4):366-7.